



# Case presentation

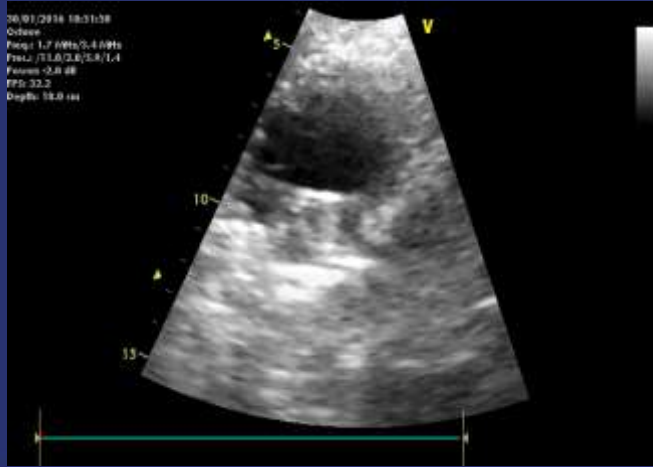
*Mahmoud Fawzy MD*

Suez Canal University

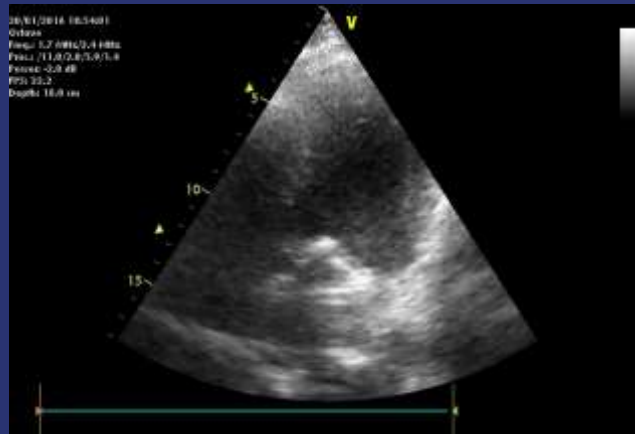Male patient 40 years old RHD with MVR 4 years ago presented for routine follow up echo.



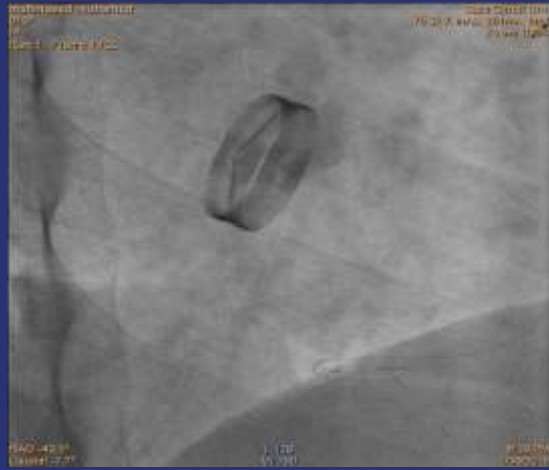# Tans-thoracic Echo



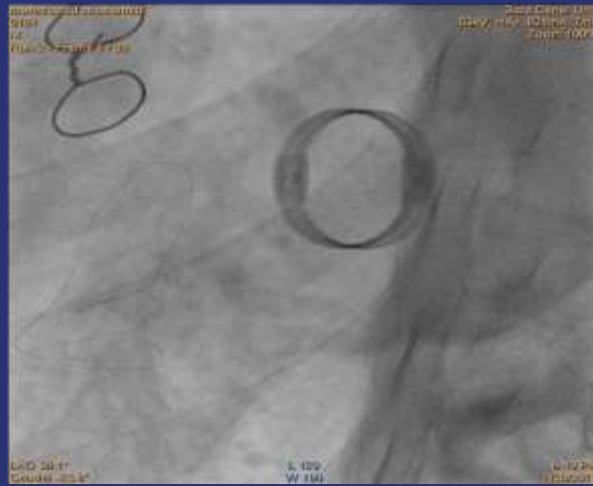# Tans-thoracic Echo



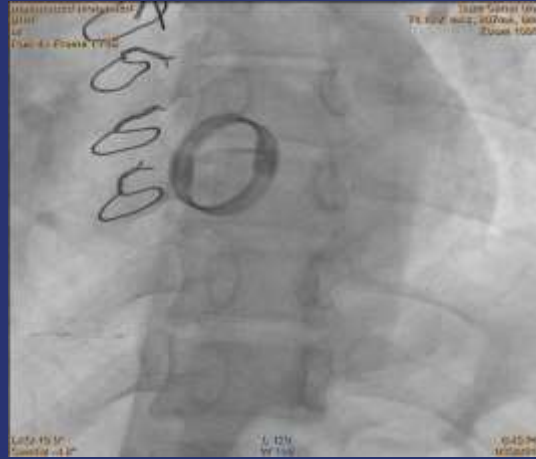# Fluoroscopy



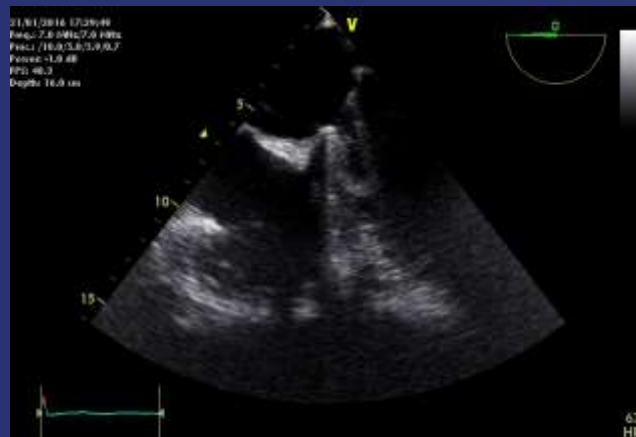# Fluoroscopy



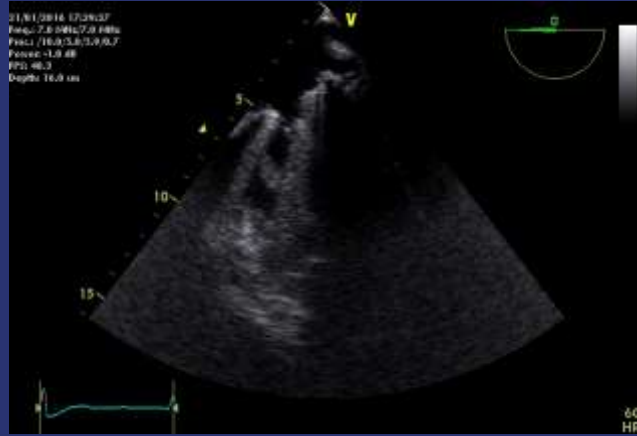# Fluoroscopy



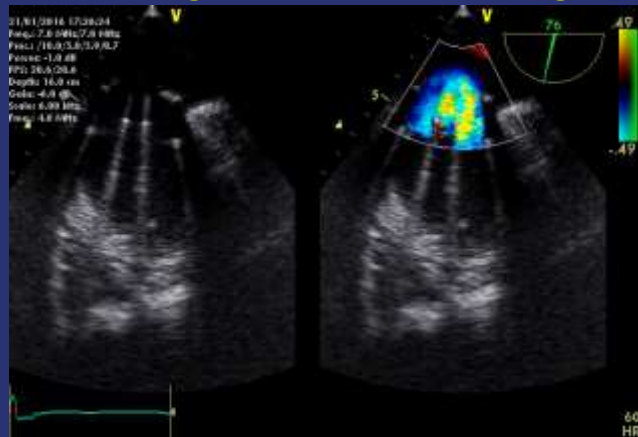# Transesophageal echocardiography



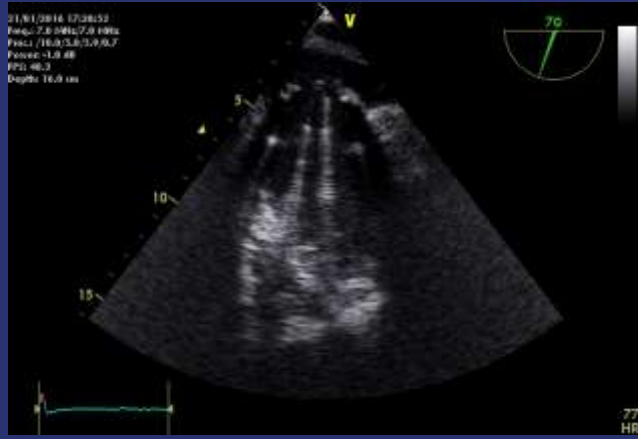
# Transesophageal echocardiography



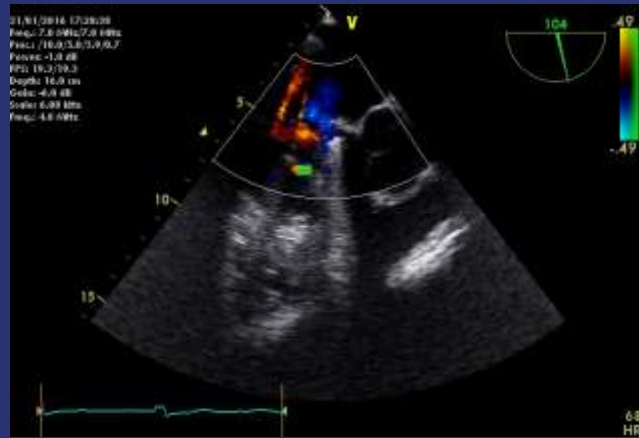
# Transesophageal echocardiography



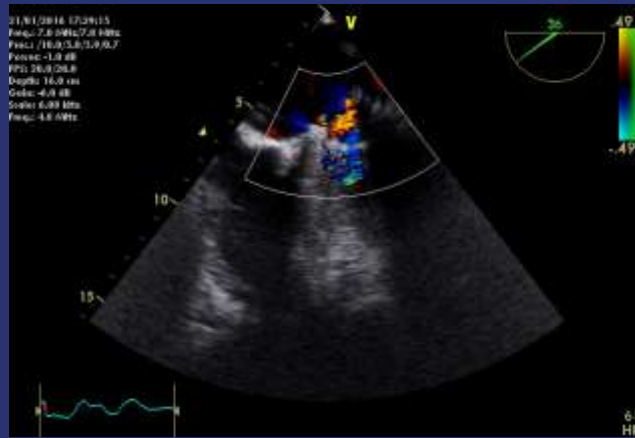
# Transesophageal echocardiography



# Transesophageal echocardiography



## Transesophageal echocardiography



## Conclusion

- Bileaflet mechanical valve was seen in the MV position with abnormal movement of the posterior and lateral aspect of the sewing ring of the valve most probably due to surgical sutures attached to the posterior MV leaflet not the annulus.
- No evidence of paravalvular leak or vegetations.



# Take home message

- TEE is mandatory if proper insertion of MV prosthesis within the annulus is not confirmed by surgeon.
- Early post operative TTE Echo is mandatory as baseline study for patient follow up.



# Thank you

