



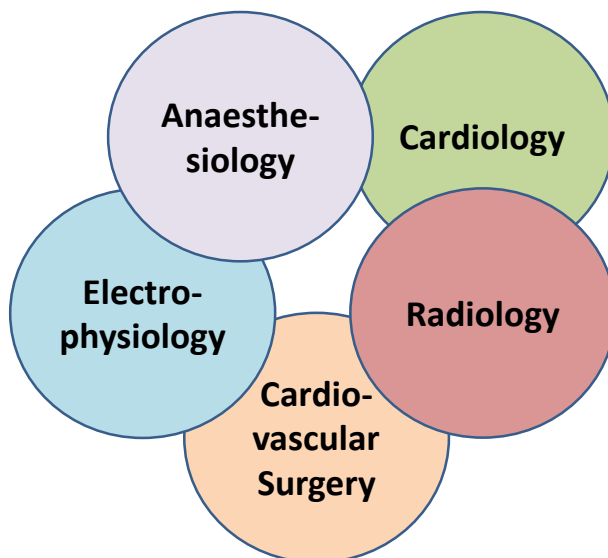
UNIVERSITÄT LEIPZIG
HERZZENTRUM



TAVI Establishing a Program

Gerhard Schuler
University of Leipzig – Heart Center

Establishing a TAVI Program : BASICS

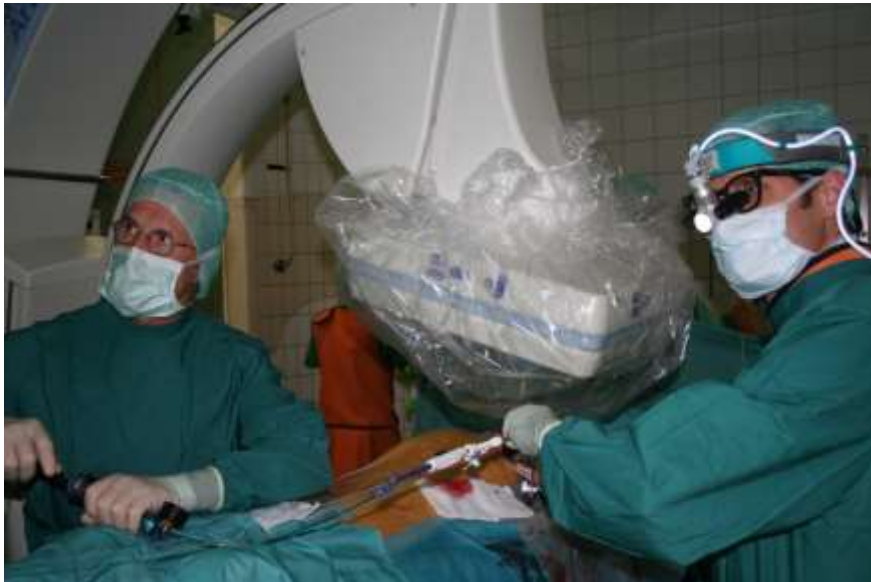

Establishing a TAVI Program : BASICS

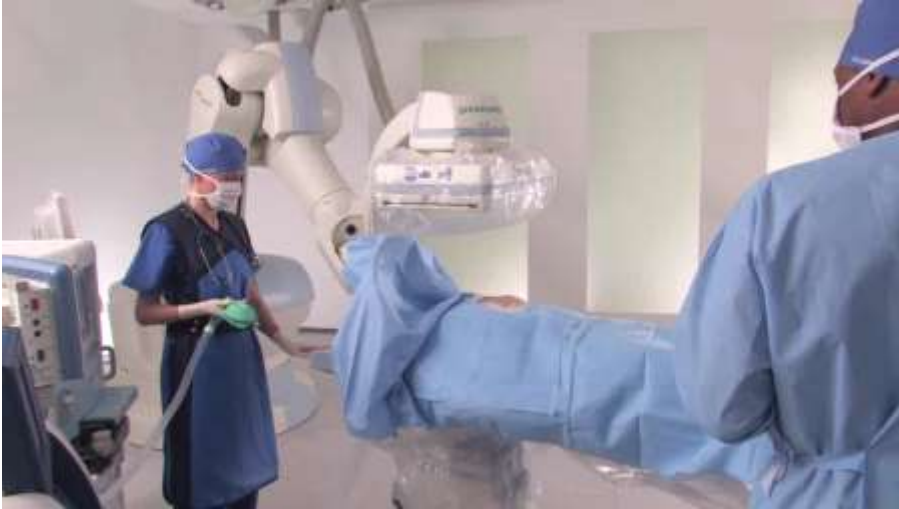Heart Team



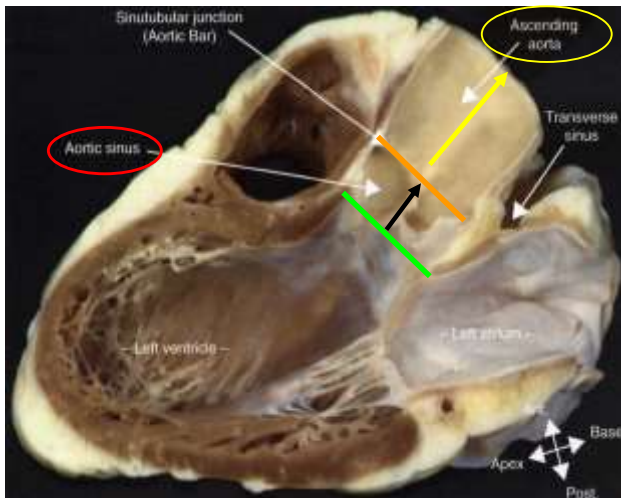
Indication for TAVR
Risk of the procedure
Which device?
Alternative treatment options



Establishing a TAVI Program : Hybrid OR



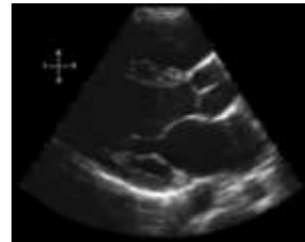Aortic Root: Definition



Sinutubular junction



Basal attachment of AV leaflets

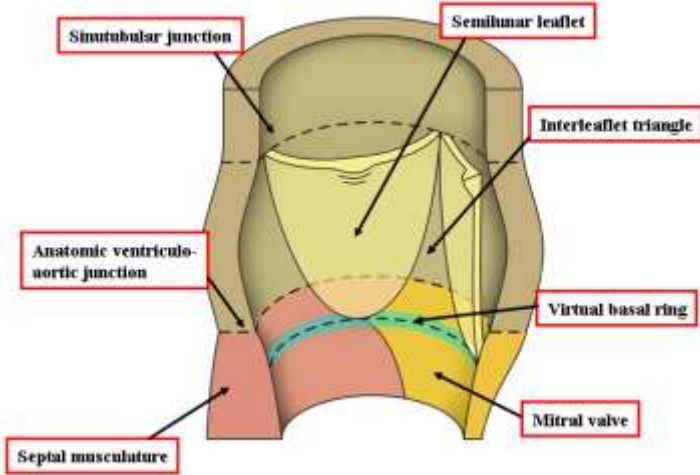


Photographs courtesy of Nicolo Piazza, MD

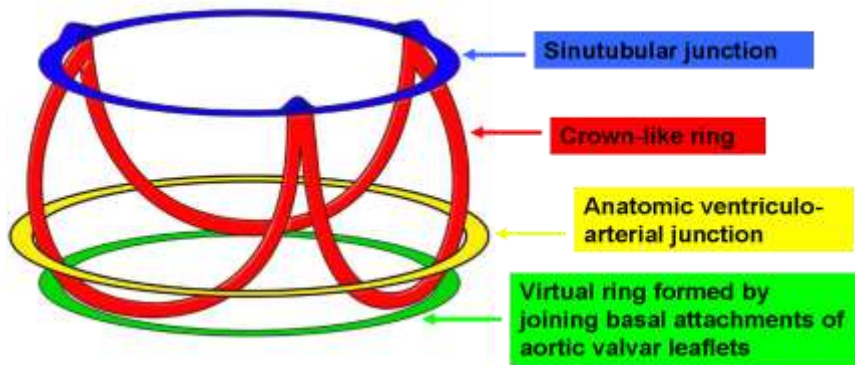
CONFIDENTIAL



Aortic Root

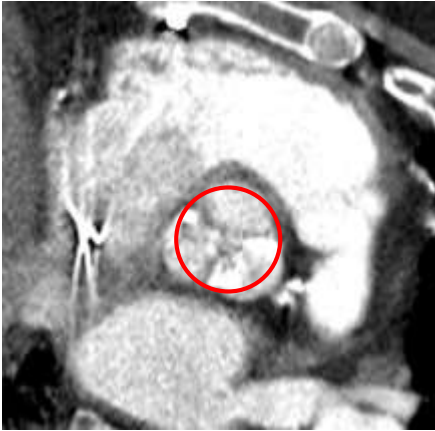

Rings of the Aortic Root



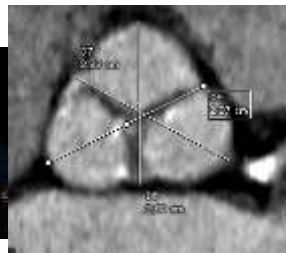
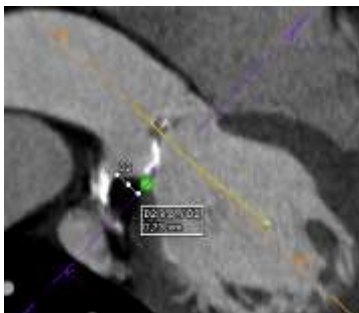
Anatomical Preconditions (Annulus/Aorta)

Methods of Measurement- CT

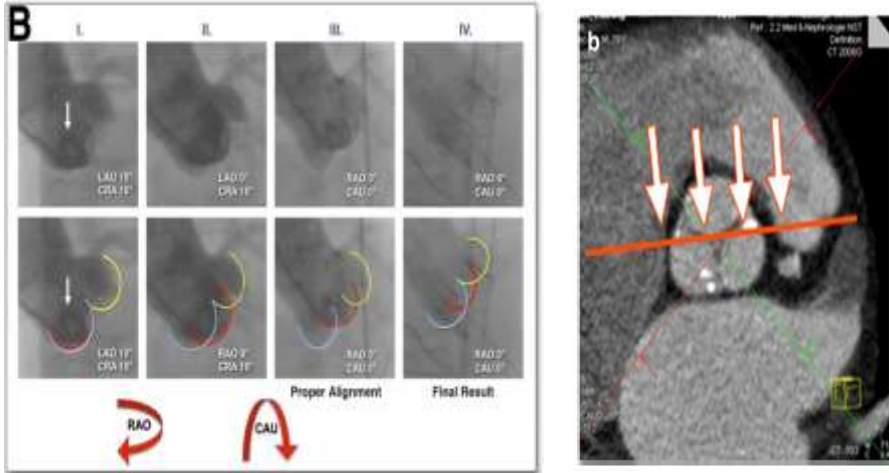


- Annulus:
 - not always round
 - oval shape
 - triangular shape

Annular Size Distance LCA / Annulus Assessment by CT



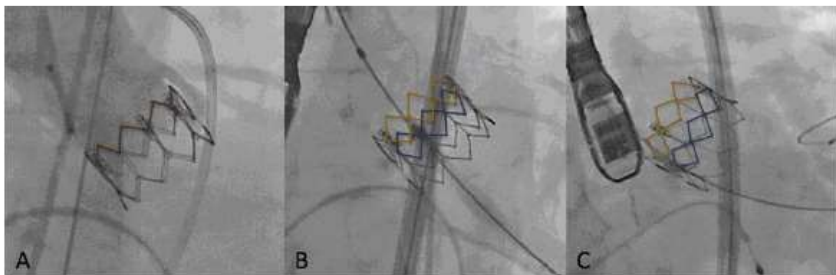
Angulation and Size



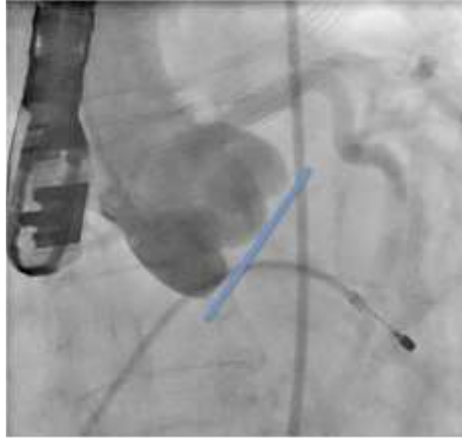Kasel et al (2013) JACC Cardiovasc Imaging. Feb;6(2):274-5

Prediction of Optimal Angiographic Deployment Projections

Journal of Cardiovasc Interv 2010; 3:1157



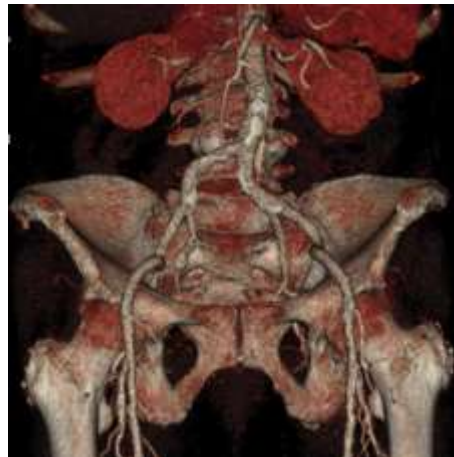Multislice CT Prediction of Optimal Angiographic Deployment



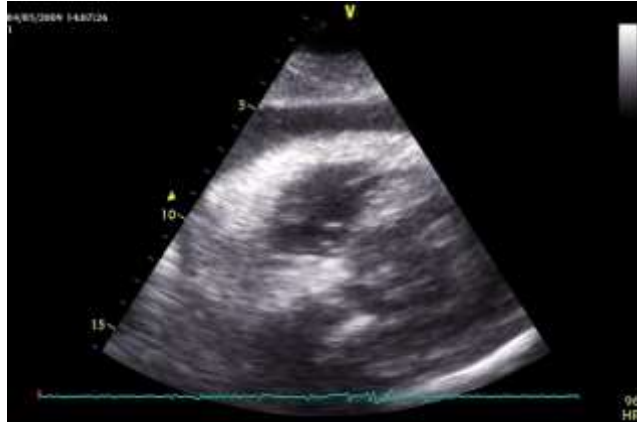Journal of Cardiovasc Interv 2010; 3:1157

Interventional Angiology

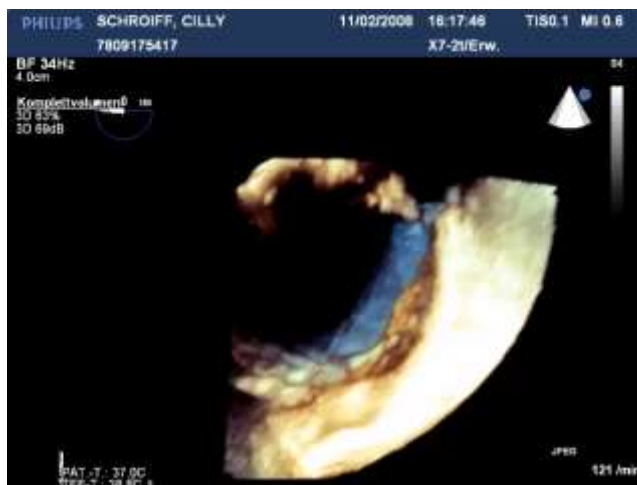Pelvic and Femoral Vessels
Size
Calcification
Kinking
Abnormalities



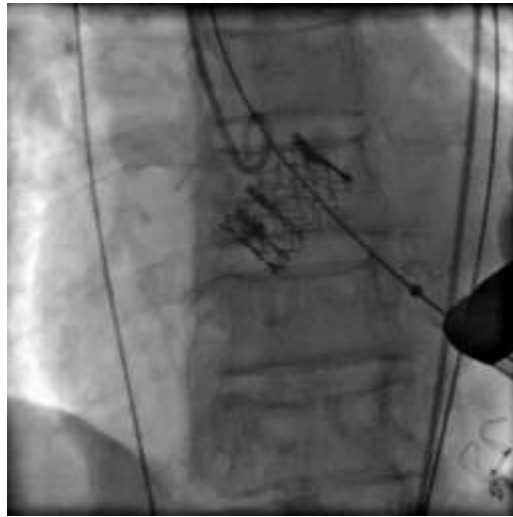
Pericardial Tamponade Following Wire Perforation



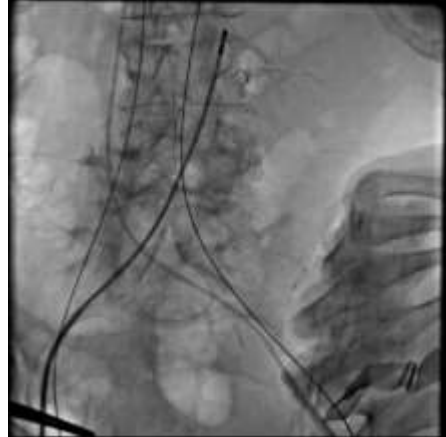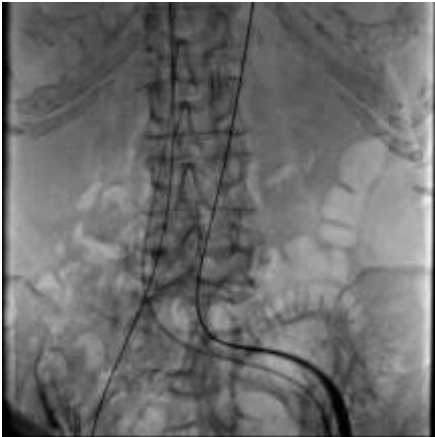Type A Dissection



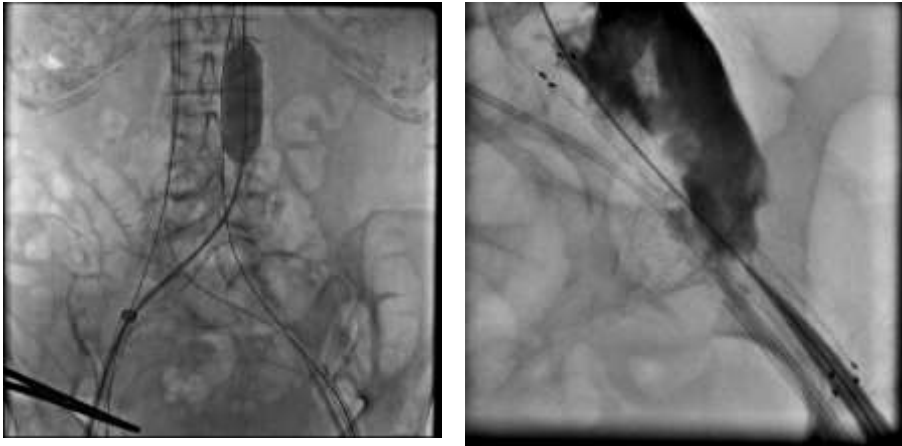
Annular Rupture



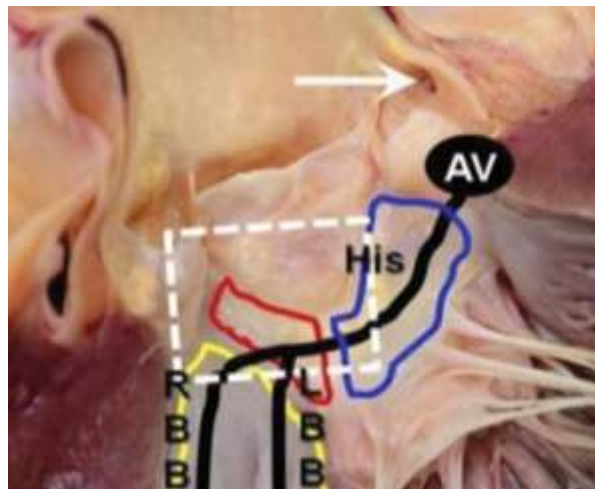
Vascular Complications



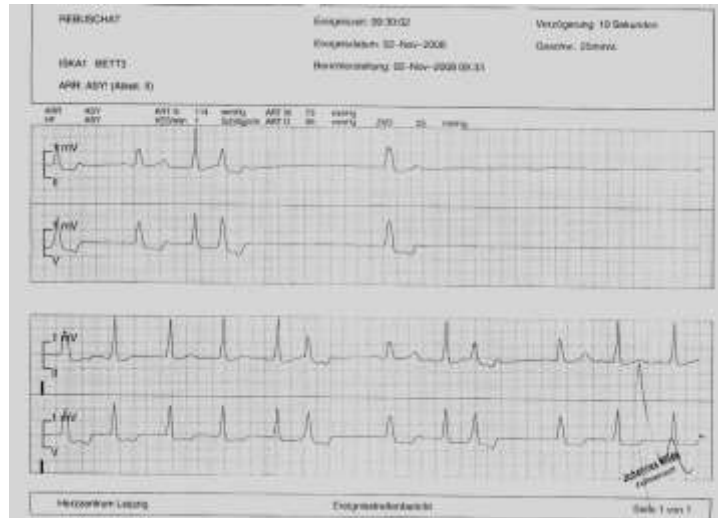
Vascular Complications



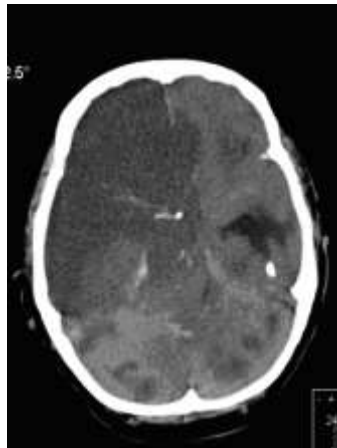Electrophysiology:



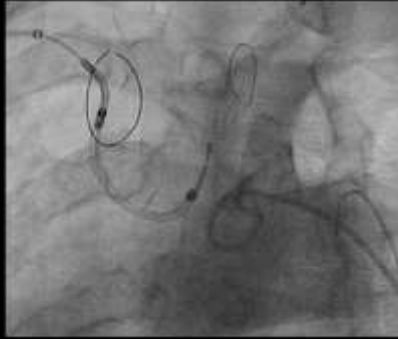
Electrophysiology: AV Block III° 4 Days Following COREVALVE



Establishing a TAVI Program: BASICS



Stroke - Claret™ Filter



MORTALITY Heart Center Leipzig

