

BIFURCATING CTO LESION

By
Dr. Hussam Bishr

P. History

2

- 49 years old, male patient
- Hypertensive
- Not diabetic
- Not smoker
- With P.H of IHD since 2009 with PCI to RCA & LAD

Present History

3

- 6 months ago Presented with exertional chest pain
- Resting ECG : non specific T-wave changes
- Stress ECG test : Positive (ST segment elevation in III & AVF)
- Echo : Normal LV dimensions, EF=71% with RSWMA
(basal inferior hypokinesia)

Labs

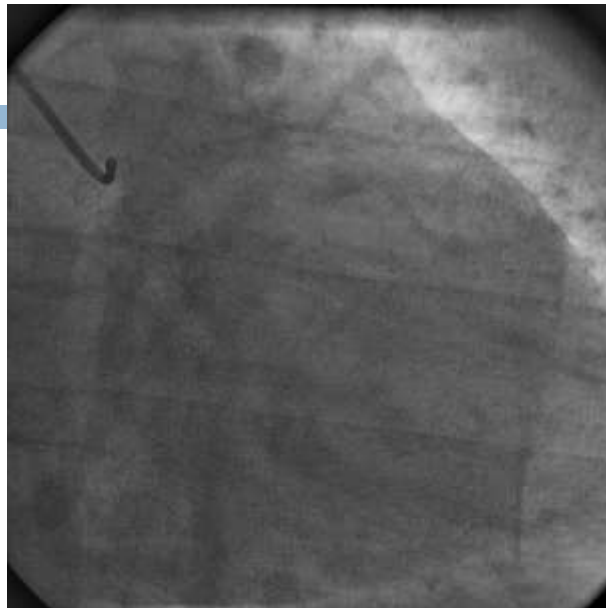
4

- S.Creat. : 1.2 mg/dl
- Urea : 16 mg/dl
- Hb: 18.4 g/dl
- PLT: 238 thousand/cmm

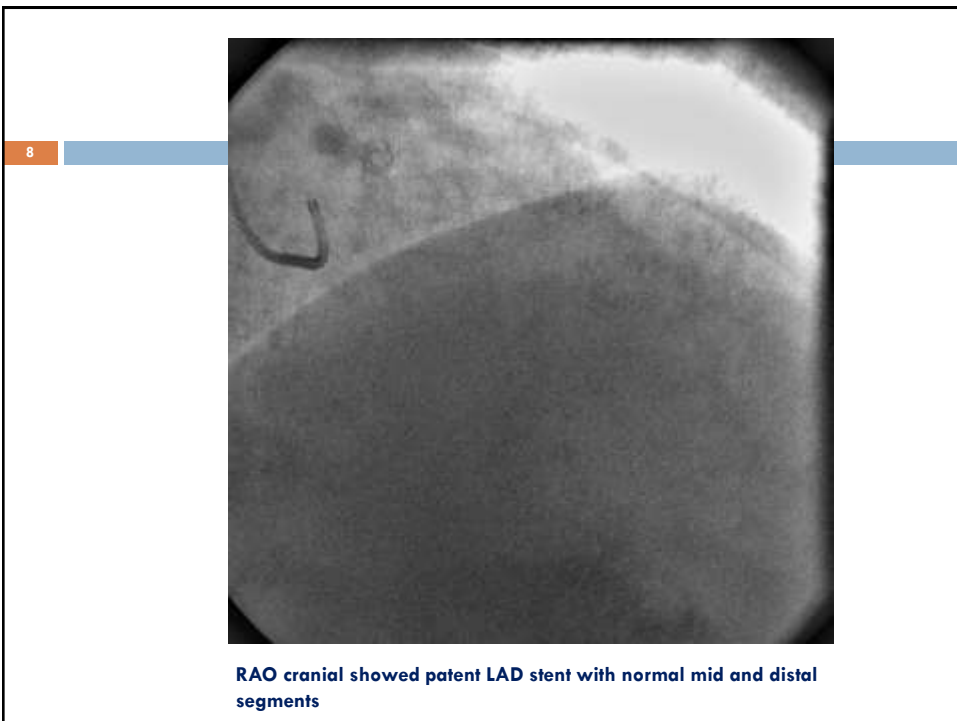
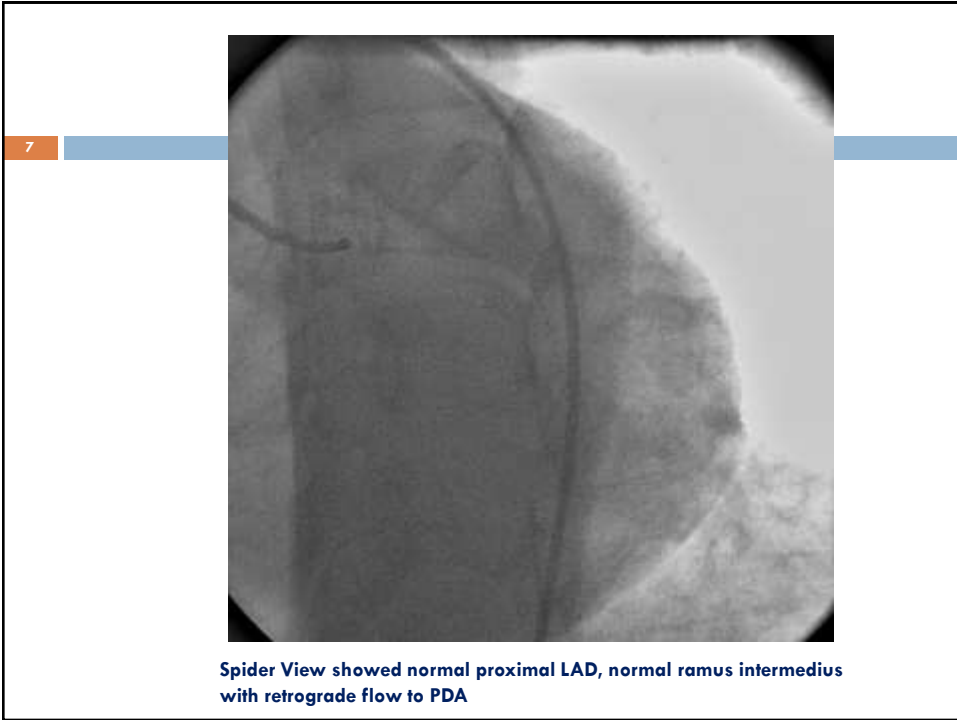
5

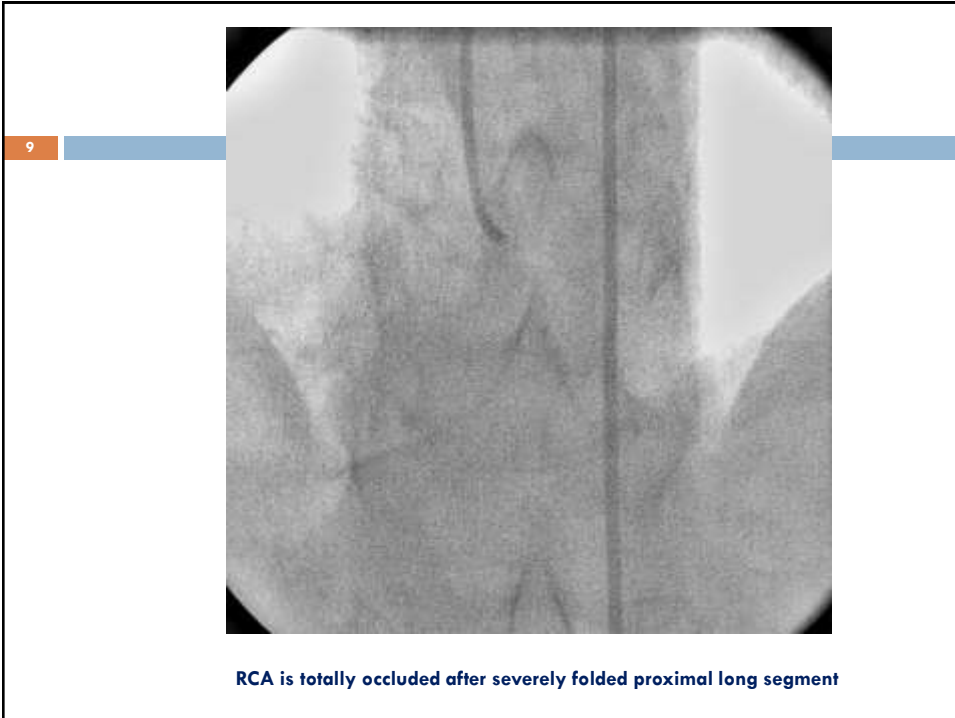
CA was done and revealed

6



RAO caudal showed normal bifurcating LM, LCX is totally occluded after long diseased stump





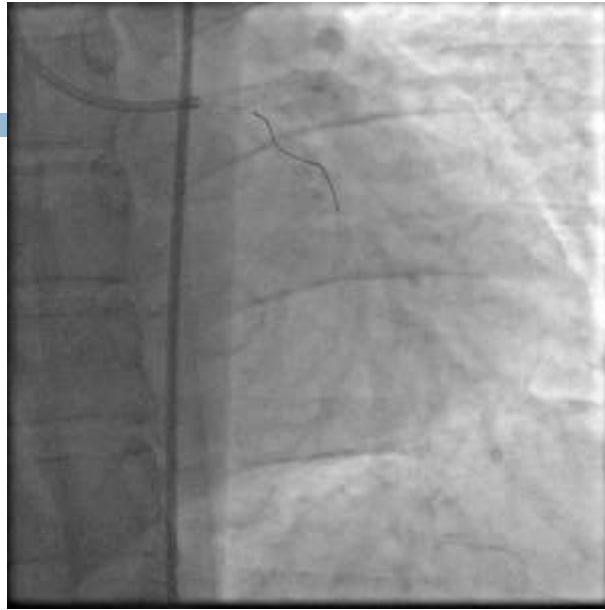10

So what is the

PLAN ?????

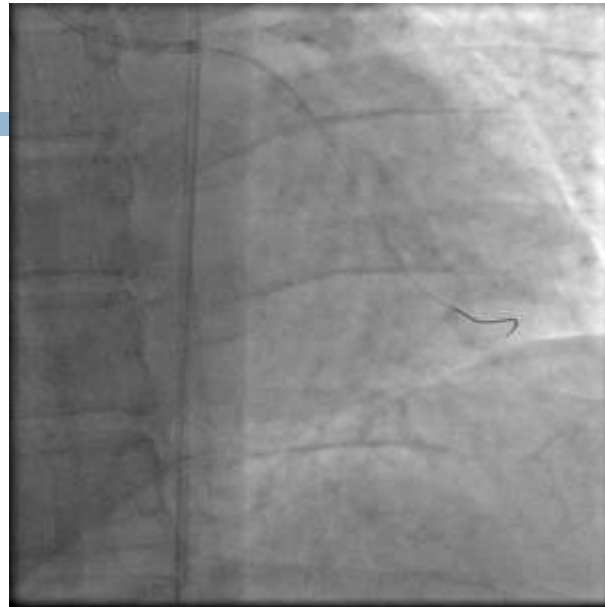This slide contains the text 'So what is the' followed by 'PLAN ?????' in a bold font. It is framed by a black border with a blue horizontal bar across the top and a small orange square containing the number '10' on the left side.

11



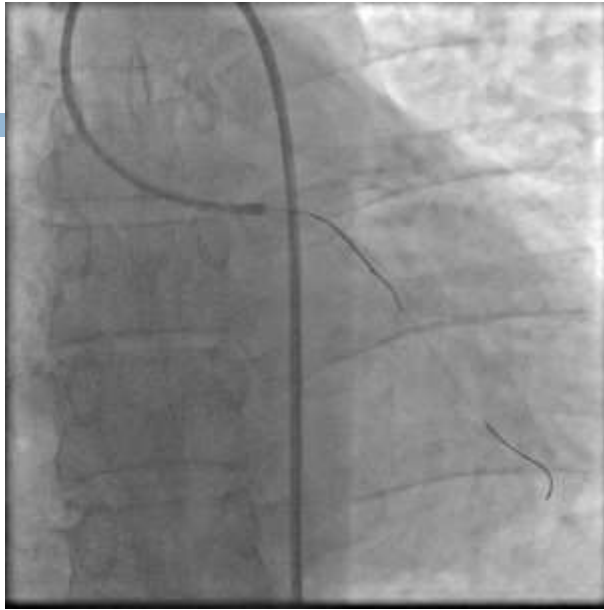LM was engaged by XB4 6F GC, Fielder XT wire was used to pass the OM lesion

12



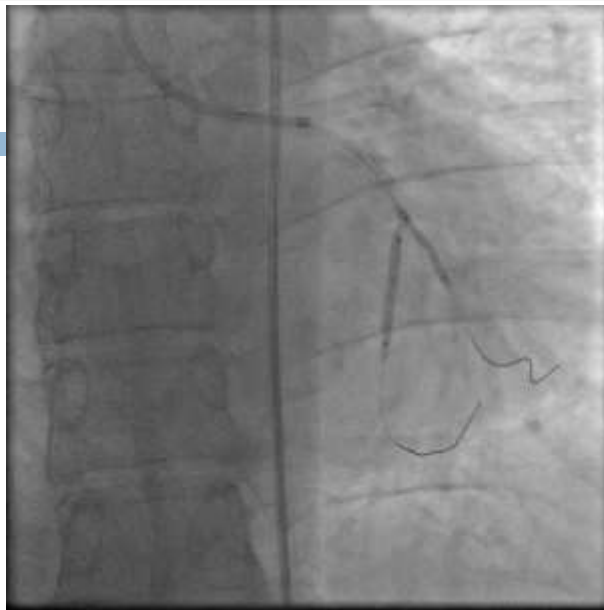Fielder XT wire passed successfully through the OM lesion with aid of fine cross MC

13



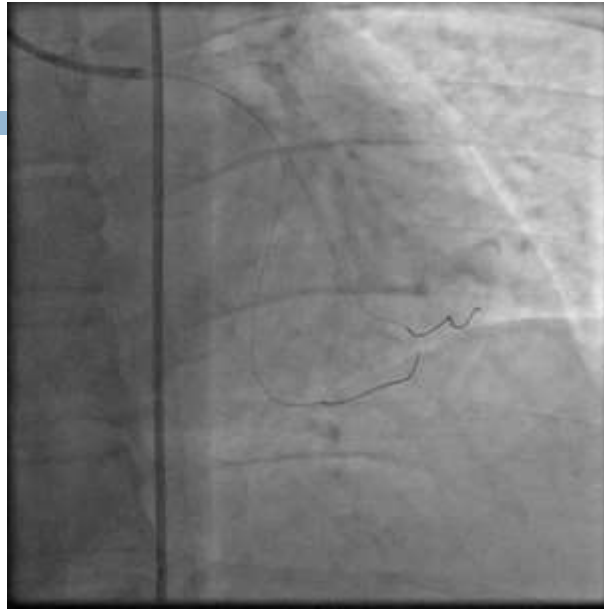Another Fielder XT wire was used to pass the proper LCX lesion

14



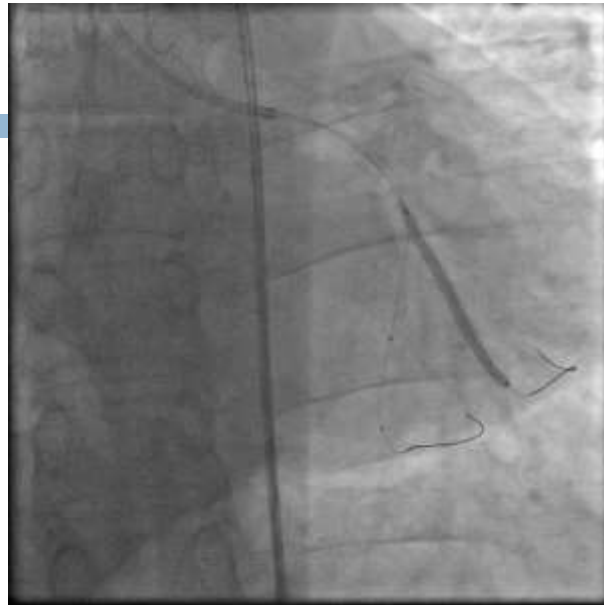PTCA to LCX and OM lesion by Ryujin balloons (2x15mm)

15



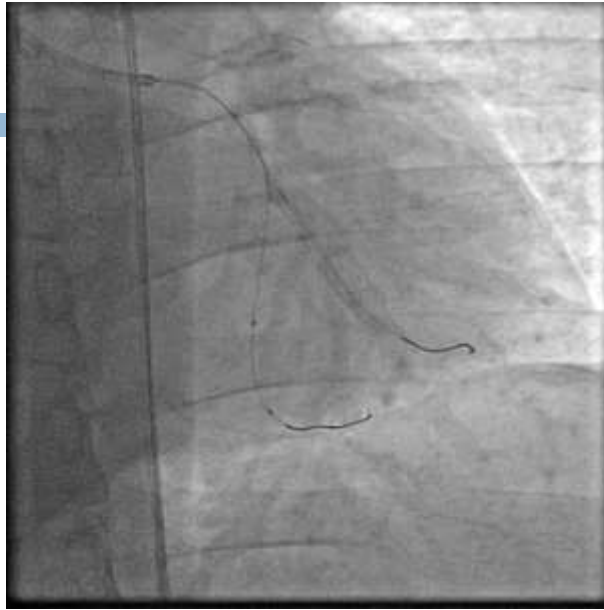Control Angiography after dilatation

16



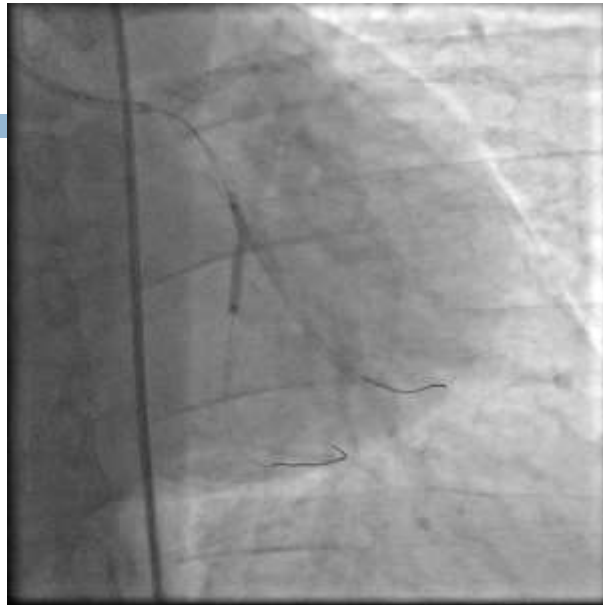Fixation of OM lesion by Ultimaster (2.25x38mm)

17



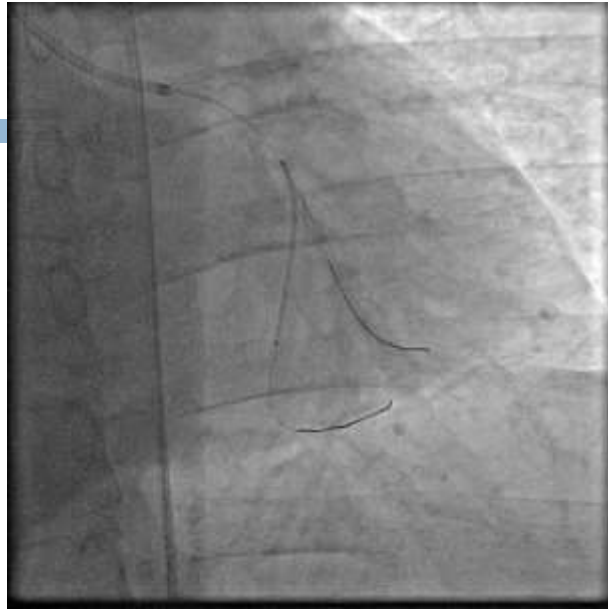Control Angiography

18



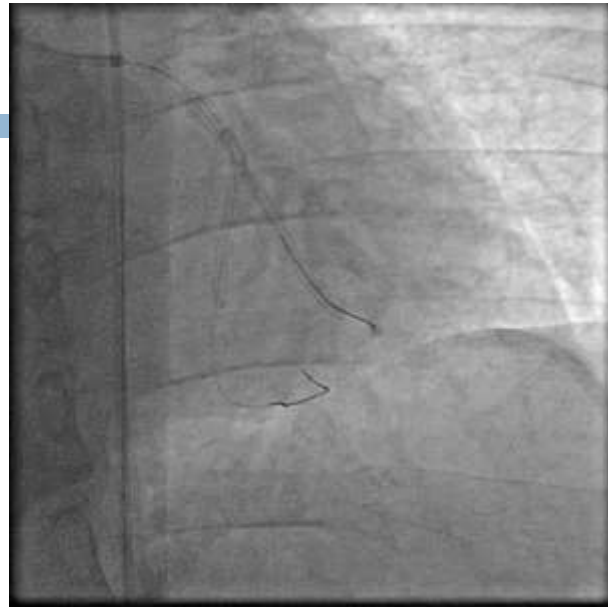Crushing the proximal end of the OM stent

19



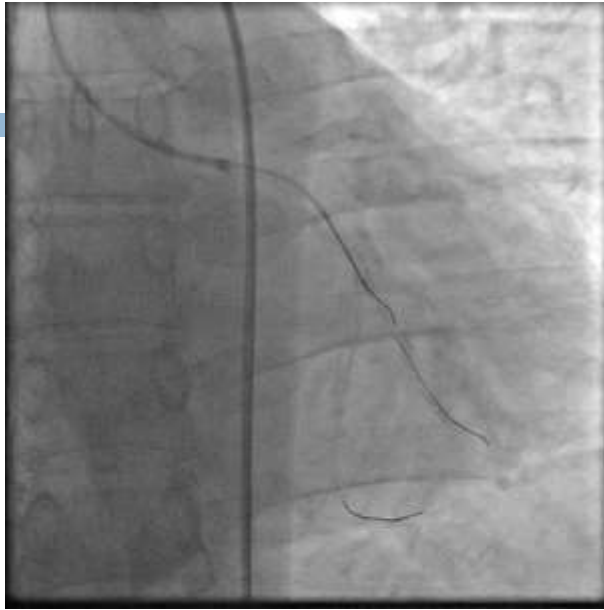Fixation of LCX lesion by Ultimaster 2.5x33mm

20



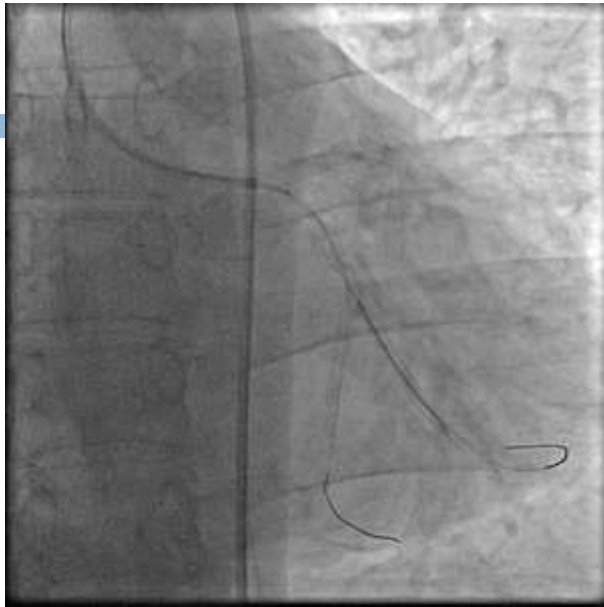
Control Angiography

21



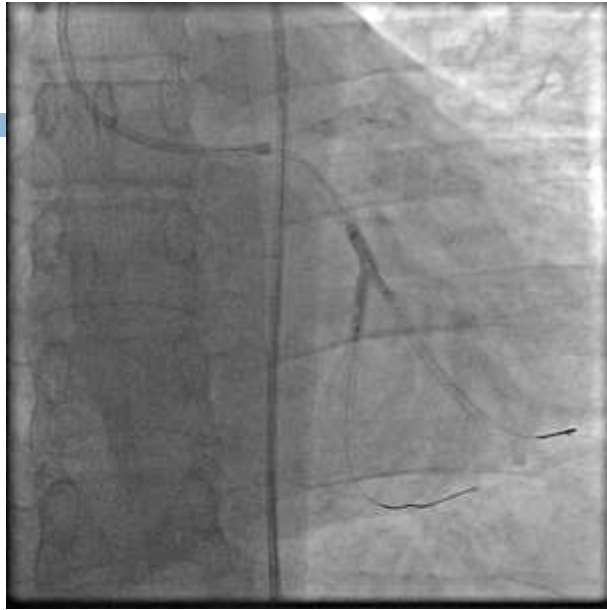
Re-crossing to the OM by run-through intermediate wire

22



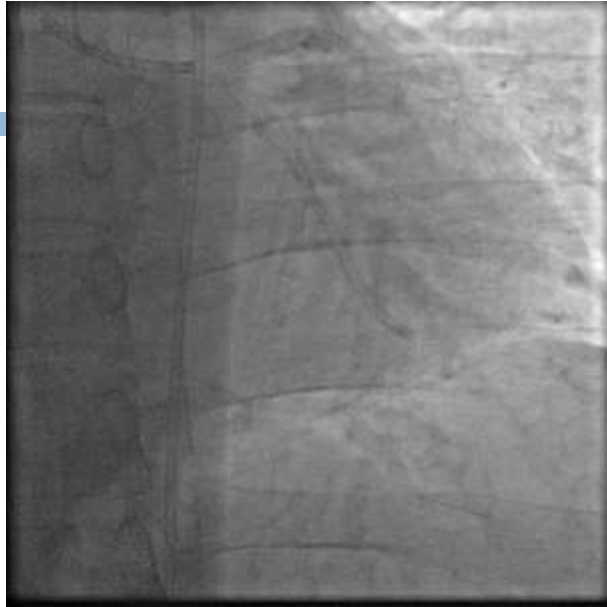
Withdrawal of the jailed wire in the OM

23



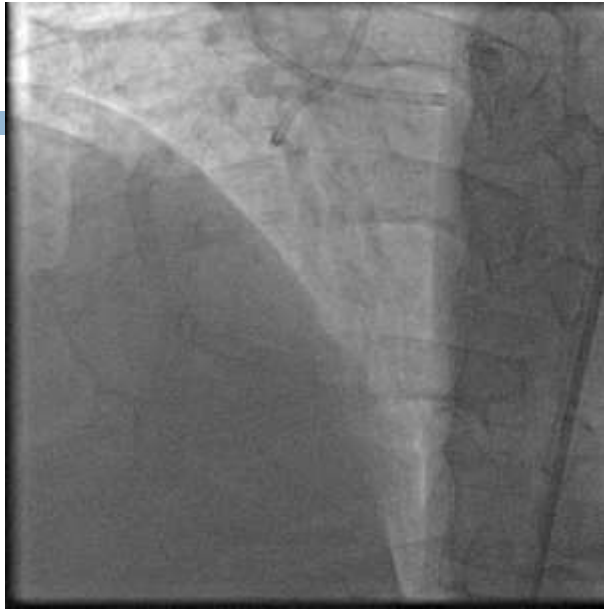KBT was done by 2 high pressure balloons .

24



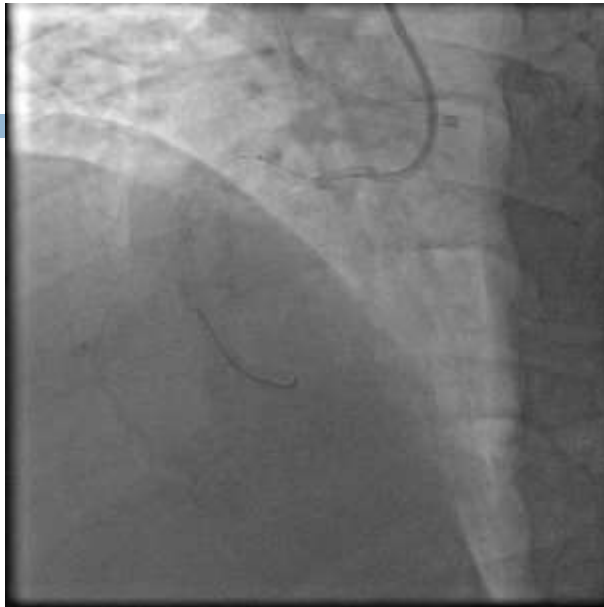Final Result of the left system

25



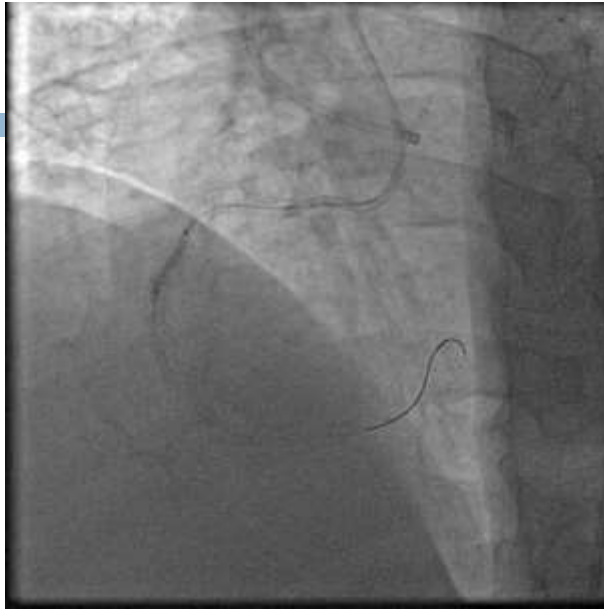
RCA was engaged by AL1

26



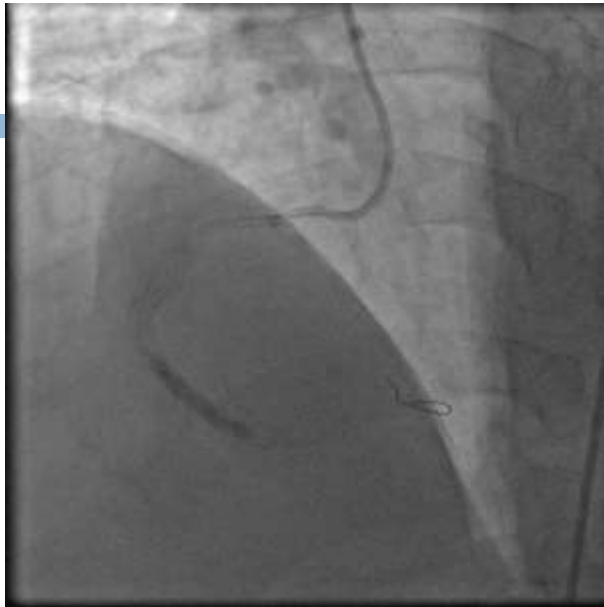
Runthrough hypercoat wire succeeded to pass the RCA lesion with the aid of fine cross MC

27



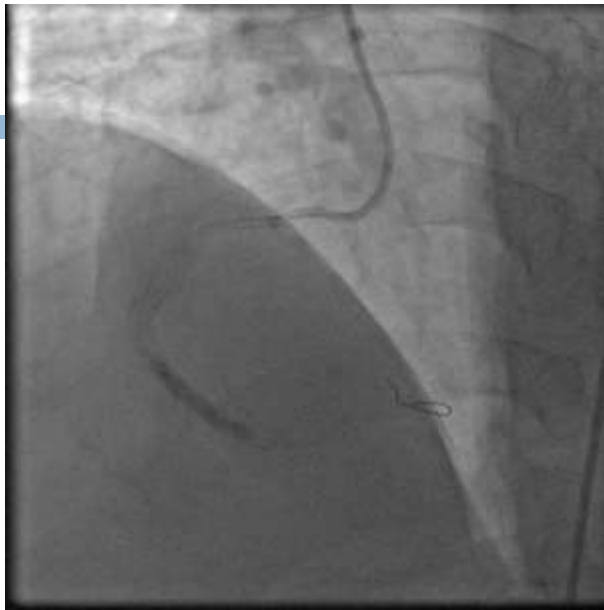Multiple PTCA to RCA ISR

28



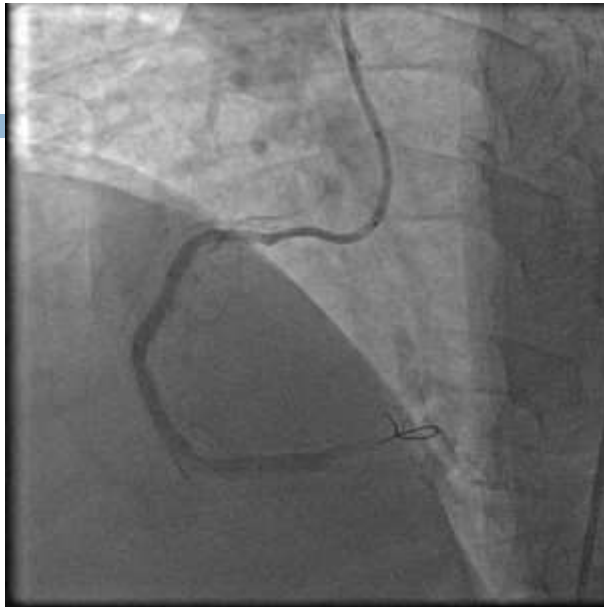PTCA to RCA ISR with larger balloon

29



PTCA with Drug Eluting Balloons

30



Final Result of the right system

