

PDA Stenting Alexandria Experience

By
Dr Hani Mahmoud Adel
University of Alexandria

2/27/2017

CE 2017 Cairo

1

Indications

- **Duct dependent pulmonary circulation**
 - PA IVS/Critical PS
 - PA TA/ SV variants with PA
 - PA VSD / F4 with very severe RVOTO
- **Duct dependent systemic circulation**
 - HLHS variants
- **TGA IVS**

2/27/2017

CE 2017 Cairo

2

PDA stenting started in early 90's

- Gibbs JL, et al in 1992 proposed such technique BHJ.
- Schneider M , et al reported his experience in 1992 in EHJ
- Alwi M, et al reported his experience in 2004 probably the largest series of cases.
- Gewillig M, et al also reported his experience in 2004 in JACC.
- Detmer Schranz reported his technique of axillary access in PDA stenting in CCI 2011.

Principle in duct dependent Pulmonary circulation

- To create a source of blood flow to the lungs as an alternative to Modified blalock - Taussing shunt .
- It gives time to the hypertrophied non-compliant RV to remodel, grow and be capable to provide adequate forward blood supply to the lungs on its own in PA IVS & some critical PS cases.
- It gets thrombosed shortly after stopping the aspirin and rarely needs to be occluded interventionaly.

Principle in TGA IVS

- Wide stent at least 4 mm diameter.
- Elevates PAP by increase flow & increase resistance .
- Expose LV to higher systolic & ED pressures.
- Delays the involution of LV & allows training of LV.
- An alternative to PA band & BT shunt for LV training for late ASO.

Types of Interventions

- RFP (Hard end of coronary wire perforation or stiff end of 0.035'' wire perforation) PV & B PV ± PDA stenting **PA IVS**
- Balloon dilatation PV ± PDA stenting **Critical PS**
- PDA stenting alone **PA VSD & F4 with severe RVOTO & in TA & PA & unbalanced CAVSD with PA**
- PDA re –stenting or redilatation (Antegrade or Retrograde)
- Hybrid intervention for PDA stenting **HLHS variants**

Population data

- No=35 cases attempted between April 2010 & October 2016
- Age in days 12 (3 -120)
- Wt in kgs 3.1 (1.8-5.5)

- **Diagnosies:**

PA VSD **8**

PA TA **9** (one was SI with dextrocardia & Rt aortic arch)

Unbalanced CAVSD PA **2** one was dextrocardia

F4 with severe RVOTO **3**

PA IVS **7** cases

Critical PS **2**

TGA **4** cases

Shape of PDA

Conical shape slopping upward PDA

14 cases mostly TA PA & PA IVS & TGA IVS

Conical shape coma shaped PDA

5 cases mostly TA PA

Vertical PDA

8 cases mostly F4 & PA VSD

Tortous S-shaped PDA with one bend

2 cases

Tortous S-shaped PDA with 2 bends

6 cases all of them failed 2 tried axillary access , no carotid cut down was attempted

Procedure data

- 29 successful stenting, 6 cases failed stenting.
- Procedure time in mins 123 (90-240)
- No of stents per case were usually one for each case
7 patients needed 2 stents .
- Redilatation of stents 6 cases.
- **P.S 2 cases for HLHS (apart from the 35 cases) one had LCOP syndrome & one embolized to RPA.**

Procedure data (cont.)

- Venous route (FV) of stenting **10 cases**
- Arterial route of stenting (FA) **25 cases** (2 of them tried left axillary access)
- Antegrade **4 cases**
- Retrograde **31 cases**
- Associated interventions
 - BAS **8 cases** 4 TGA IVS & 4 PA IVS
 - PV Perforation & BPV **3 cases**
 - BPV **1 case**
- Stay in NICU in most cases was between 48-96 hrs apart from the complicated cases

Complications

- 2 cases with very tortuous PDA died one within 24 hours post procedure and the other on table both dt spasm of the PDA which became resistant for response to prostin f as a result of more than 2 hours manipulation of wires & catheters within the PDA.
- PDA stent was embolized in a case of PA VSD with vertical PDA to RPA and was nice in place & we put another one nicely and baby was ok.

- 6 cases died (4 of the successfully stented cases & 2 of the failed stenting cases)
 1. One died of L.C.O.S (3.5 mm x 20 mm in 1.8 kg 33 weeker).
 2. One died of L.CO.S in PA IVS 2.6 kg 8 days old baby with retrograde PV perforation and PDA stent with severe Pi & figure of 8 circulation .
 3. 2 died without stenting one on table & one 24 hrs later and were very tortous PDAs with 2 or more bends
 4. 2 died of limb ischemia.

- Loss of foot pulses were in 8 cases 6 were transient and 2 were permanent , one died from it as part of L.COP S and one needed amputation and died after amputation.
- One baby had IC Hge and needed long stay in NICU for 3 weeks to recover from such adverse reaction to heparin although we did not put baby on more dose of heparin than the usual protocol and that procedure was one of most rapid & smooth ones , discovered at 12 hrs post procedure with convulsions.

Equipements

- 4 fr Pigtail catheter for angiograms
- 4 fr cut off Pigtail catheter for advance of wire
- 0.014 "coronary extrasupport guidewire with floppy J-tip as BMW
- 4 fr (arterial or venous) or 6 fr (venous) long Mullins Cook sheath to stabilize stent placement when there is acute curve between arch & the PDA.
- 3-4 mm (inflated to 3.5 up to 4.3 mm) highly flexible low profile coronary premounted bare stents liberte' & Omega (Boston Scientific).
- Other wires might be needed terumo wire & 0.035" x 260 cm j-tipped exchange wire

Procedure imp steps

- Stop Prostin infusion between 6 to 12 hrs before procedure with SaO₂ pre-procedure 70-75% .
- Bolus heparin of 100 u/kg IV after access and frequent boluses every 1 hr to maintain ACT of more than 180 msec.
- Heparin infusion start on a rate of 10-15 u/kg/hour based on size of stent 3.5 mm or 4 or 4.5 mm diameter as soon as stent is inflated.
- Better ventilate baby for 12 hours esp if lengthy procedure.
- Keep baby on heparin till oral feeds and starting baby aspirin .
- IV Abcs.

Fate of stented cases

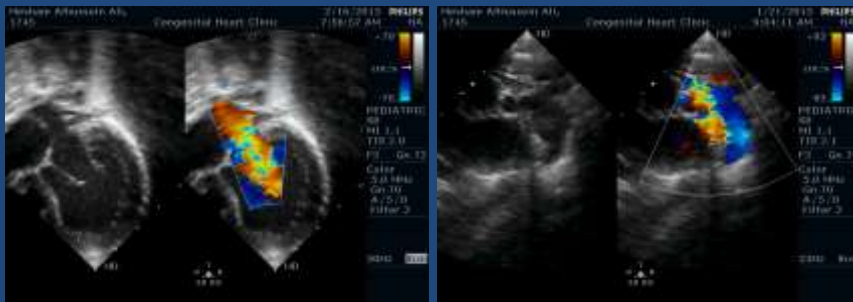- TGA IVS cases 2 were eligible for switch regarding LV mass & LVPWd at 3 months of age, whereas the other 2 cases LV involuted even with PDA stenting.
- PA cases need for redilation in 6 cases.
- Glenn shunt in 6 cases
- PA IVS needing surgical valvotomy 3 cases
- F4 that had full repair 3 cases.

2/27/2017

CE 2017 Cairo

17

PA TA

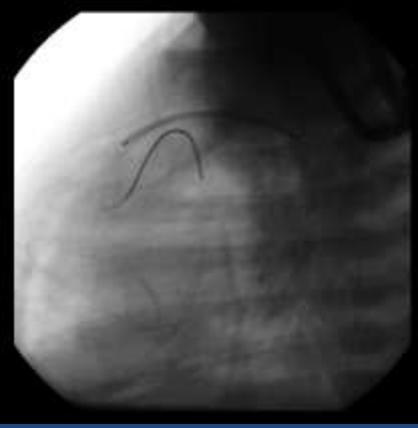
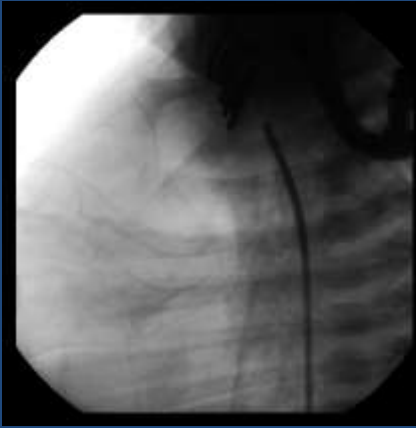
2/27/2017

CE 2017 Cairo

18

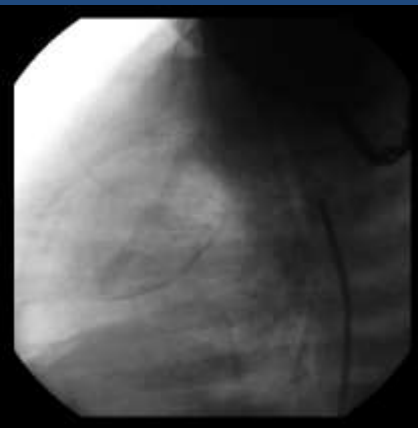
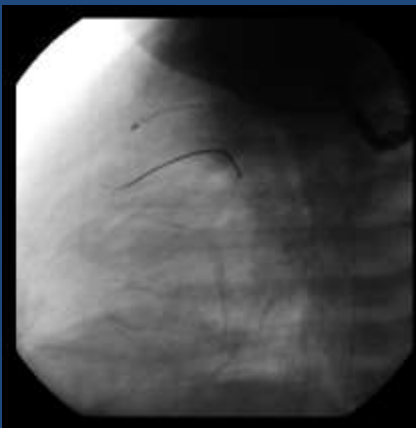
One bend coma shaped PDA



2/27/2017

CE 2017 Cairo

19

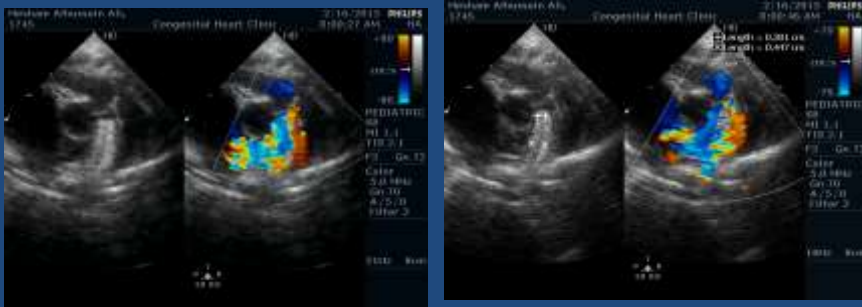


2/27/2017

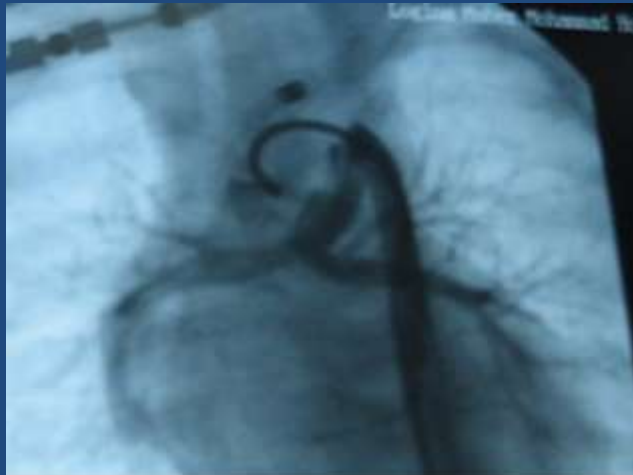CE 2017 Cairo

20

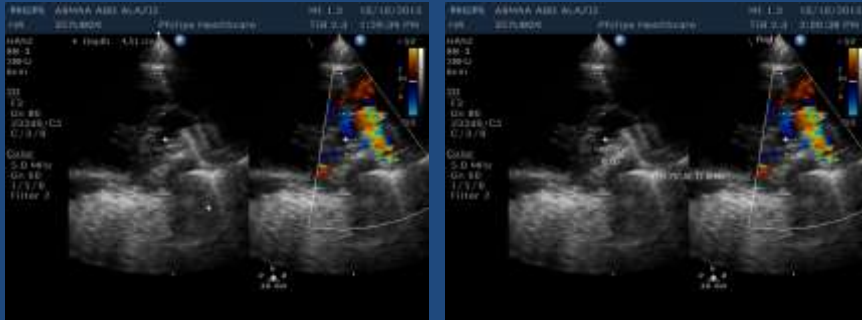
Post stenting Echo



PA VSD



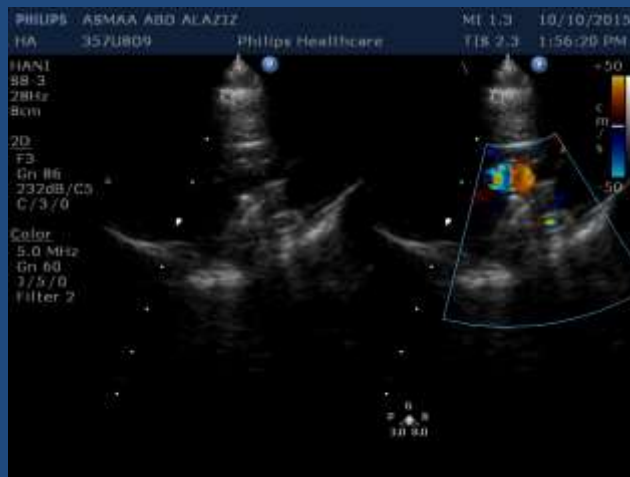Tortuous S-shaped PDA with one bend



2/27/2017

CE 2017 Cairo

23



2/27/2017

CE 2017 Cairo

24

Advantages

- Less incidence of pulmonary overcirculation.
- Less risk of branch PAs distortion compared with 3.5 mm shunts in small NBs.
- For babies with small branch PAs less than 3.5 mm difficult for BT shunting.
- No need of another intervention for occluding the BT shunt.
- Smoother post procedure course.
- Can be done in day 2 or 3 of life even if the baby is 2 kg or less.
- Less time on prostin & in NICU with all its complications and cost.
- Save the baby a thoracotomy and even median sternotomy in some cases.

2/27/2017

CE 2017 Cairo

25

Limitations

- Failed axillary access twice in cases with very tortuous PDA, **Sonosite** would have made a lot of difference.
- Difficulties in perforation PV in cases of PA IVS with no Bailys RFP system.
- No guarantee that PDA stenting would significantly delay LV involution in TGA IVS for more 2-3 kgs.

2/27/2017

CE 2017 Cairo

26

Take home messages

- Try to cover all the duct with least no. of stents .
- Never leave the duct ampulla uncovered to avoid restenting in another setting.
- Never go too far in covering it leading to acquired CoA.
- Never try to stent unless you are happy with the PDA morphology by proper angiograms in both PA & lateral projections with some angulations, as manipulations of a PDA with wires and catheters and failing to stent with no plan B for urgent BT shunt back up is a death verdict to the baby in lot of such cases.

2/27/2017

CE 2017 Cairo

27

- Try to postpone till weight is above 3 kg the risks become much less compared to below 3 kg.
- For complex very tortous PDAs with 2 bends do not try stenting unless attempting left axillary access.
- For TGA IVS PDA stenting take care of the duct is short with acute angle with isthmus (marked obtuse angle with Dao) and easy to cause acquired CoA if not very accurately deciding proper length of stent.

2/27/2017

CE 2017 Cairo

28

- For more than one stent and while telescoping stents try to cover well the pulmonary end by first stent and while overlapping the second stent for covering the aortic end it is important while putting the stent to be cautious in order not to further advance the 1st stent into PA and also while taking the deflated balloon from second stent not to pull the stent back far into Dao.

Thank You