



45<sup>TH</sup> Annual International Congress of the  
EGYPTIAN SOCIETY OF CARDIOLOGY  
**CardioEgypt 2018**

## Dealing with Difficult Anatomy

Samir B. Pancholy, MD, FAHA, FACC, FSCAI  
Professor of Medicine, Geisinger Commonwealth School of Medicine,  
Program Director, Cardiovascular Diseases,  
The Wright Center for GME  
The Commonwealth Medical College  
Scranton, PA

## Disclosures

- Consultant: Medtronic, Terumo
- Equity: Vasoinnovations Inc.



45<sup>TH</sup> Annual International Congress of the  
EGYPTIAN SOCIETY OF CARDIOLOGY  
**CardioEgypt 2018**

[www.cardioegypt.com](http://www.cardioegypt.com)

## Counterpuncture

- More frequently successful on first attempt



[www.cardioegypt.com](http://www.cardioegypt.com)

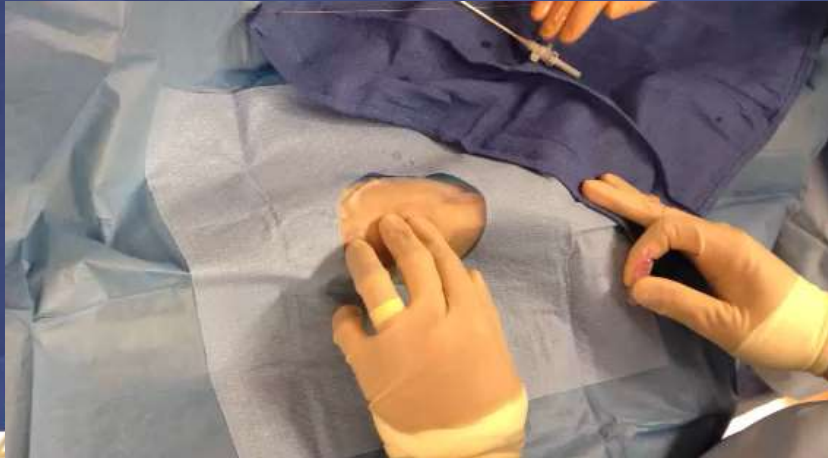## Counterpuncture

- More frequently successful on first attempt
- ????? Faint pulse



[www.cardioegypt.com](http://www.cardioegypt.com)

# Modified Counterpuncture technique



EGYPTIAN SOCIETY OF CARDIOLOGY  
**CardioEgypt 2018**

[www.cardioegypt.com](http://www.cardioegypt.com)

Failed  
Puncture

Loss of  
Radial Pulse

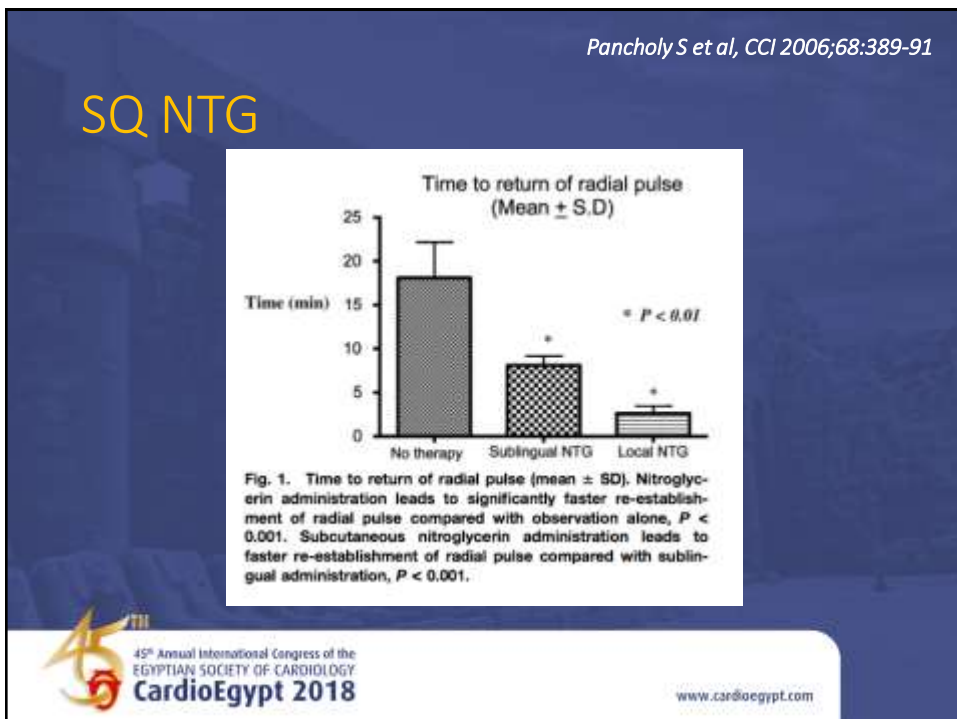
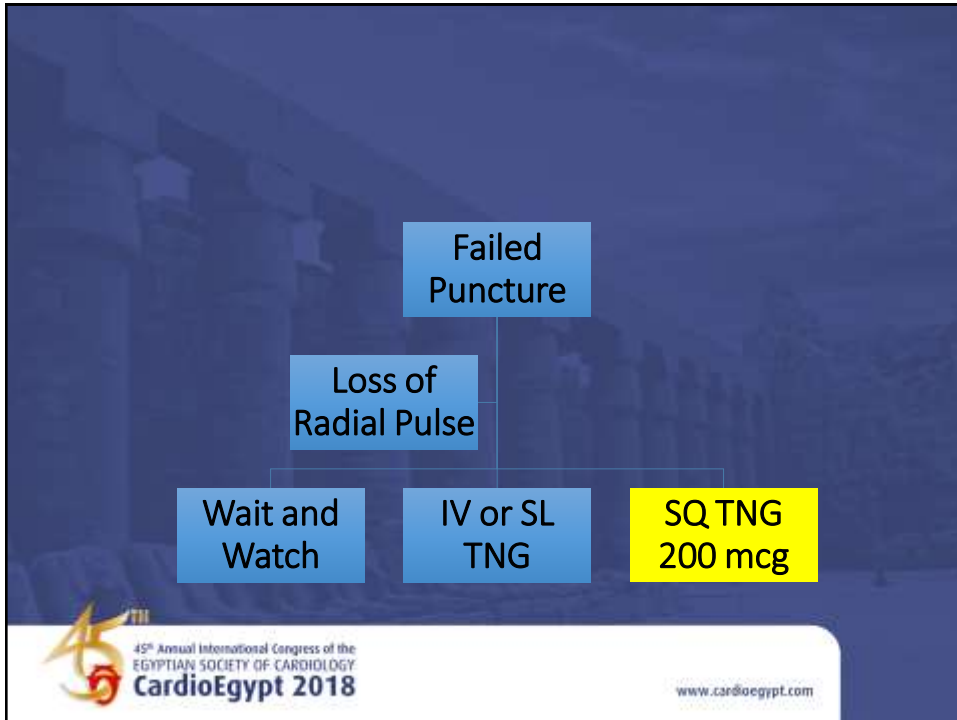
Wait and  
Watch

IV or SL  
TNG

SQ TNG  
200 mcg

45<sup>th</sup> Annual International Congress of the  
EGYPTIAN SOCIETY OF CARDIOLOGY  
**CardioEgypt 2018**

[www.cardioegypt.com](http://www.cardioegypt.com)



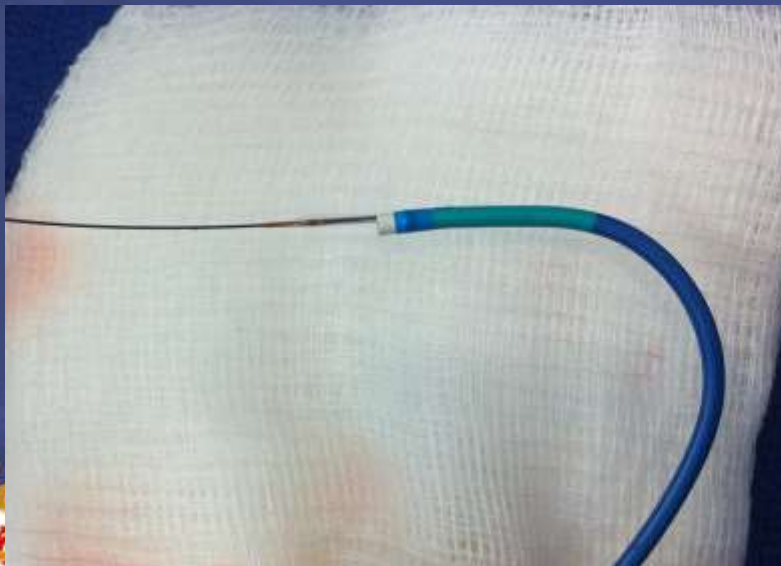
## Balloon-Assisted Tracking

- Difficult anatomy (tortuosity, plaque)
- Spasm
- Catheter transitions create increase in resistance
- Potential for vessel trauma (“Razor effect”)




[www.cardioegypt.com](http://www.cardioegypt.com)


## Guide balloon combo



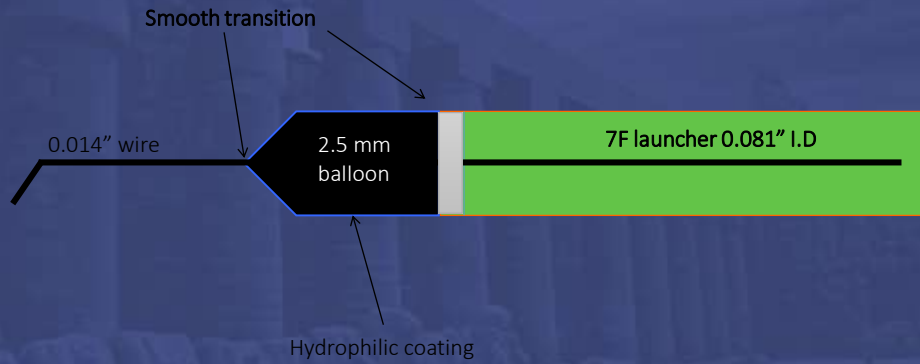
Inflate balloon



Inflate balloon



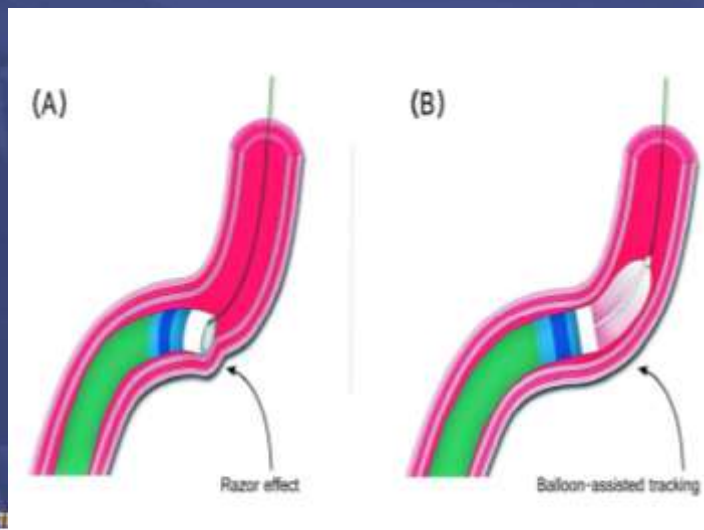
## Balloon-in-catheter



45<sup>th</sup> Annual International Congress of the  
EGYPTIAN SOCIETY OF CARDIOLOGY  
**CardioEgypt 2018**

[www.cardioegypt.com](http://www.cardioegypt.com)

## Razor Effect



45<sup>th</sup> Annual International Congress of the  
EGYPTIAN SOCIETY OF CARDIOLOGY  
**CardioEgypt 2018**

Patel T, Shah S, Pancholy S, et al CCI; 2012

## How to relieve kink



45<sup>th</sup> Annual International Congress of the  
EGYPTIAN SOCIETY OF CARDIOLOGY  
**CardioEgypt 2018**

[www.cardioegypt.com](http://www.cardioegypt.com)

## Catheter kinking

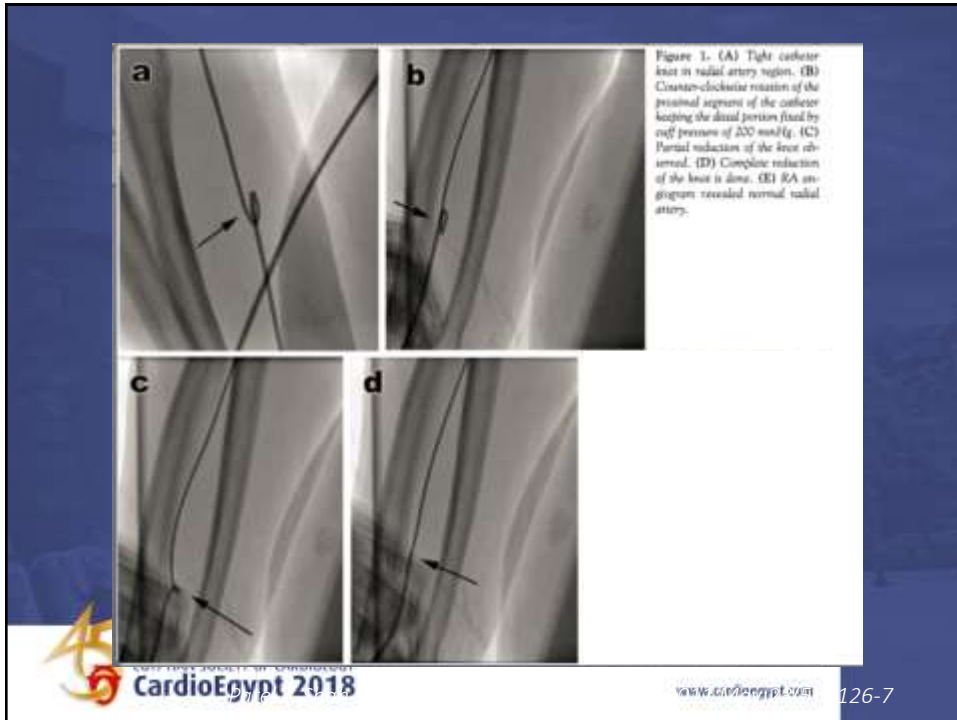
- BP cuff technique
- Snare



45<sup>th</sup> Annual International Congress of the  
EGYPTIAN SOCIETY OF CARDIOLOGY  
**CardioEgypt 2018**

[www.cardioegypt.com](http://www.cardioegypt.com)



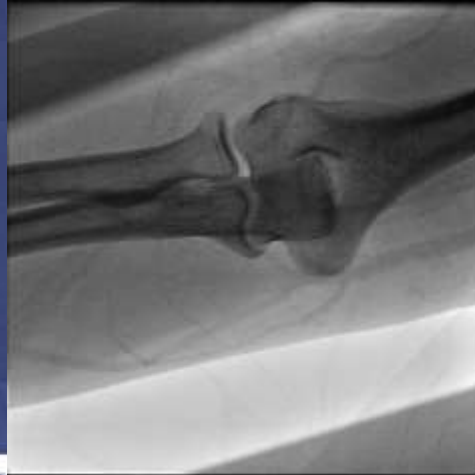

## Venous access

- Difficult intravenous access
- Ultrasound guided entry
  - No radiation
  - Needs equipment, training, time

Pancholy SB, Sweeney J.  
*Catheter Cardiovasc Interv.* 2011 Nov 1;78(5):809-12.

# Levophase venogram

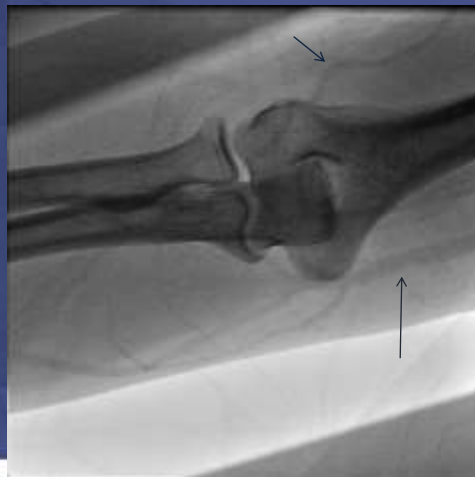

45<sup>th</sup> Annual International Congress of the  
EGYPTIAN SOCIETY OF CARDIOLOGY  
**CardioEgypt 2018**

[www.cardioegypt.com](http://www.cardioegypt.com)

Pancholy SB, Sweeney J.  
*Catheter Cardiovasc Interv.* 2011 Nov 1;78(5):809-12.

# Levophase venogram

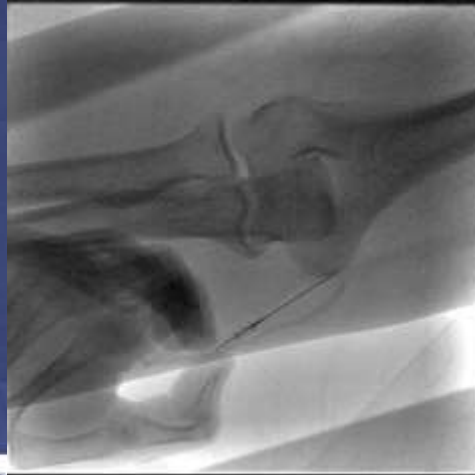


45<sup>th</sup> Annual International Congress of the  
EGYPTIAN SOCIETY OF CARDIOLOGY  
**CardioEgypt 2018**

[www.cardioegypt.com](http://www.cardioegypt.com)

Pancholy SB, Sweeney J.  
*Catheter Cardiovasc Interv.* 2011 Nov 1;78(5):809-12.

## Venous puncture

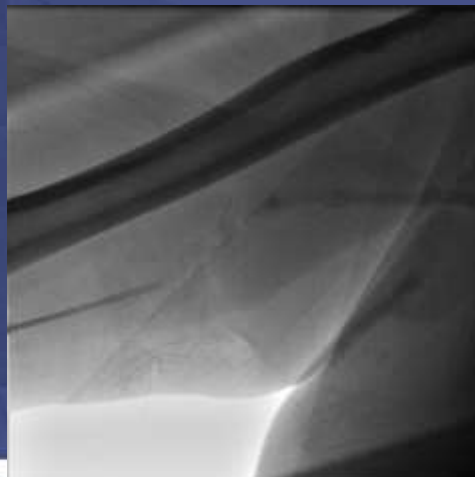


45<sup>th</sup> Annual International Congress of the  
EGYPTIAN SOCIETY OF CARDIOLOGY  
**CardioEgypt 2018**

[www.cardioegypt.com](http://www.cardioegypt.com)

Pancholy SB, Sweeney J.  
*Catheter Cardiovasc Interv.* 2011 Nov 1;78(5):809-12.

## Sheath insertion



45<sup>th</sup> Annual International Congress of the  
EGYPTIAN SOCIETY OF CARDIOLOGY  
**CardioEgypt 2018**

[www.cardioegypt.com](http://www.cardioegypt.com)

## Trouble further up



[www.cardioegypt.com](http://www.cardioegypt.com)

## Swan not entering RV from RA

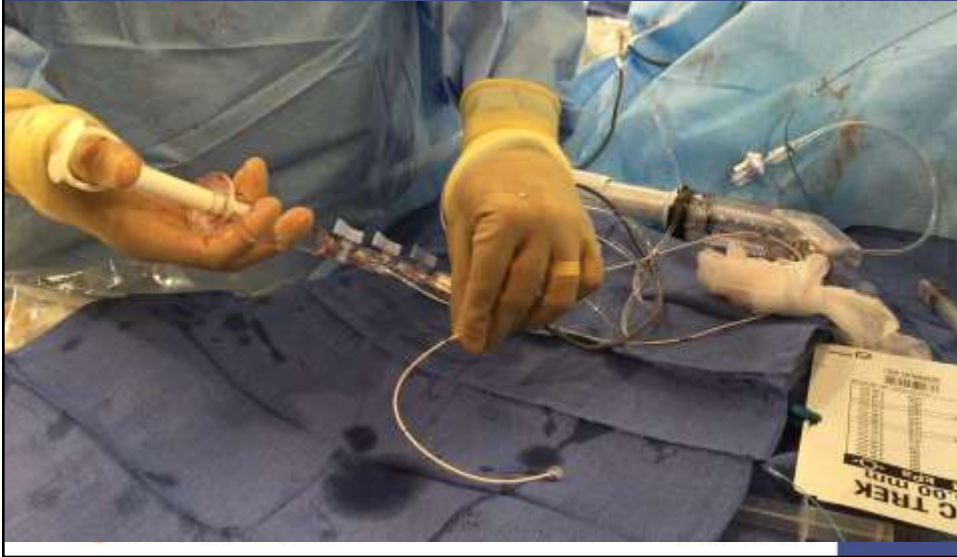- Due to RAE
- Tricuspid valve, instead of having a “funnel shaped” inflow, becomes a “volcano crater” like structure on a dilated RA base, making it difficult to cross with a soft catheter.
- PA catheter enters RAA, isthmus etc and loops
- Usually a guidewire is needed to “stiffen” and “straighten” the PA catheter.



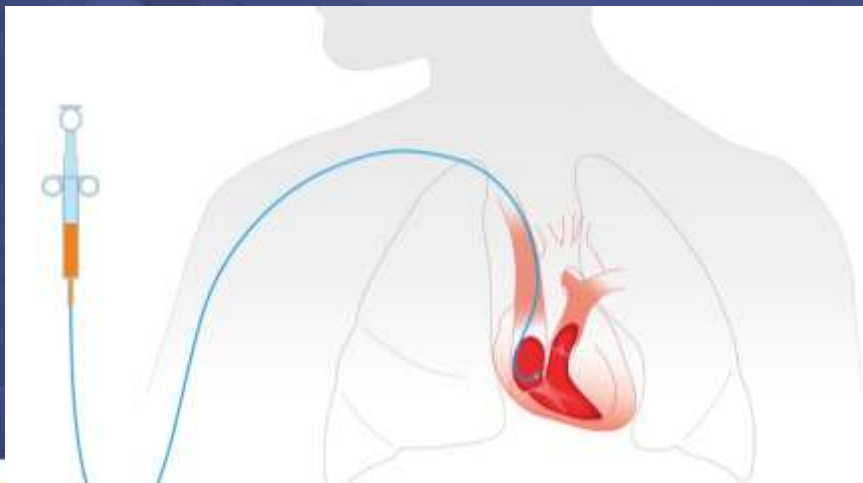
[www.cardioegypt.com](http://www.cardioegypt.com)

Pancholy SB, Vayada N. Catheter Cardiovasc Interv. 2014

# Inject 10 ml of saline rapidly



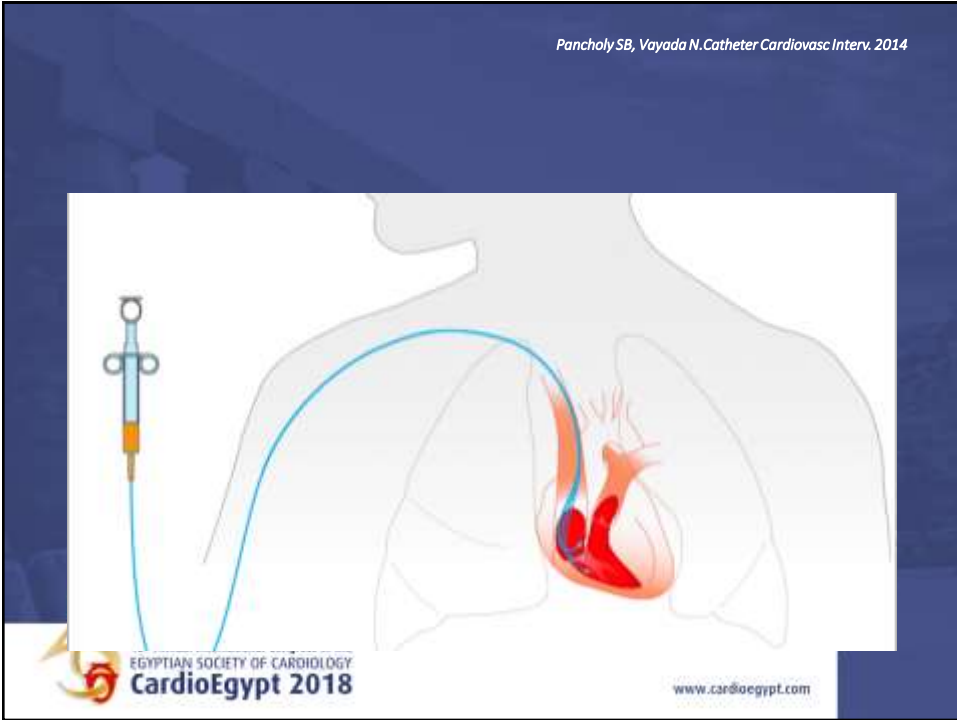
Pancholy SB, Vayada N. Catheter Cardiovasc Interv. 2014



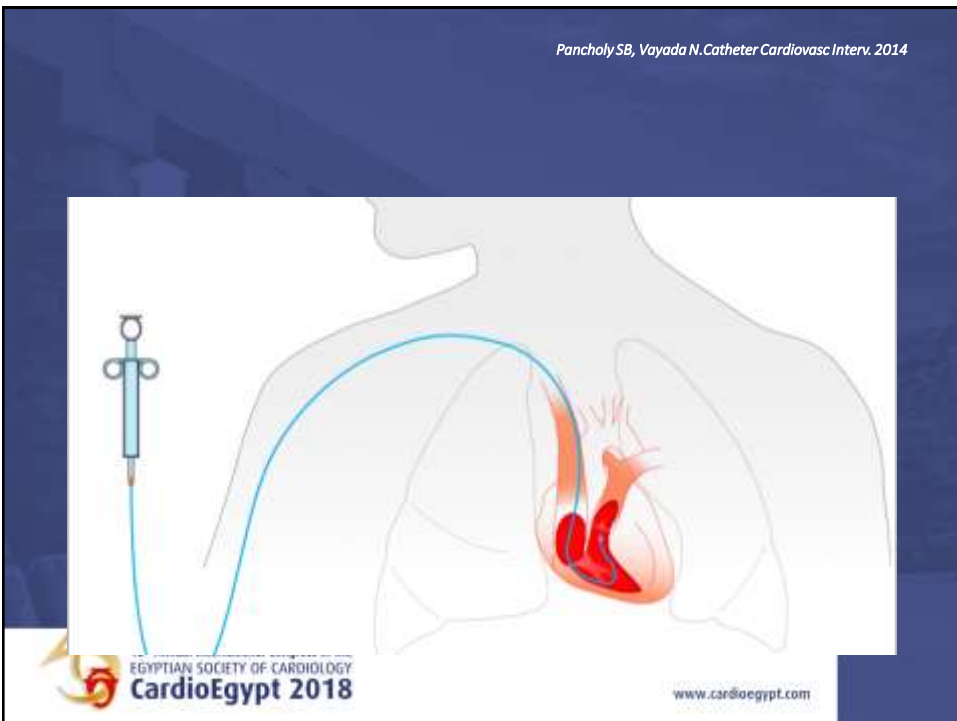
EGYPTIAN SOCIETY OF CARDIOLOGY  
**CardioEgypt 2018**

[www.cardioegypt.com](http://www.cardioegypt.com)

Pancholy SB, Vayada N. *Catheter Cardiovasc Interv.* 2014



Pancholy SB, Vayada N. *Catheter Cardiovasc Interv.* 2014



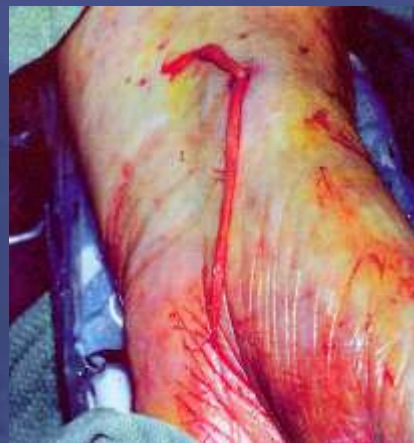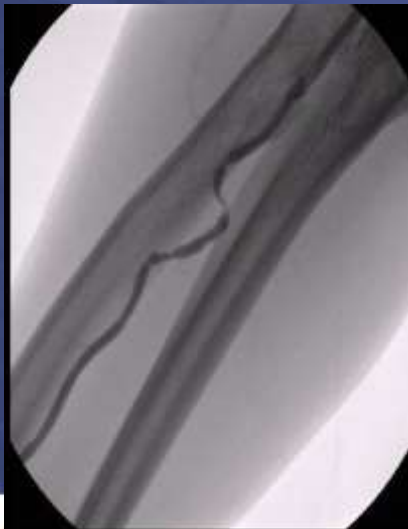## I want my mommy

- The case went well.....☺☺☺☺
- I bragged a lot..... ☺☺☺☺
- Sheath will not come out ☹☹☹☹
- Patient screams when I pull the sheath☹☹☹☹:(



www.cardioegypt.com

## Consequences of Spasm and Eversion



Dieter RS et al. Catheter Cardiovasc Interv 2003;58:478-80



www.cardioegypt.com

## RELAX

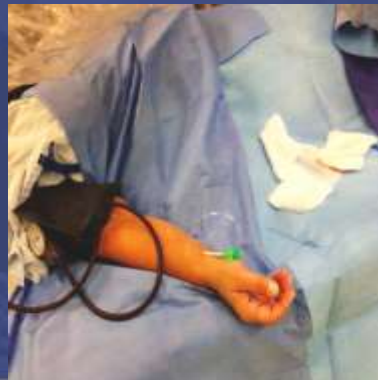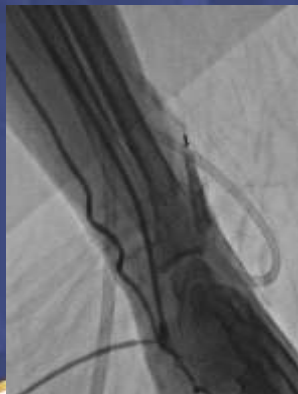- More Sedation the patient (and staff+yourself)
- Warm up the room temperature
- If HR/BP allow, give additional vasodilators
- Time



[www.cardioegypt.com](http://www.cardioegypt.com)

## A Novel Nonpharmacologic Technique to Remove Entrapped Radial Sheath

Samir B. Pancholy,<sup>1\*</sup> MD, FACP, FACC, FSCAI, Poorna Rajasekhar Karuparthi,<sup>2</sup> MD, and  
Rajiv Gulati,<sup>3</sup> MD, FACC, FSCAI *CCI 2014*

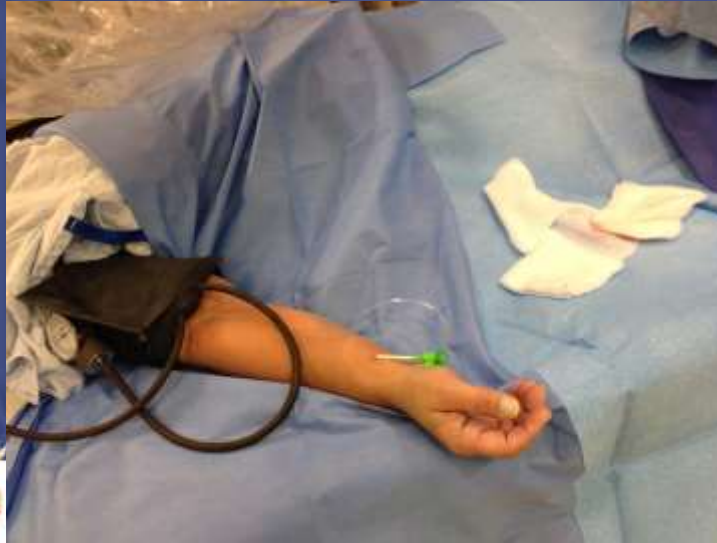

[www.cardioegypt.com](http://www.cardioegypt.com)



Pancholy SB, et al. *Catheter Cardiovasc Interv.* 2014

SBP + 40 mmHg X 5 min



## Need a Trick, Got a Trick!

- [www.transradialworld.org](http://www.transradialworld.org)
- [pancholy8@gmail.com](mailto:pancholy8@gmail.com)
- 570-840-9852 (Text first please)