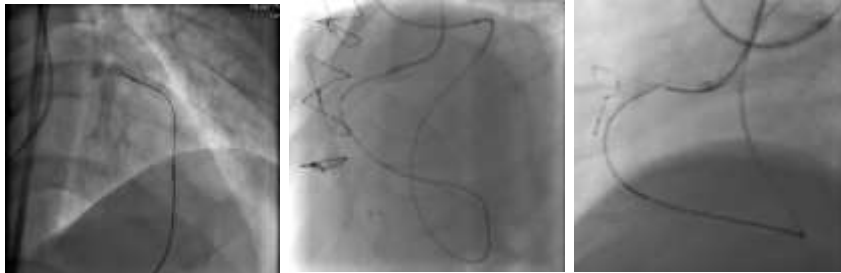

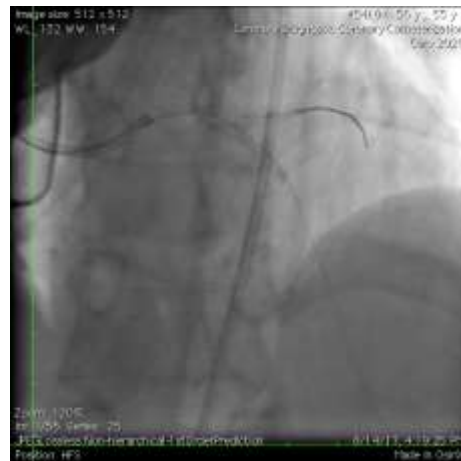
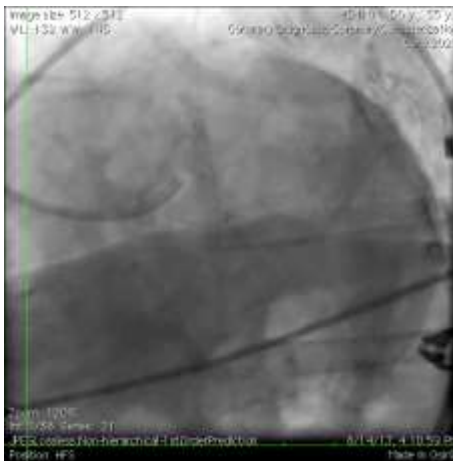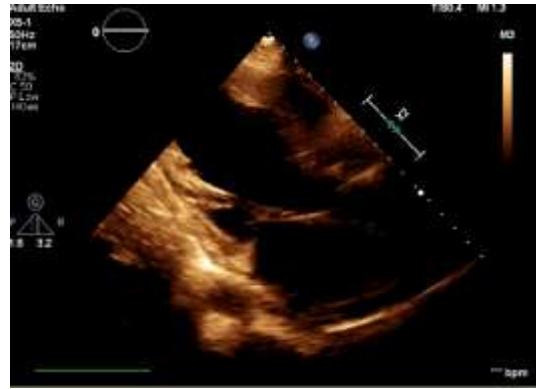
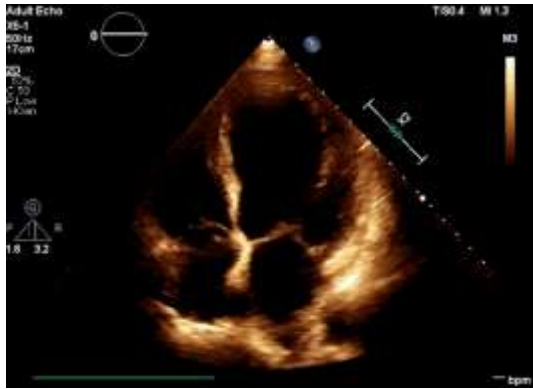PCI in a patient with severely depressed LV function

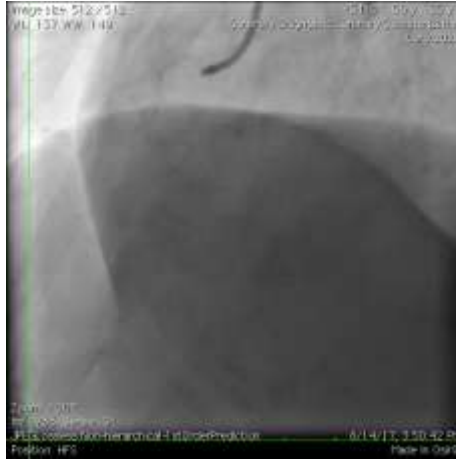Ahmed M. ElGuindy, MD, MRCP, FACC



Clinical data

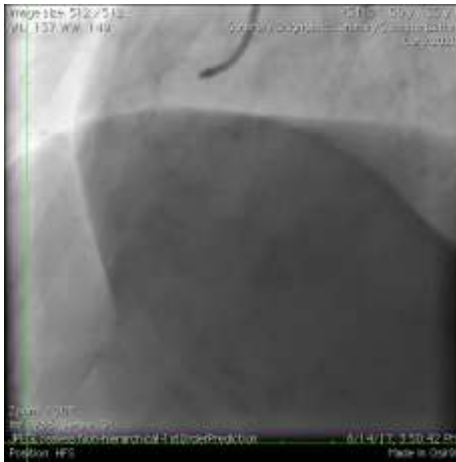- 56 year-old female
- Presenting crescendo angina and SOB over the past 2 months
- Type 2 DM, HTN
- EF=15-20%
- Moderate MR
- Severe pulmonary HTN



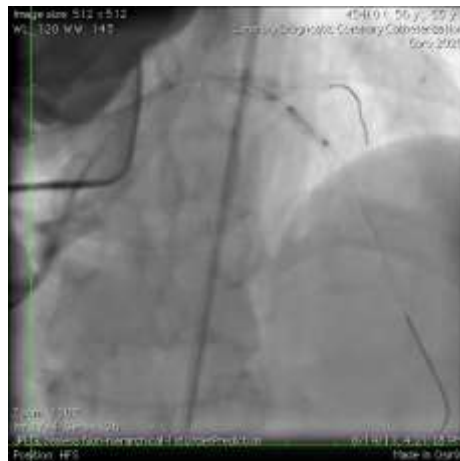
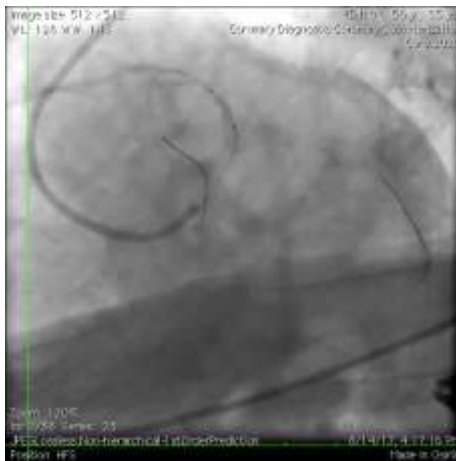


Heart Team Decision: PCI



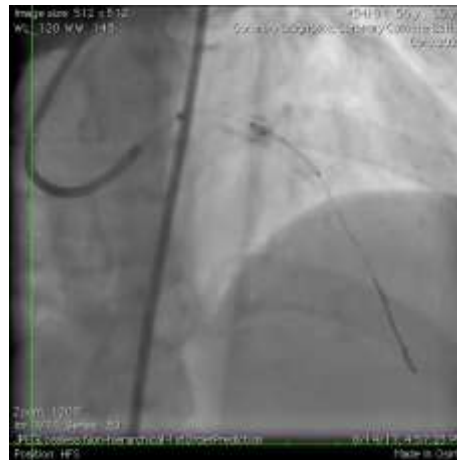
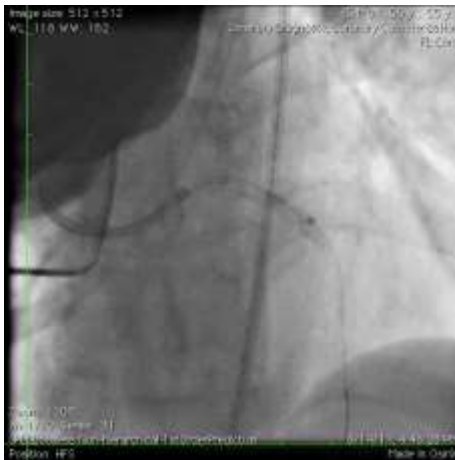
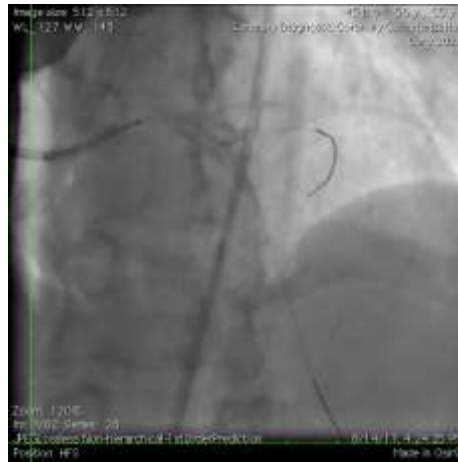
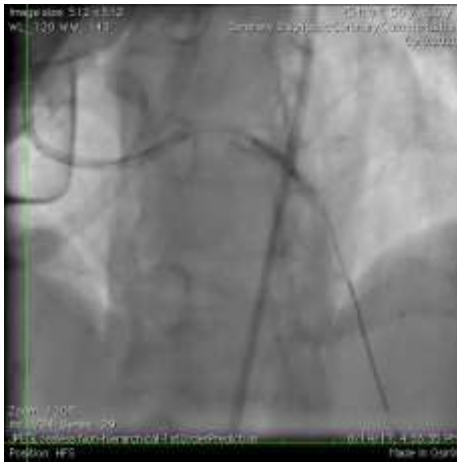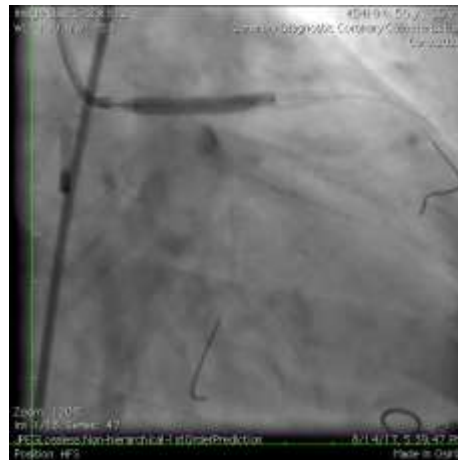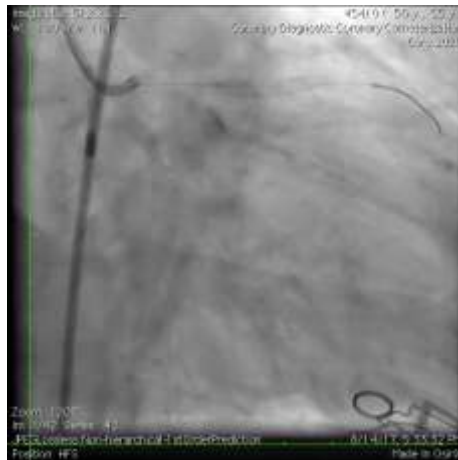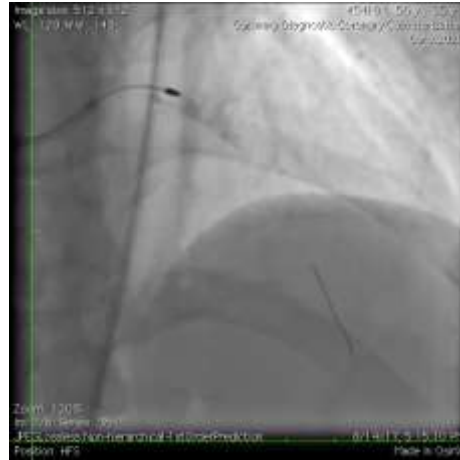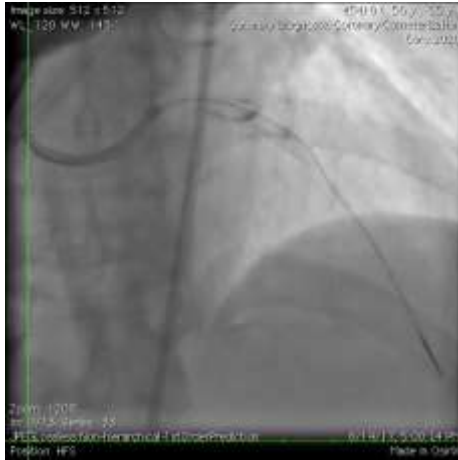ARWAN HEART CENTER
MAGDI YACOUB
FOUNDATION

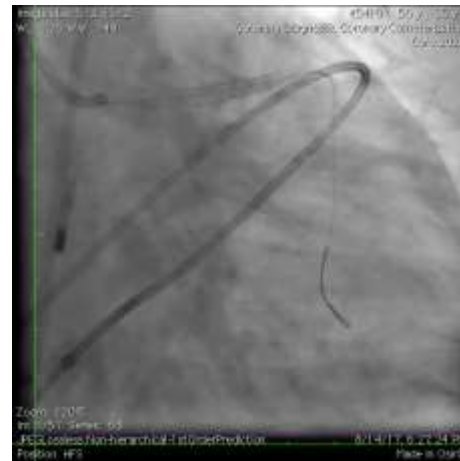
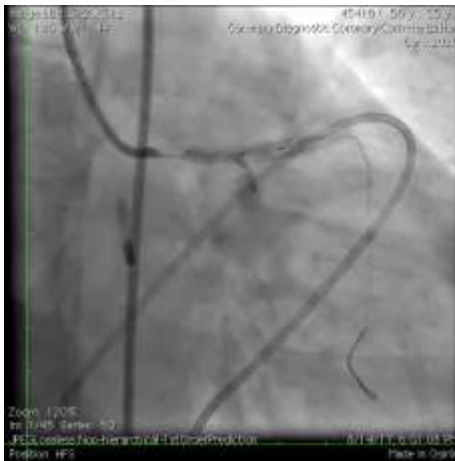
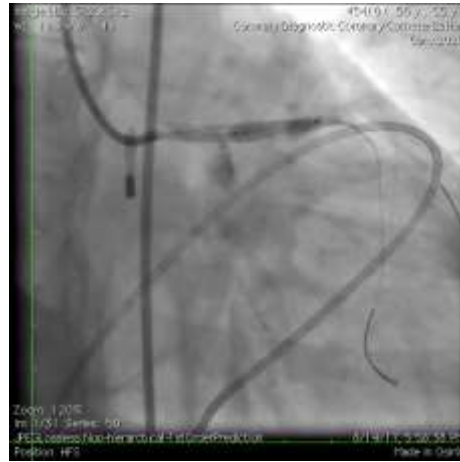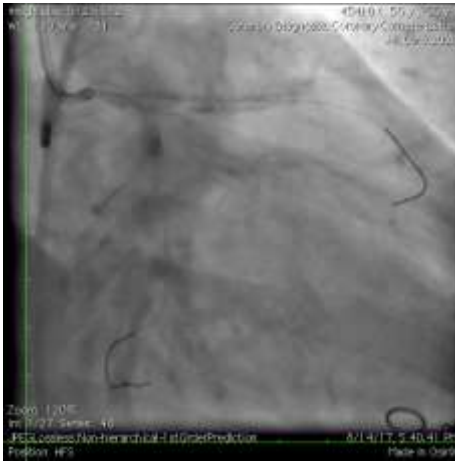ARWAN HEART CENTER
MAGDI YACOUB
FOUNDATION

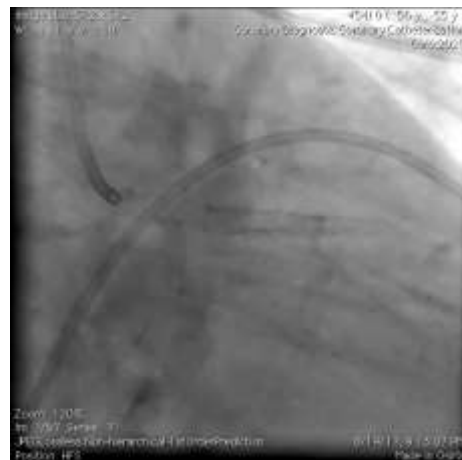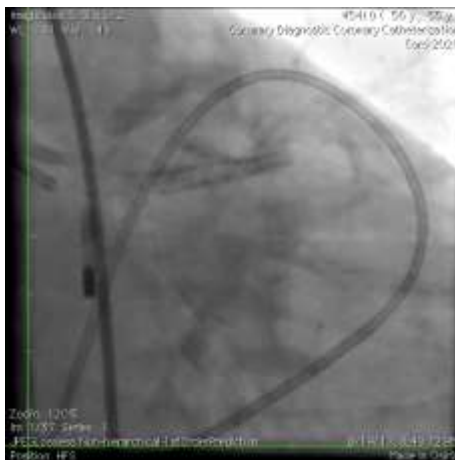








- Transferred to the ITU with good hemodynamics
- Pigtail left insitu
- 8 hours later: hypotension and 100 cc drained from pigtail



Imperial College
London



AWWAN HERZOG CENTER
MAGDI YACOUB
FOUNDATION

