


DZHK
DEUTSCHES ZENTRUM FÜR
HERZ-KREISLAUF-FORSCHUNG E.V.




UNIVERSITÄTSmedizin.
MAINZ


PCI in a patient with left main disease A case that went badly

Tommaso Gori

Universitätsmedizin der Johannes Gutenberg-Universität Mainz
Deutsches Zentrum für Herz und Kreislauf Forschung, Standort Rhein-Main



DZHK
DEUTSCHES ZENTRUM FÜR
HERZ-KREISLAUF-FORSCHUNG E.V.



UNIVERSITÄTSmedizin.
MAINZ

Man, 63j.o.

3-vessel CAD
Hx Stent RCA/RIVA/RX 2010-2015
TI-Scintigraphy 12/2016: Ischemia of the anterior and inferior wall
No angina
LVEF 55%

CVRF: aHT, HLP, pos. FA

High-grade stenosis ACI right (NASCET 80-90%)

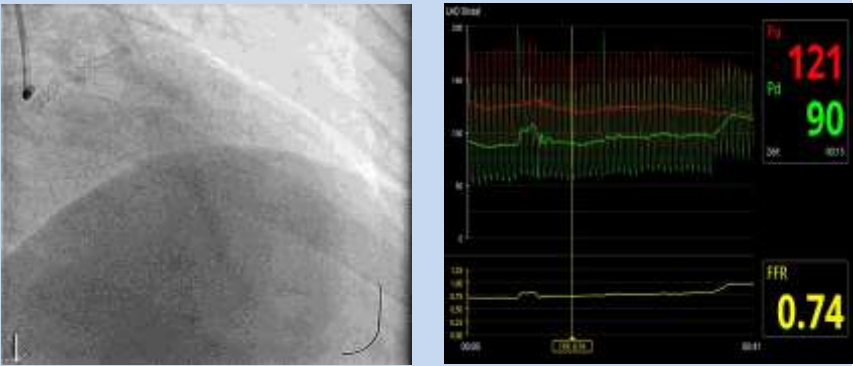
Chronic kidney failure, GFR 57ml/min

Depression
...

DZHK
DEUTSCHES ZENTRUM FÜR
HERZ-KREBLAUF-FORSCHUNG E.V.

UNIVERSITÄTSMEDIZIN
MANNHEIM

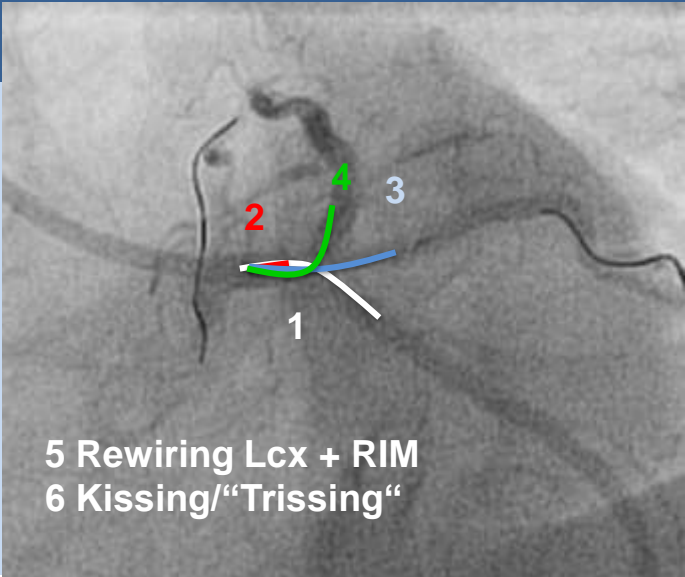
FFR RIVA



The image displays two panels. The left panel is a grayscale coronary angiogram showing a catheter inserted into a coronary artery. The right panel is a hemodynamic monitoring screen with a black background. It features two line graphs: a top graph with a red line and a bottom graph with a green line. On the right side of the screen, three numerical values are displayed: '121' in red, '90' in green, and '0.74' in yellow. The '0.74' value is labeled 'FFR'.


DZHK
DEUTSCHES ZENTRUM FÜR
HERZ-KREBLAUF-FORSCHUNG E.V.


UNIVERSITÄTSMEDIZIN
MANNHEIM



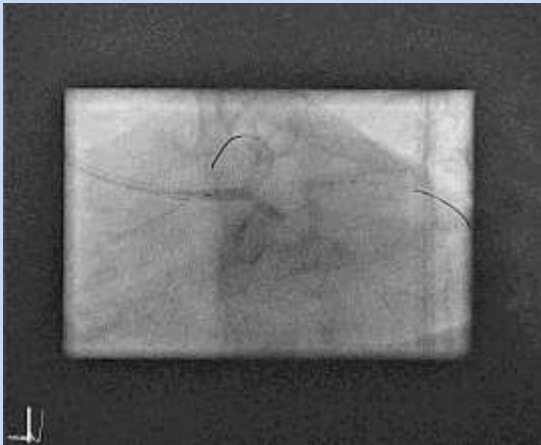
The image is a grayscale coronary angiogram showing a complex network of coronary arteries. Several catheters are visible, with three specific points marked by numbers: '1' in white, '2' in red, and '3' in white. A green arrow points upwards from point 2, and a blue arrow points to the right from point 1. A white arrow points downwards from point 1.

5 Rewiring Lcx + RIM
6 Kissing/“Trissing“


 **DZHK**
DEUTSCHES ZENTRUM FÜR
HERZ-KREBLAUF-FORSCHUNG E.V.


 **UNIVERSITÄTSmedizin.**
MAINZ

LM – PTCA NC Trek 3.0x20mm, 16ATM

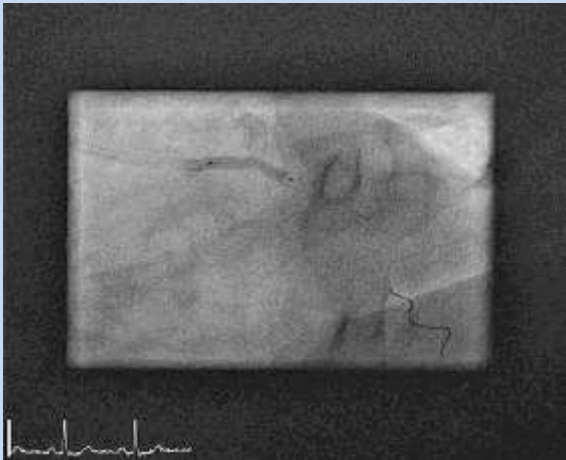


13:19
5000IE Hep


 **DZHK**
DEUTSCHES ZENTRUM FÜR
HERZ-KREBLAUF-FORSCHUNG E.V.


 **UNIVERSITÄTSmedizin.**
MAINZ

Stent Xience 3.0x23mm, 16ATM

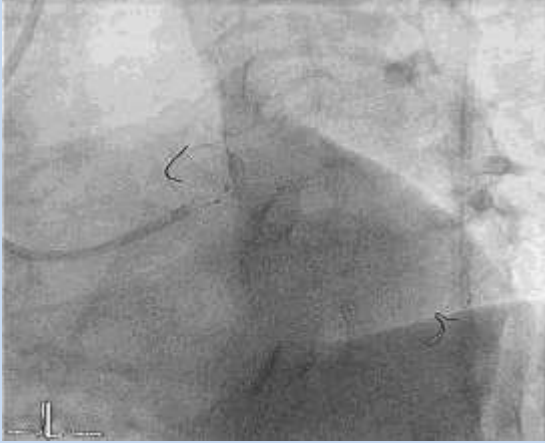


13:29
Followed by
POT with 3.5mm NC


 DZHK
DEUTSCHES ZENTRUM FÜR
HERZ-KREBLAUF-FORSCHUNG E.V.


 UNIVERSITÄT **medizin.**
MAINZ

Kissing with 3.0mm Maverick Ballons



13:49
ACT 149sec.
5000IE Heparin


 DZHK
DEUTSCHES ZENTRUM FÜR
HERZ-KREBLAUF-FORSCHUNG E.V.


 UNIVERSITÄT **medizin.**
MAINZ


Kissing with 2.0mm Ballons

Is one of the wires wrong?

- LAD Wire is pulled out
- Rewiring does not work

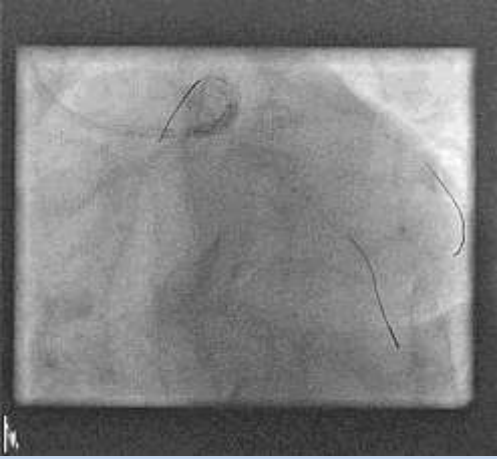



 **DZHK**
DEUTSCHES ZENTRUM FÜR
HERZ-KREBLAUF-FORSCHUNG E.V.


 **UNIVERSITÄTSMEDIZIN.**
MAINZ

LAD

Rewiring of LAD
PTCA with Maverick 3.0mm

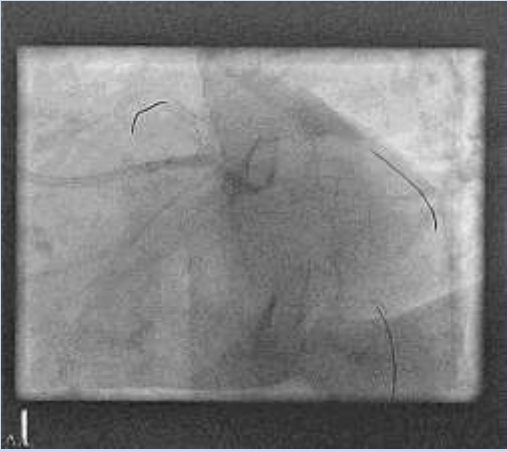


 **DZHK**
DEUTSCHES ZENTRUM FÜR
HERZ-KREBLAUF-FORSCHUNG E.V.

 **UNIVERSITÄTSMEDIZIN.**
MAINZ

LCX

PTCA with Maverick 3.0mm



DZHK
DEUTSCHES ZENTRUM FÜR
HERZ-KREBLAUF-FORSCHUNG E.V.

UNIVERSITÄTSmedizin.
MANNHEIM

Kissing

DZHK
DEUTSCHES ZENTRUM FÜR
HERZ-KREBLAUF-FORSCHUNG E.V.

UNIVERSITÄTSmedizin.
MANNHEIM

Kissing

What did I learn from this case

Don't read too many books

Be generous with Heparin

Look at time

Use a simple strategy (Culotte is not the best anyways)

Reverse TAP à la Mainz

