

# Case presentation

Overconfidence always leads to complications

---

TAREK RASHID, MD  
AINSHAMS UNIVERSITY

## History

---

**General data:**

- Female patient
- 62 years

**Risk factors:**

- HTN
- Dyslipidemic

- Started to C/O of exertional angina for 2 years
- Accelerated to Exertional angina class III over the last few months

## Investigations

---

### Laboratory tests

- S. creat. 0.9 mg%
- HbA1c 5.5%
- E GFR 78 ml/min

### ECG:

- Normal sinus rhythm
- T wave inversions inferolateral

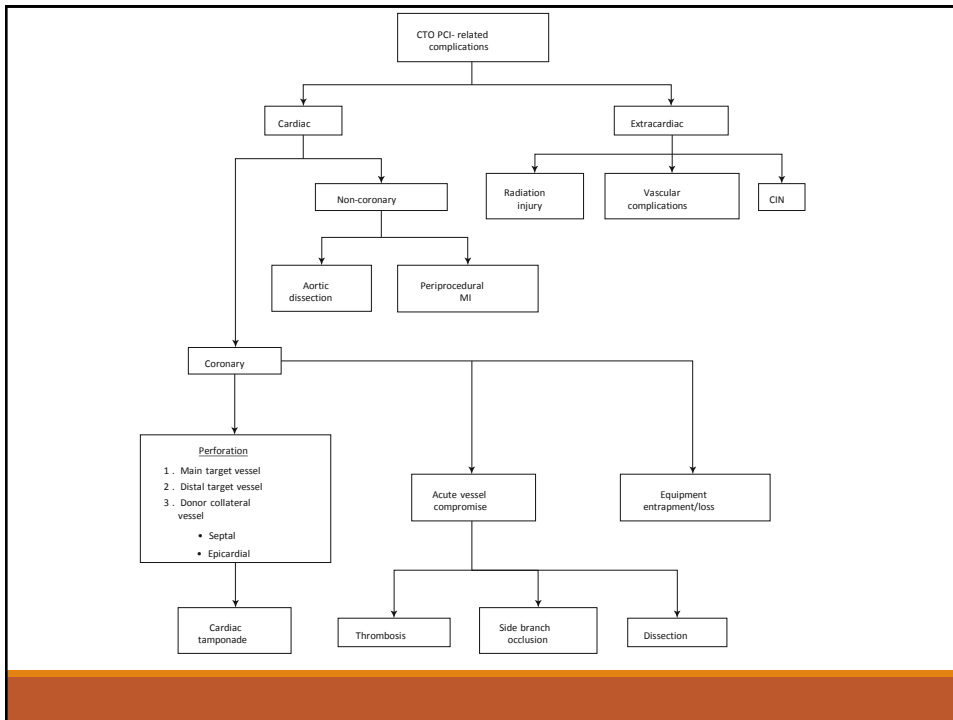
### Echocardiography:

- EF 56%
- Diastolic dysfunction grade I
- No SWMA

## CCU course

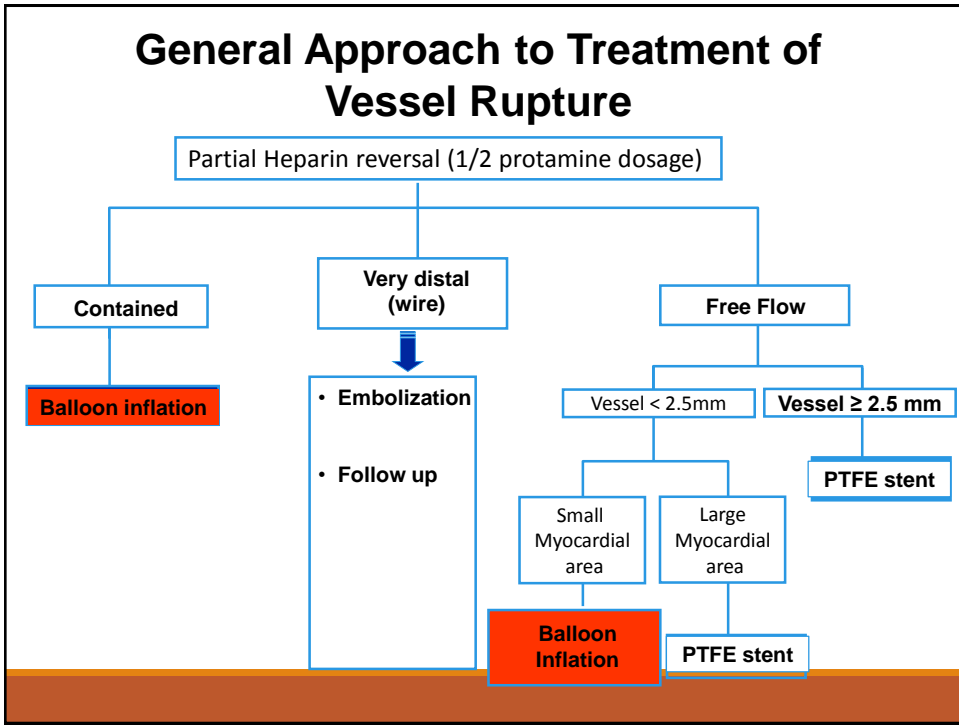
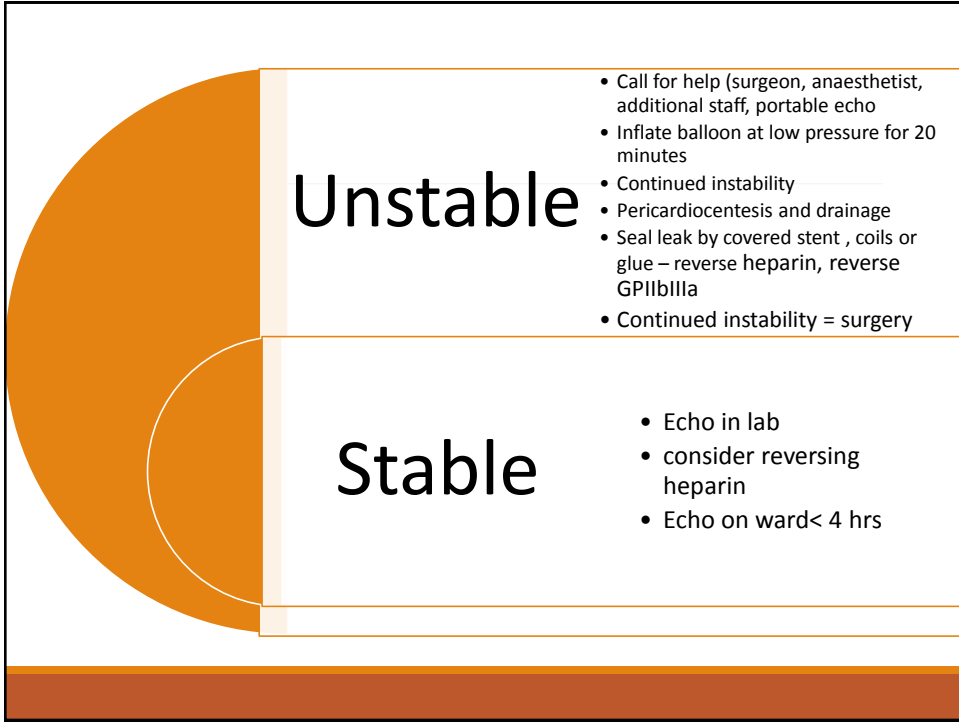
---

- Patient transferred to the CCU in a stable condition
- Follow up echocardiography revealed no reaccumulation of the effusion
- Kept under observation for 48 hours
- Discharged home safely in a good condition
- 1 month clinical follow revealed improvement of the angina
- Scheduled for PCI to LAD



## Coronary perforation

- Anatomical breach in the integrity of tunica adventitia of an epicardial artery leading to extravasation of blood.
- CTO is the area of intervention with most prominent association
- Can be caused by oversized balloons, balloon rupture, aggressive stent post dilatation, laser therapy, excessive rotablation or guidwire exit
- Types:
  - type I extraluminal crater without extravasation
  - type II pericardial or myocardial blushing without extravasation
  - type III active jet extravasation
  - type IV Cavity spilling
  - type V distal perforation
- When to suspect? (errant wire position, unexplained hypotension or tachycardia, use of hydrophilic or stiff wires, extraluminal angiographic staining or extravasation)



## Take Home Message

---

- CTO PCI carries a higher risk of coronary perforations compared to non-CTO (2.9% vs. 0.2%)
- In CTO PCI dual catheter injection is mandatory to delineate the natural course of the distal target vessel and identify branches in order to minimize the complications
- Exchanging the stiffer wires for workhorse wires after successful CTO crossing can minimize the risk of perforation
- It is critical that all catheterization centers performing CTO PCI have emergency equipment immediately available to treat perforated coronary vessel which includes a pericardiocentesis kit, covered stents, embolization equipment and two-dimensional echocardiography machine

# Thank You

Tarek Rashid

