

I truly Didn't Expect It

Waleed EL-Awady

A. Professor of Cardiology

Case Scenario

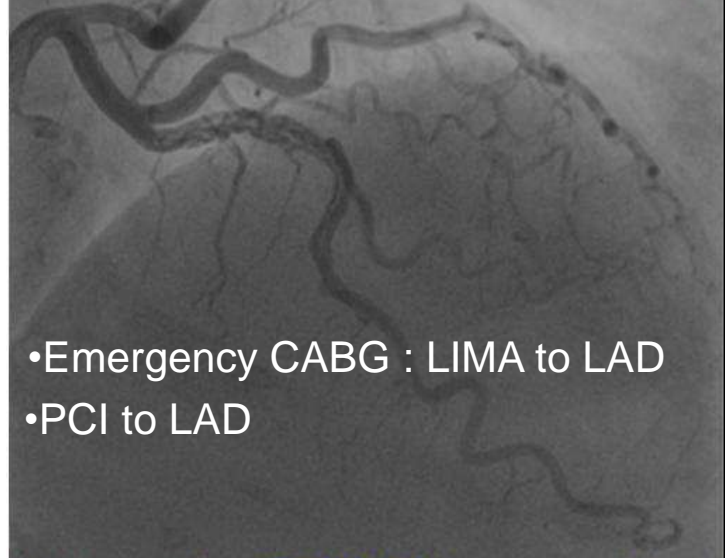
- Female
- 40 yrs
- Sudden severe chest pain
- ECG: ST elevation in all precordial leads
- Received thrombolytic therapy that was unsuccessful → persistent chest pain

Coronary Angiography

Decision

Samira Mohamed Elzanaty
F
722010-831-201401221351543

DR:Waleed ElAwady
722010-831 100129643 50019128 01 0 0041
20140122
135202.157



- Emergency CABG : LIMA to LAD
- PCI to LAD

Lao - 1 deg ,Cran - 31 deg
Zoom: 99%

SoftLink

Run 3 Of 49
Frame 35 Of 67

Circulation

JOURNAL OF THE AMERICAN HEART ASSOCIATION



Clinical Features, Management, and Prognosis of Spontaneous Coronary Artery Dissection

Marysia S. Tweet, Sharonne N. Hayes, ~~Sridevi R. Pitta~~, Robert D. Simari, Amir Lerman, Ryan J. Lennon, Bernard J. Gersh, Sherezade Khambatta, Patricia J.M. Best, Charanjit S. Rihal and Rajiv Gulati

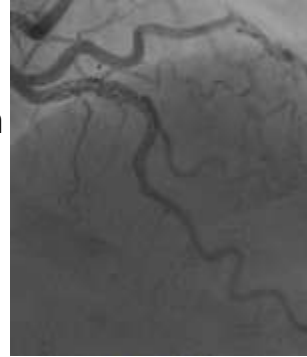
Circulation. 2012;126:579-588; originally published online July 16, 2012;

In this regard, PCI was associated with elevated rates of technical failure relating to passage of coronary wire into the false lumen of the dissected vessel or loss of coronary flow through propagation of dissection and displacement of intramural hematoma by stent placement. This underscores the

**Spontaneous Coronary Dissection:
Causes of PCI failure**

Wiring The False lumen can Result in :

- Propagation of dissection
- Balloon dilatation in the false lumen
- Stent implantation in the false lumen
- Displaced intramural hematoma
- Acute occlusion of the true lumen
- Acute occlusion of side branches
- Perforation



**Wiring and identification of
the true lumen is essential
for success !!!!!**

Identification of the True Lumen

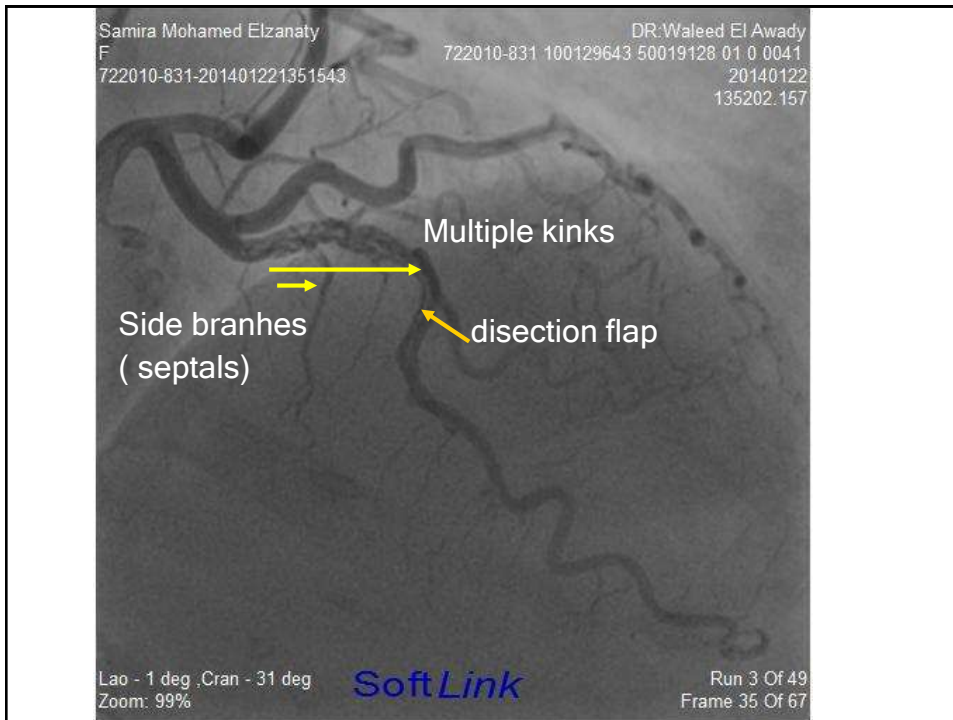
- IVUS
- OCT
- Micro - catheters
- Twin Pass Dual Access Catheter



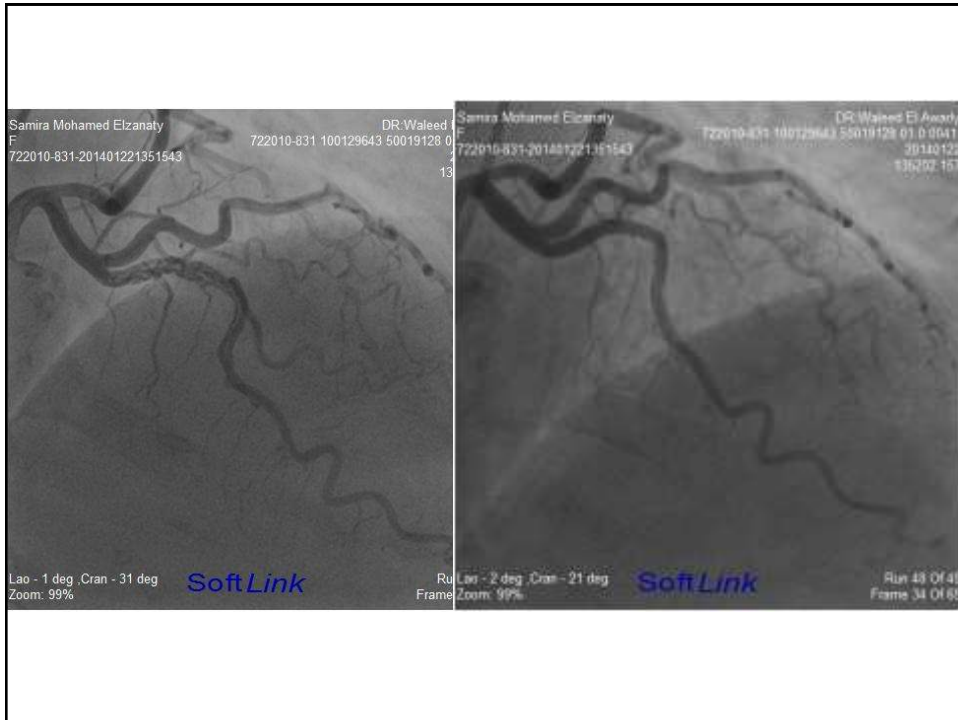PCI was planned

- Rt femoral
- Guiding Catheter: Support ?
 - JL 3.5
- Wire: Floppy
- First: multiple trials were failed to pass the wire

Technical challenges



- Some cautious balloon support (1.5X10)
- Finally the wire passed to Distal LAD
- The balloon passed easily across the wire
- Predilatation : 2 X20....2.75 X 20



Home Message

- Spontaneous coronary dissection is a rare etiology of STEMI that can be observed in the elderly as well as in young patients
- Identification of the true lumen is the key step during the treatment of dissections

Home Message

- Identification of the true lumen is feasible by IVUS, OCT, Twin pass catheter
- If we don't have these tools, wiring will be difficult and risky but feasible depending on tactile sense by the operator

Thank You