



# The role of MPI in the assessment of anatomically non significant coronary artery lesions .

*Mona M Rayan*  
*Professor of cardiology*  
*Ain shams university.*

## Outline

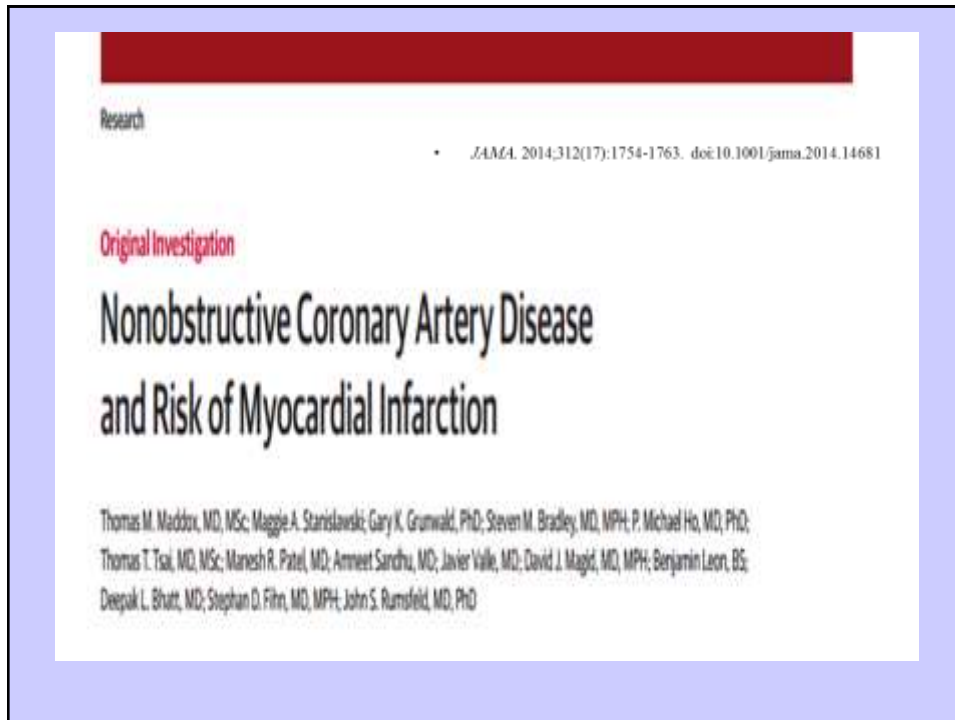- Definition of non significant lesions.
- Non obstructive lesions, are they truly non obstructive and benign?
- Noninvasive assessment of the functional significance of non obstructive lesions . Is this a matter of right or wrong ?
- Case presentations

Among the advanced cardiac imaging modalities, multislice computed tomography (MSCT) coronary angiography is emerging as a reliable non-invasive method for the assessment of coronary artery disease (CAD), coronary anatomy and cardiac function.

- CAD extent as defined by the degree of plaque burden and lumen obstruction include:
  - No apparent CAD: no stenosis  $>20\%$
  - *Non-obstructive CAD:  $\geq 1$  stenosis  $> 20\% \leq 70\%$*
  - obstructive CAD: any stenosis  $> 70\%$  or left main stenosis  $\geq 50\%$ ) affecting 1, 2, or 3 vessel.

## *Non obstructive lesions*

*Are they truly benign?*

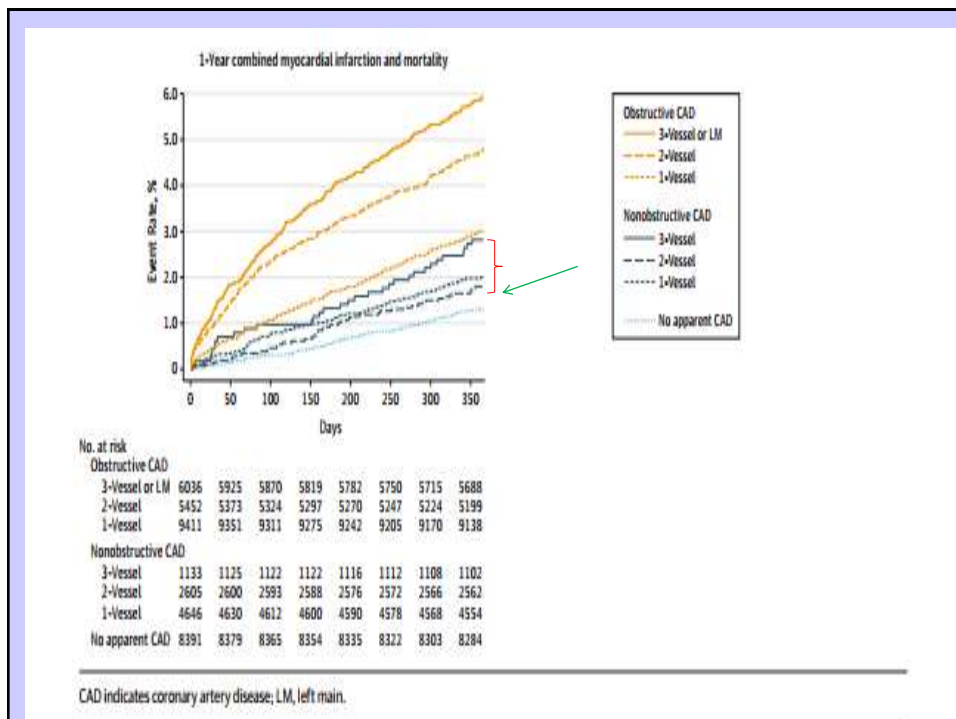


## Study design

- Maddox et al in 2014 carried out a Retrospective study of all patients undergoing elective coronary angiography for CAD between October 2007 and September 2012. Patients with prior CAD events were excluded.
- The primary outcome was 1-year hospitalization for nonfatal MI after the index angiography. Secondary outcomes included 1-year all-cause mortality and combined 1-year MI and mortality.
- JAMA. 2014;312(17):1754-1763. doi:10.1001/jama.2014.14681

## Results

- Among 37 674 patients, 22.3% had non obstructive CAD. Among patients with no apparent CAD, the 1-year MI rate was 0.1% and increased progressively to 0.2% in 1-vessel non-obstructive CAD, 0.6% in 2 and 3 vessel non-obstructive CAD.



## CONCLUSIONS

- In this cohort of patients undergoing elective coronary angiography, non-obstructive CAD, compared with no apparent CAD, was associated with a significantly greater 1-year risk of MI and all-cause mortality.
- These findings suggest the clinical importance of nonobstructive CAD and warrant further investigations to improve outcomes among these patients.

SYSTEMATIC REVIEW AND META-ANALYSIS



### Nonobstructive Versus Obstructive Coronary Artery Disease in Acute Coronary Syndrome: A Meta-Analysis

Carmine Pizzi, MD, FESC; Borejda Xhyheri, MD; Grazia Maria Costa, MD; Massimiliano Faustino, MD; Maria Elena Flacco, MD; Maria Rosaria Gualano, MD, PhD; Giorgia Fragassi, BS; Francesco Grigioni, MD, PhD; Lamberto Manzoli, MD, MPH

## Study design

They included the researches from MedLine, EMBASE, and proceedings of international meetings up to June 2015 to compare the risk of events of NObCAD versus ObCAD patients using meta-analyses.

In NObCAD and ObCAD patients, the combined yearly rates were as follow:

2% versus 10% (all-cause mortality);

1% versus 6% (myocardial infarction),

4% versus 13% (all-cause mortality plus myocardial infarction),

1% versus 6% (cardiac death),

and 9% versus 17% (major cardiovascular events).

## Conclusions

NObCAD in patients with acute coronary syndrome has a significantly lower cardiovascular risk at baseline and a subsequent lower likelihood of death or major cardiovascular events. However, these subjects are still at high risk for cardiovascular mortality and morbidity, suggesting potential under treatment and calling for specific management.

( J Am Heart Assoc. 2016;5:e004185 doi: 10.1161/JAHA.116.004185

Noninvasive assessment of  
the functional significance of  
non significant lesions , is  
this a matter of right or  
wrong ?

## Clinical and angiographic outcome of patients with mild coronary lesions treated with balloon angioplasty or coronary stenting

### Implications for mechanical plaque sealing

N. Mercado<sup>a</sup>, W. Maier<sup>b</sup>, E. Boersma<sup>a\*</sup>, C. Bucher<sup>b</sup>, V. de Valk<sup>c</sup>, W.W. O'Neill<sup>d</sup>, B.J. Gersh<sup>e</sup>, B. Meier<sup>f</sup>, P.W. Serruys<sup>a</sup>, W. Wijns<sup>g</sup>

<sup>a</sup>Thoraxcentre, University Hospital Dijkzigt, Rotterdam, The Netherlands

<sup>b</sup>Department of Cardiology, University Hospital Zurich, Zurich, Switzerland

<sup>c</sup>Cardialysis, Rotterdam, The Netherlands

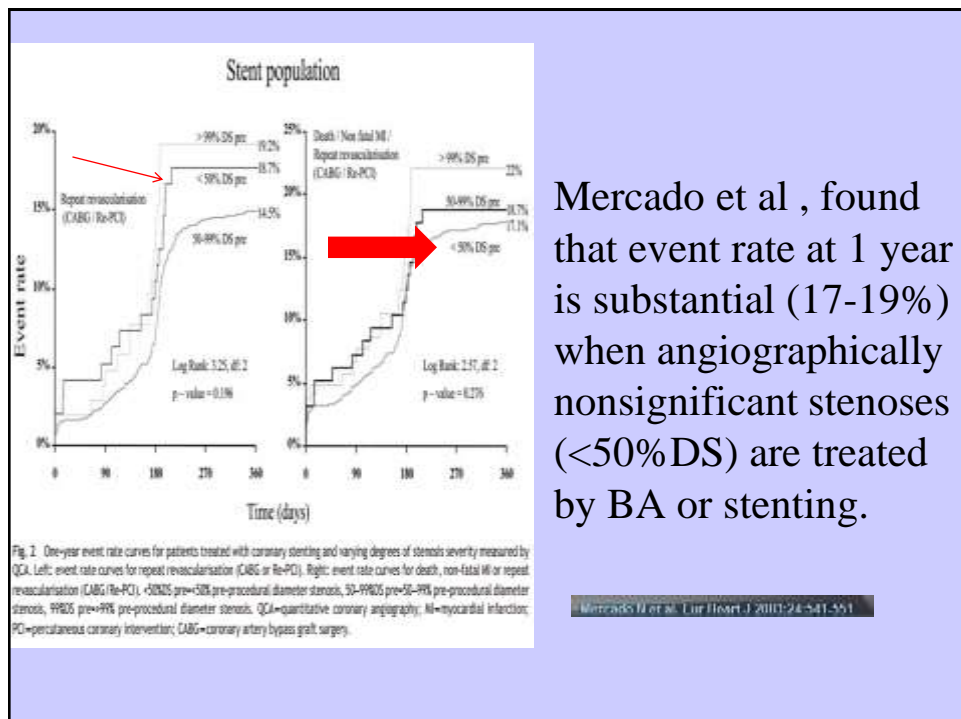
<sup>d</sup>Division of Cardiology, William Beaumont Hospital, Royal Oak, MI, USA

<sup>e</sup>Division of Cardiovascular Diseases, Mayo Clinic, Rochester, MN, USA

<sup>f</sup>Swiss Cardiovascular Centre Bern, University Hospital, Bern, Switzerland

<sup>g</sup>Cardiovascular Centre, Onze Lieve Vrouw Ziekenhuis, Aalst, Belgium

Received 27 March 2002; revised 11 June 2002; accepted 12 June 2002



Mercado et al, found that event rate at 1 year is substantial (17-19%) when angiographically nonsignificant stenoses (<50% DS) are treated by BA or stenting.



***Guidelines recommend noninvasive tests to risk stratify and identify patients with higher likelihood of coronary artery disease prior to elective coronary angiography. However, a high percentage of patients are found to have non-obstructive CAD.***

***This led to the inclusion of a combination of anatomical images with functional parameters in recent imaging strategies (hybrid imaging). Examples include a combination of CCTA with MPI (CCTA/MPI), CCTA with perfusion computed tomography (CCTA/CTP), CCTA with FFRCT (FFR calculated by CCTA), and CMRI perfusion images and cardiac perfusion PET.***

## **Case presentation**

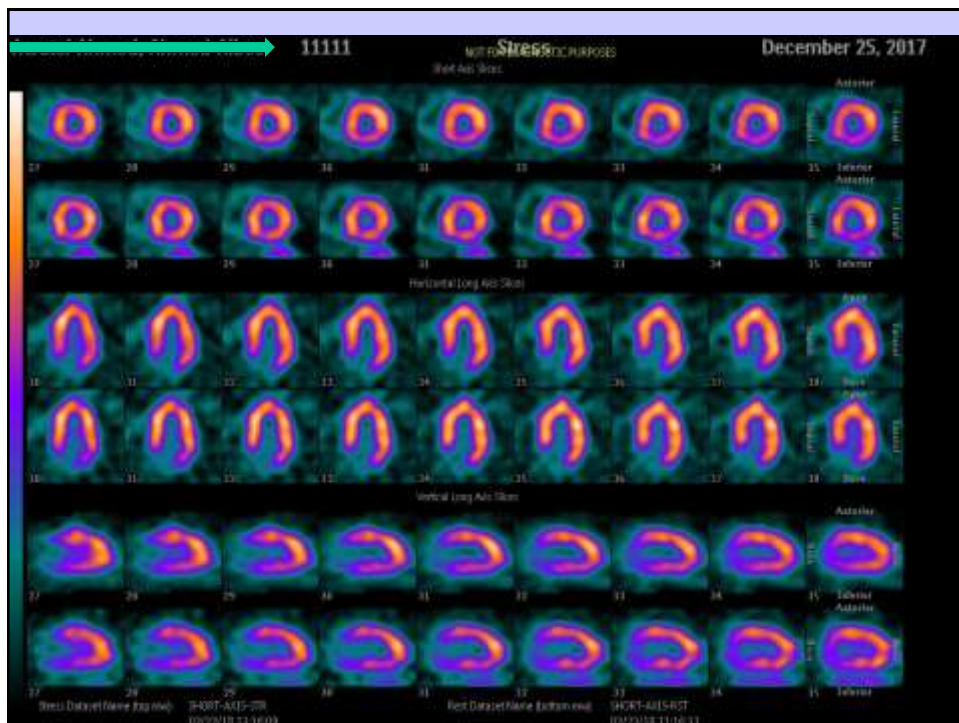
Throughout the 2<sup>nd</sup> half of 2017 , in Ain shams university MPI lab, we performed 900 studies. The main indication in 20% of these studies was the assessment of non significant lesions whether native vessel or after revascularization.

## Case 1

61 year old female patient , diabetic  
hypertensive c/o chest pain. Cardiac cath.  
showed 40% LAD lesion .

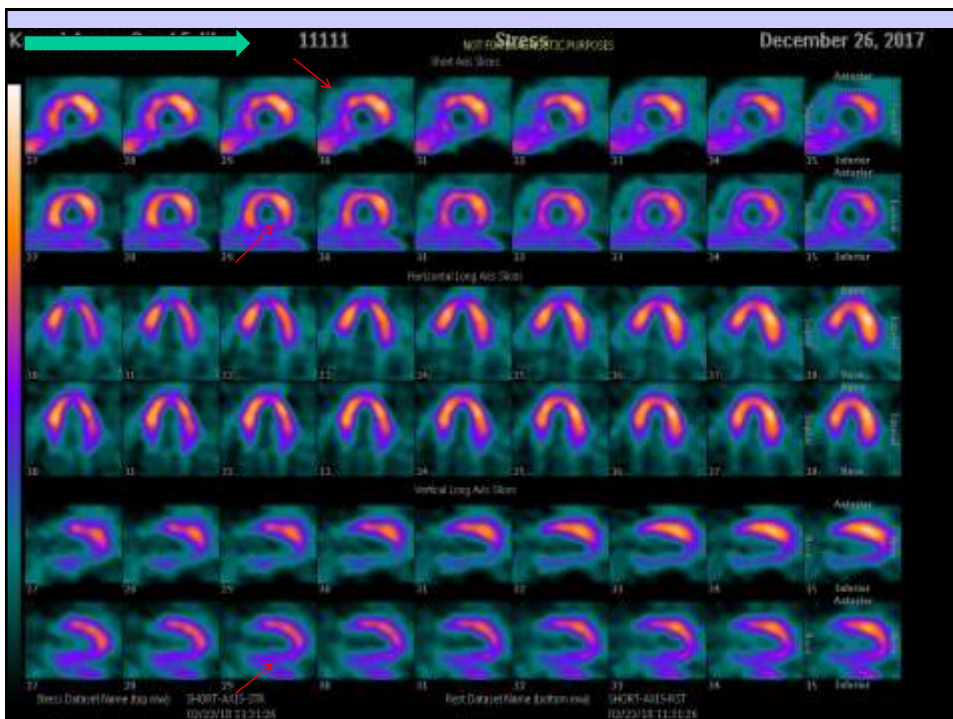
Resting ECG normal

Exercise data she exercised for 6 min reached  
95% of THR stopped due to fatigue. No chest  
pain or significant ECG changes.



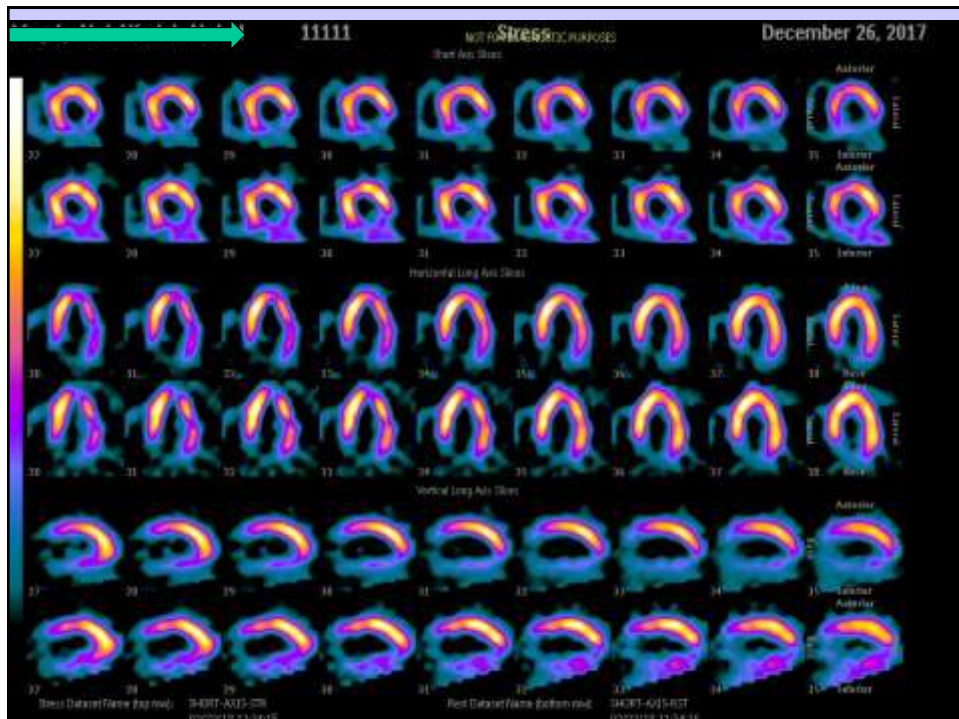
## Case 2

- A 58 year old patient , diabetic hypertensive c/o post PCI chest pain.
- He had 2 DES in the LAD,LCX 7 months ago with a borderline 40% RCA lesion.
- Resting ECG: normal
- He exercised for 4 min reaching 85% of THR .
- He had chest pain and ST segment depression .



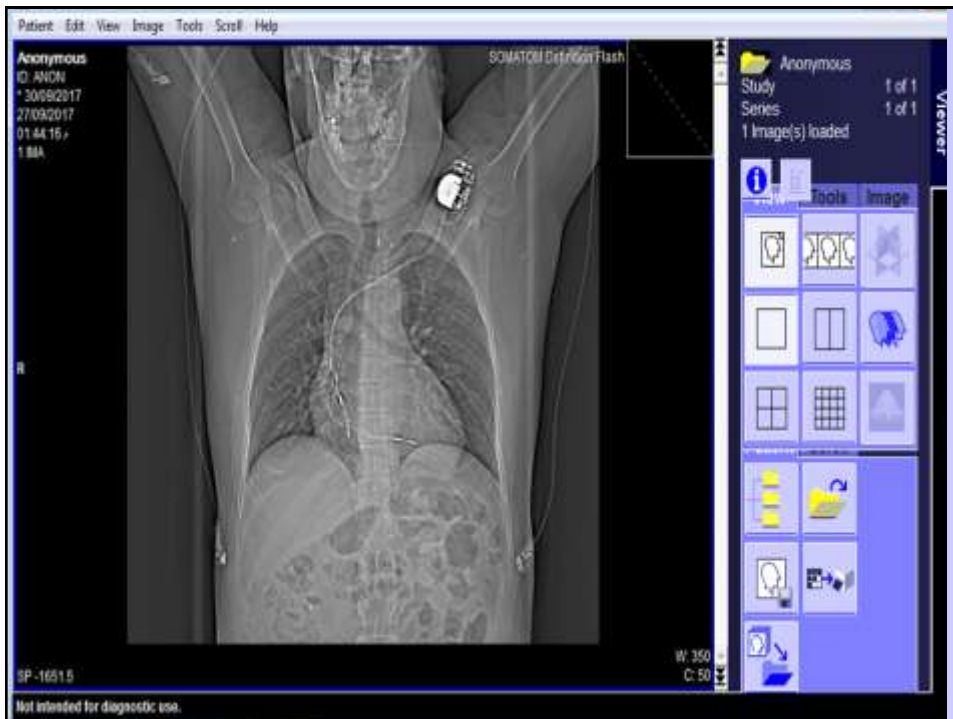## Case 3

- A 54 year old patient , smoker, c/o post MI chest pain . He had inferior STEMI and received thrombolytic therapy.
- He underwent CA that revealed 40% LAD lesion and 50% RCA lesion.
- Resting ECG: inferior Q waves.
- He exercised for 5 min(85% THR) , he had chest pain and ST segment depression.



## An interesting case

- A 45 year old hypertensive patient
- He had permanent pace maker implantation 2 years ago and is c/o exertional chest pain.
- He underwent CCTA.





## Take home message

- Angiographic severity of coronary artery stenosis has historically been the primary guide to revascularization or medical management of coronary artery disease. However, physiologic severity defined by coronary pressure and/or flow has resurged into clinical prominence as a potential, fundamental change from anatomically to physiologically guided management.
- (J Am Coll Cardiol 2013;62:1639–53)



*Thank you*