



Egyptian Society of
CARDIOLOGY

Minia University Tanta University Zagazig University

45TH
45th Annual International Congress of the
EGYPTIAN SOCIETY OF CARDIOLOGY
CardioEgypt 2018

Trans brachial intra aortic balloon counter
pulsation in a patient with acute coronary
syndrome with severely diseased peripheral
arterial diseases

Safer high risk PCI with an unusual access.

O. Shoeib*, F. Burzotta, C. Aurigemma, C. Trani
Policlinico «A. Gemelli», Catholic University of the Sacred Heart, Rome – *Tanta University, Egypt
oshouip@gmail.com

Patient History

- A male patient aged 61 years old with hypertension, peripheral arterial disease and previous multiple strokes and active HIV infection.
- Started to complain of chest pain after which he was presented in the ER.
- His ECG showed ischemic changes in the inferolateral leads and his troponin was positive.

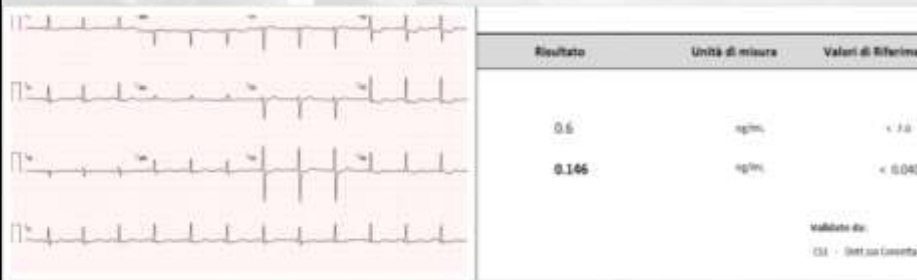Multiple strokes HIV



45th Annual International Congress of the
EGYPTIAN SOCIETY OF CARDIOLOGY
CardioEgypt 2018

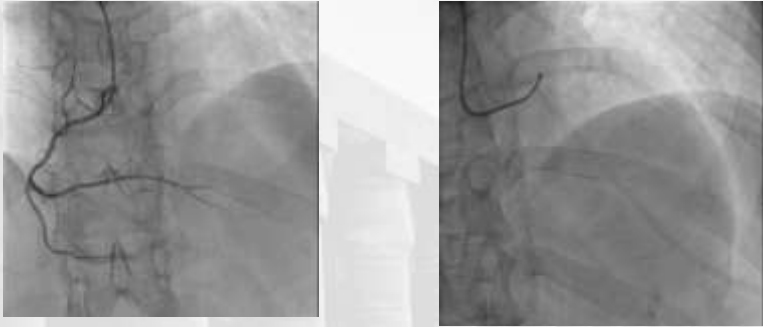
www.cardioegypt.com

Patient In ER




Workup

- The patient was transferred to CCU, Echocardiography showed ischemic heart disease with hypokinesia in the antero-lateral wall (EF 51%).
- Coronary angiography was done:
 - Significant lesion in the left main coronary artery at the trifurcation with LAD, CX and early marginal branch (medina 1.1.1.1).
 - Significant lesion in the mid segment LAD at the bifurcation with diagonal branch (Medina 1.1.1).



First coronarography



45th Annual International Congress of the
EGYPTIAN SOCIETY OF CARDIOLOGY
CardioEgypt 2018

www.cardioegypt.com



45th Annual International Congress of the
EGYPTIAN SOCIETY OF CARDIOLOGY
CardioEgypt 2018

www.cardioegypt.com

First heart team discussion

- With such complex anatomy in such risky patient so the case went for discussion in our morning heart team.
- The patient was refused by surgeons due to his co morbidities.
- The PCI decision was made.

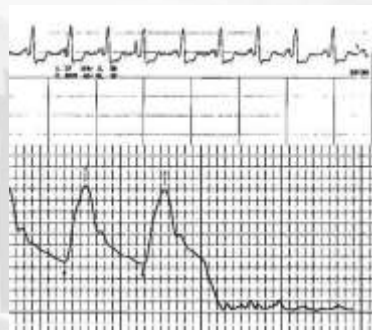


45th Annual International Congress of the
EGYPTIAN SOCIETY OF CARDIOLOGY
CardioEgypt 2018

www.cardioegypt.com

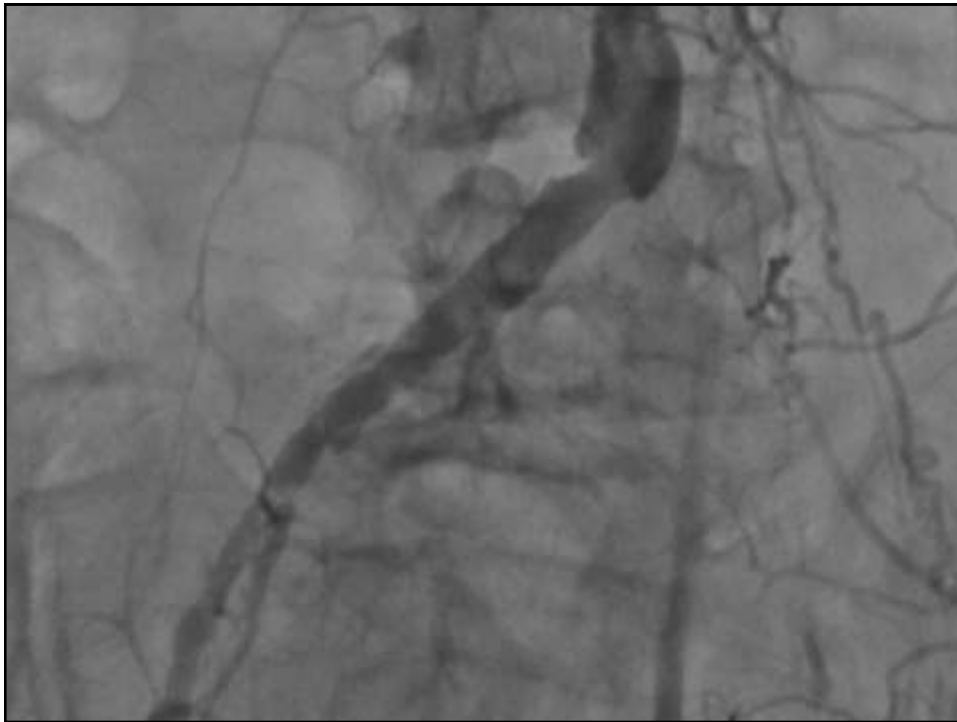
At Cath. LAB

- PCI was initiated at the next day, during which the patient experienced severe chest pain and severe hypotension with just the guiding catheter cannulation in the LM
- The operator decided to continue the PCI with transfemoral intra-aortic balloon counter pulsation support.



45th Annual International Congress of the
EGYPTIAN SOCIETY OF CARDIOLOGY
CardioEgypt 2018

www.cardioegypt.com



A red, cartoonish question mark character with yellow eyes and sharp teeth, set against a background of a hospital room. The character is positioned in the center of a white square, which is overlaid on a grayscale image of a hospital room with a bed and a window. The character has a menacing expression, with yellow eyes and sharp, black teeth. The background shows a hospital room with a bed, a window, and some furniture, all in grayscale.

Heart team again

Another discussion at the heart team meeting after the patient had a CT angiogram for the aortic arch and the main vessel and the decision was made for PCI with trans-brachial IABP support.



45th Annual International Congress of the
EGYPTIAN SOCIETY OF CARDIOLOGY
CardioEgypt 2018

www.cardioegypt.com

Technical procedures

- An 8 Fr sheath was inserted in the left brachial artery through which the IABP (40 cm balloon) was inserted.
- Another 6 Fr sheath was inserted at the right radial approach through which an aortography was made to control the balloon position and insure the patency of the left subclavian artery.



45th Annual International Congress of the
EGYPTIAN SOCIETY OF CARDIOLOGY
CardioEgypt 2018

www.cardioegypt.com

Technical procedures

- Then the PCI was continued by treating first the mid-segment LAD lesion by provisional stenting in the LAD with final kissing balloon with the diagonal branch.
- The LM trifurcation lesion was addressed by predilation in both side branches (LAD and CX) then a provisional stent LM-Cx followed by final kissing balloon and dilatation at the marginal branch ostium with a very good final angiographic result.



www.cardioegypt.com

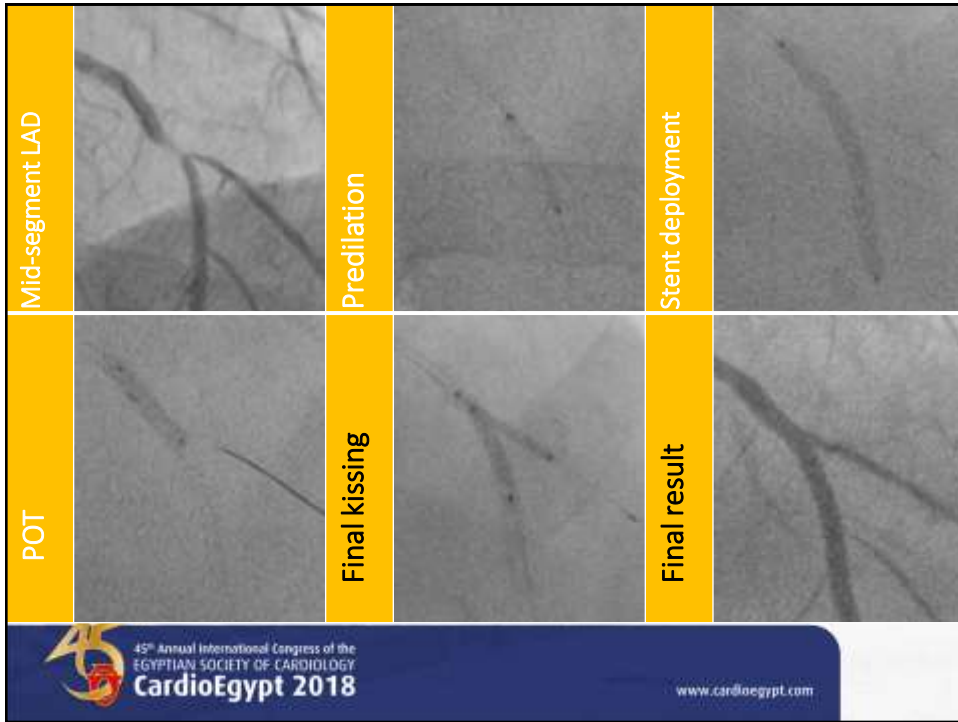
Egyptian Society of CARDIOLOGY

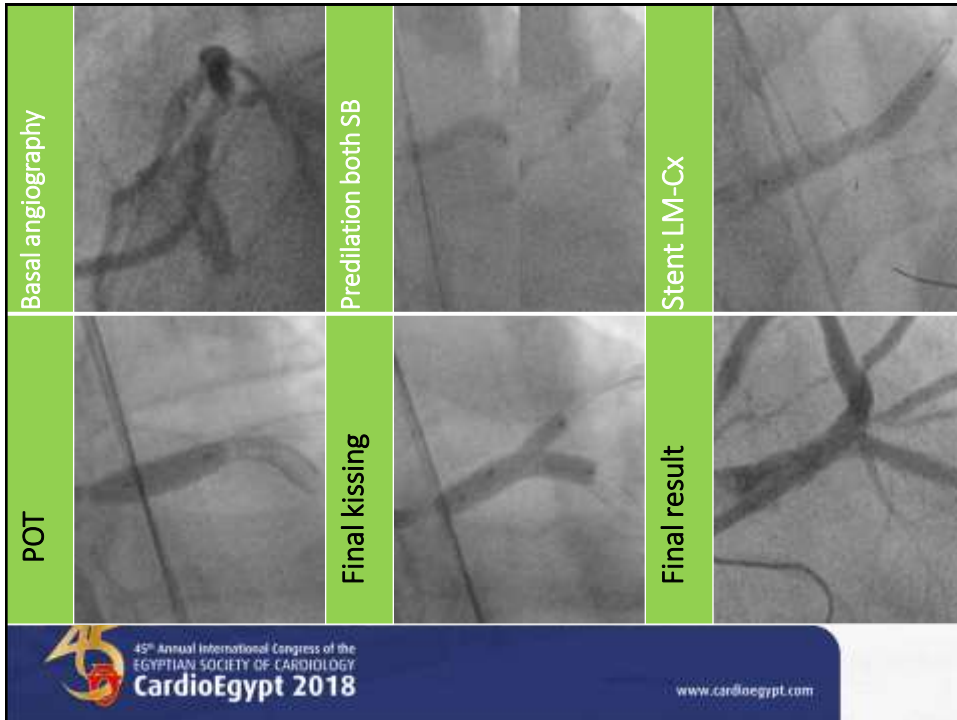
Minia University Tanta University Dapang University

45TH Annual International Congress of the
EGYPTIAN SOCIETY OF CARDIOLOGY
CardioEgypt 2018

Mid segment LAD PCI

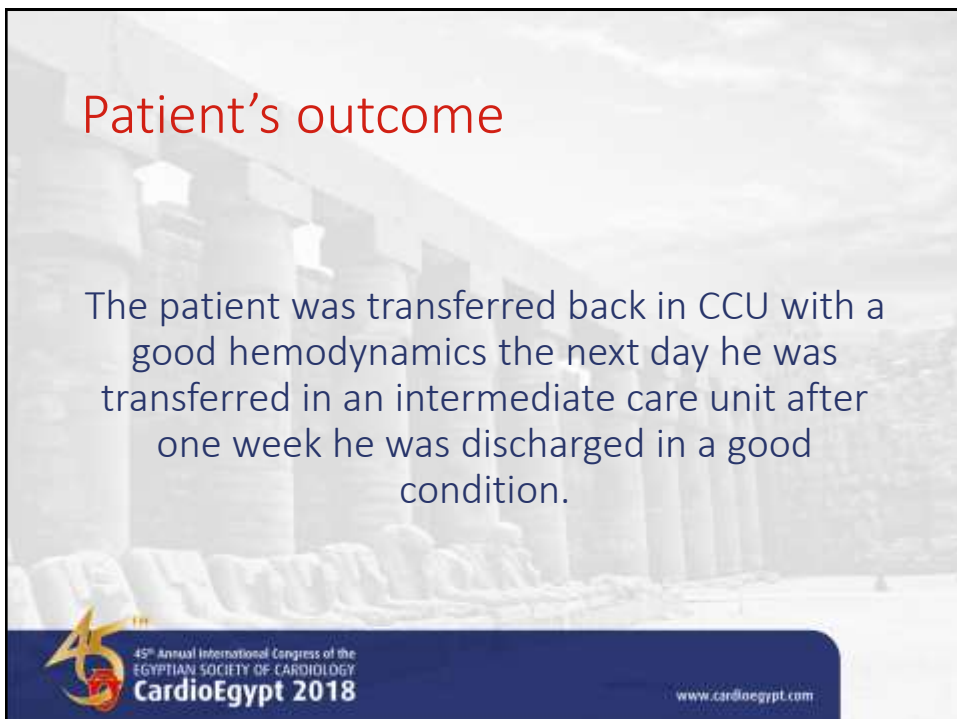
Bifurcation with diagonal branch (Medina 1.1.1)





Patient's outcome

The patient was transferred back in CCU with a good hemodynamics the next day he was transferred in an intermediate care unit after one week he was discharged in a good condition.



Pearls and pitfalls

- Left brachial is safer (avoid all cerebral vessels except for left cerebral artery)
- The balloon sensor in the up side down position is not accurate the balloon is synchronized based on ECG tracking only, or connect to another invasive monitoring near the aortic valve.



www.cardioegypt.com

Pearls and pitfalls

- After balloon insertion make sure it is away from the subclavian ostium and inject contrast to check its patency.
- Keep monitoring of the arm perfusion with a pulse oximeter especially if you intended to leave the IABP for a while.



www.cardioegypt.com

Conclusion

- Access from the femoral arteries for IABP insertion may not be feasible in a substantial number of patients with severe peripheral vascular disease.
- A relative lower sheath size and better profile for the IABP give it advantages over other types of LV support to be used through other vascular accesses which allow hemodynamic support in high risk PCI in such group of patients.



www.cardioegypt.com