



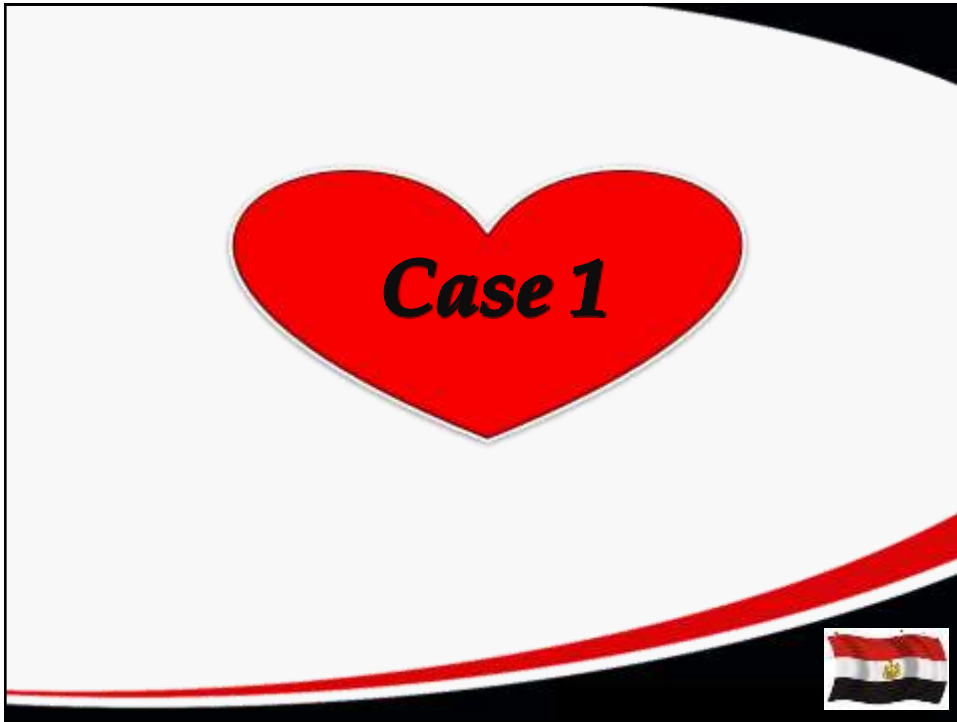Meet with Expert Cases

Alia Abd El-Fattah

Professor of Critical Care Medicine,
Cairo University

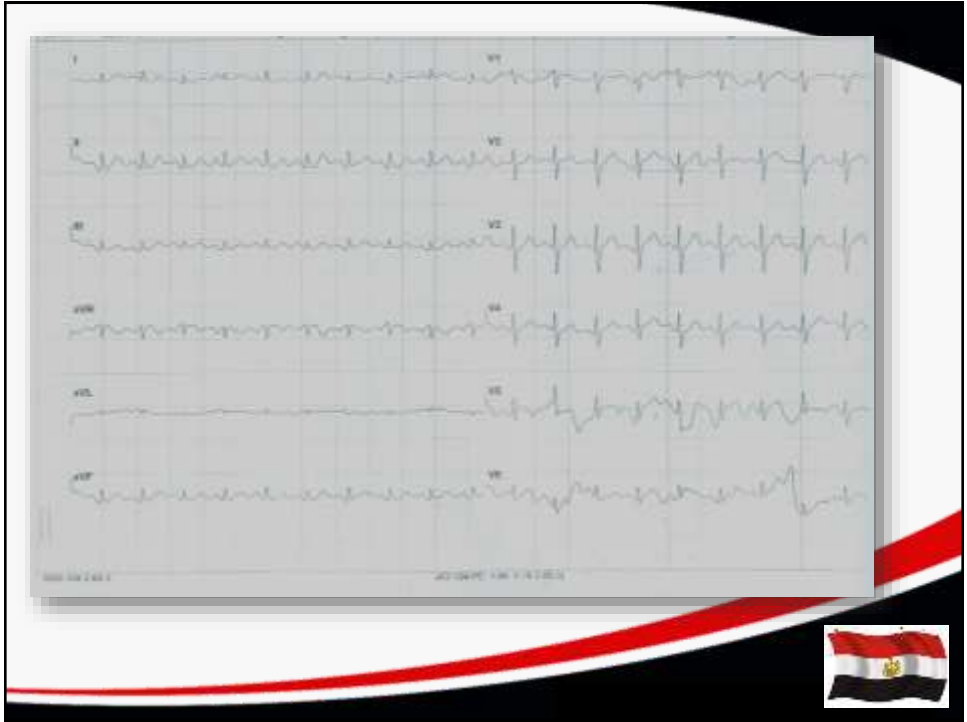
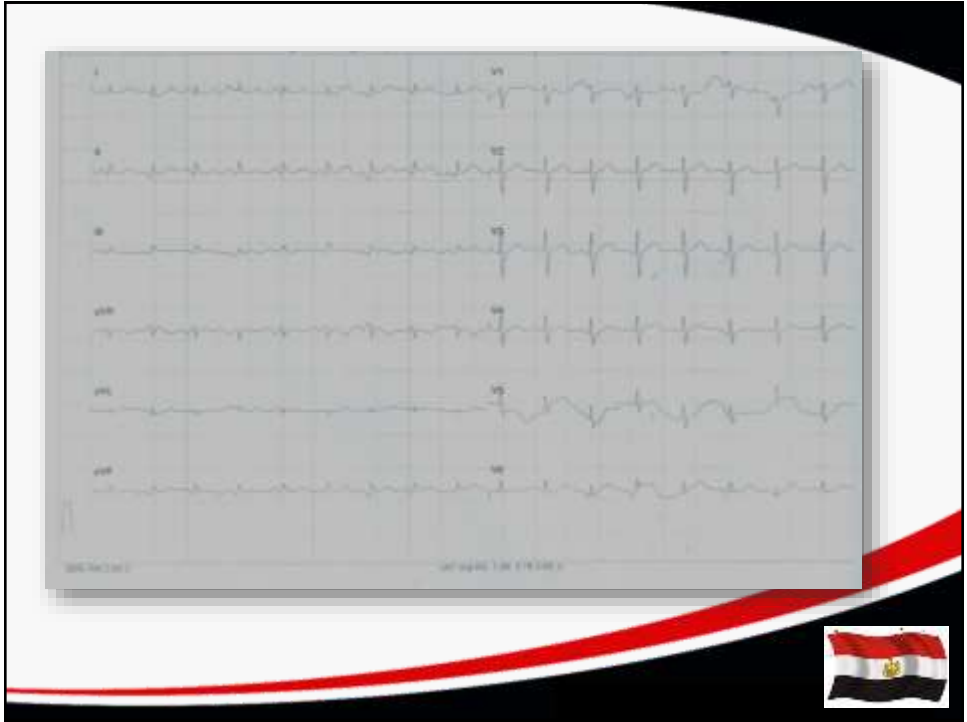
2018

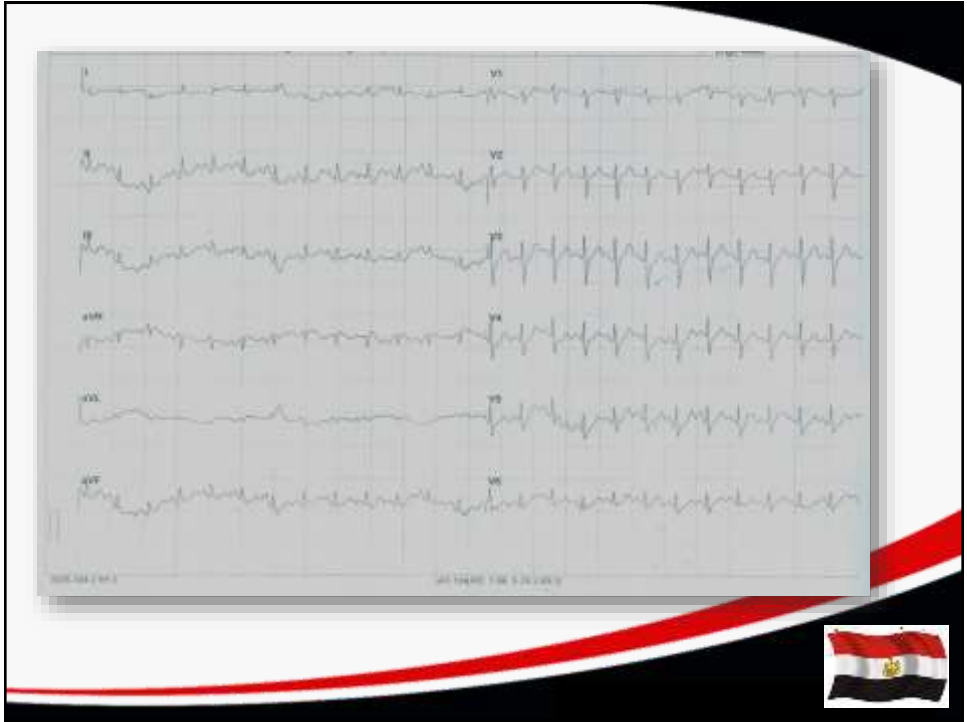
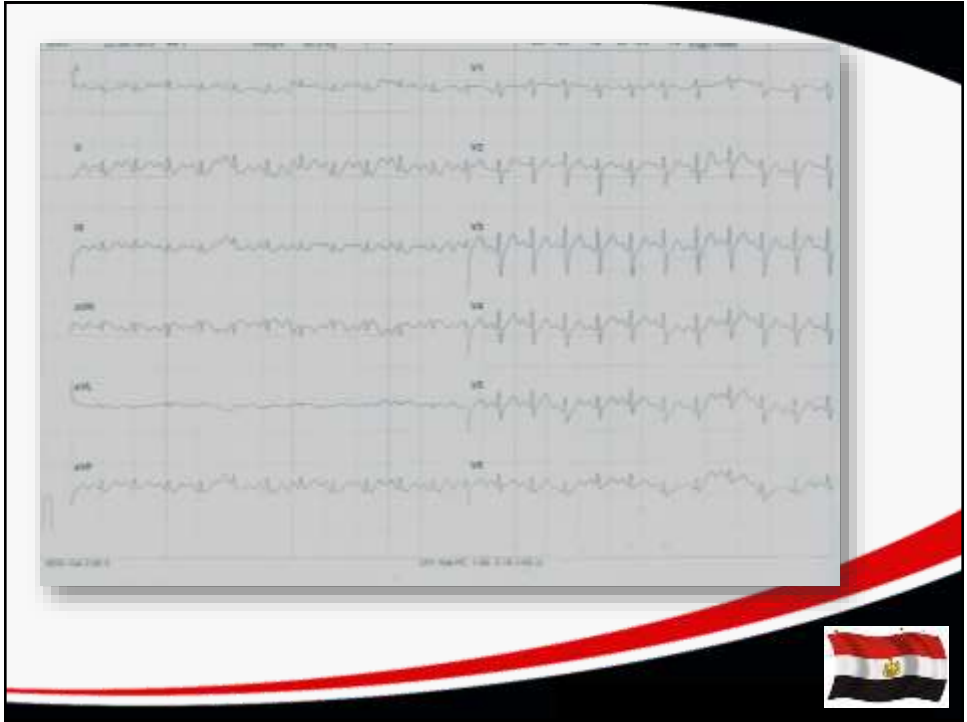


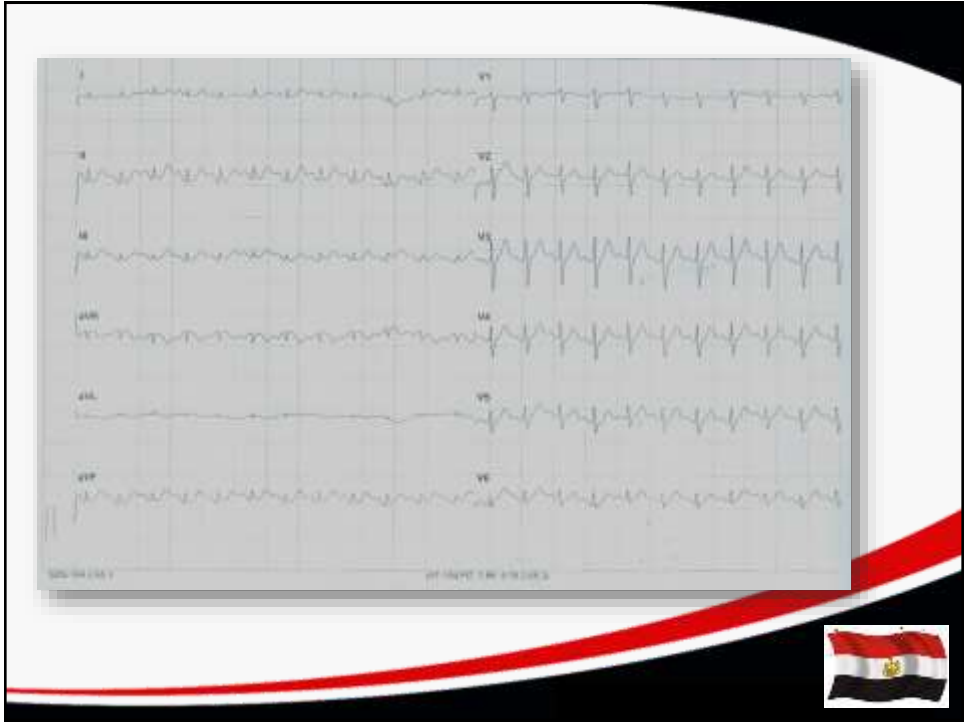
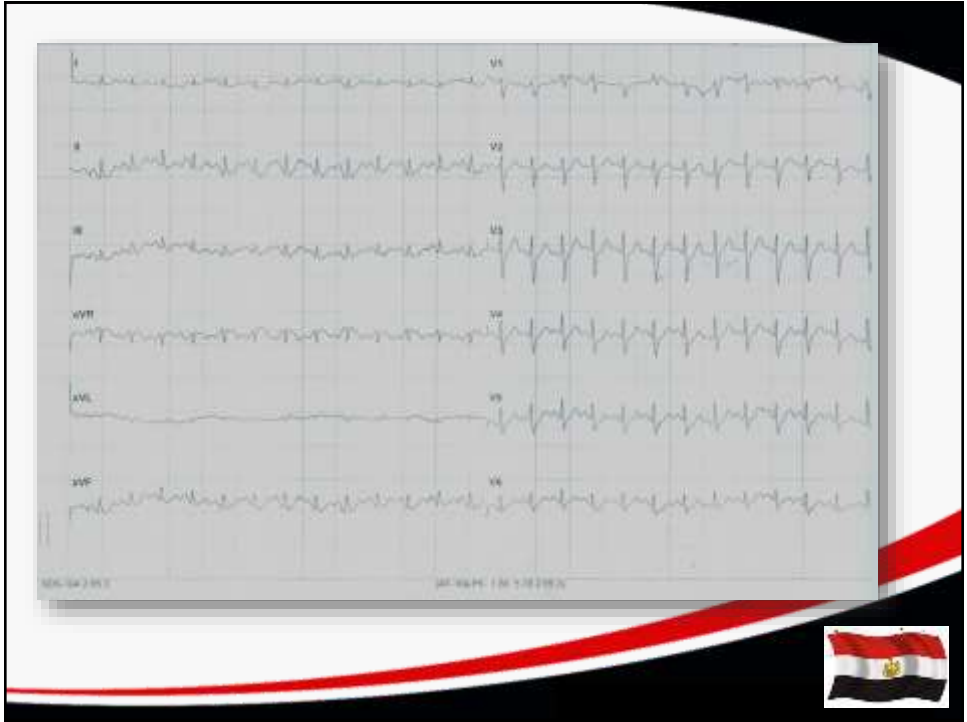


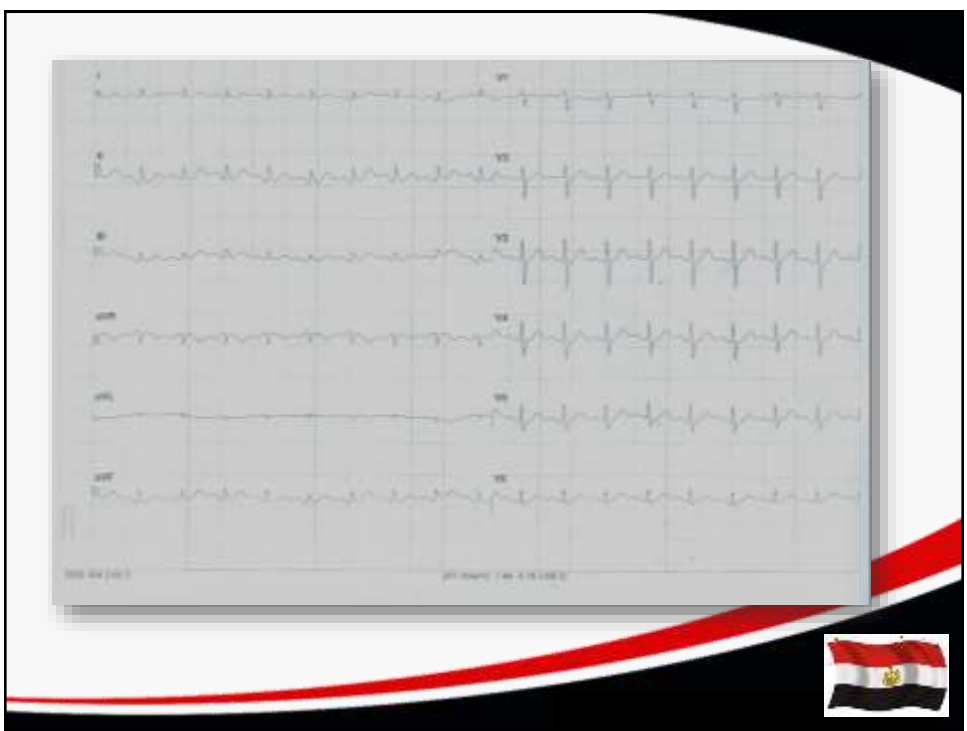
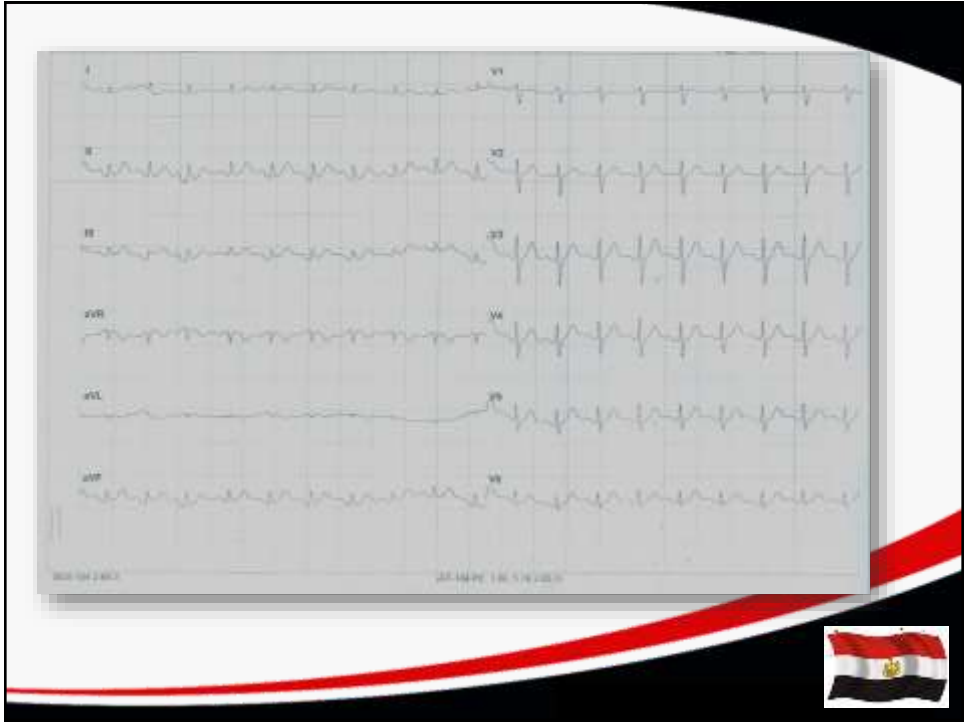
- Male patient
- 44 years old
- C/O: Chest pain
- Risk factors for CAD: Hypertensive, Ex. Smoker
- Protocol of MPI:
 - Exercise stress
 - Gated SPECT
- Resting HR: 95 b/min Resting BP: 130/80 mmHg
- Resting ECG: Normal Exercise protocol: Bruce
- Peak HR: 164 bpm %MPHR achieved: 93
- Total exercise time: 7 min 25 sec Max. BP: 200/110 mmHg
- The test was terminated because of: reaching MPHR
- ECG showed: No dynamic changes

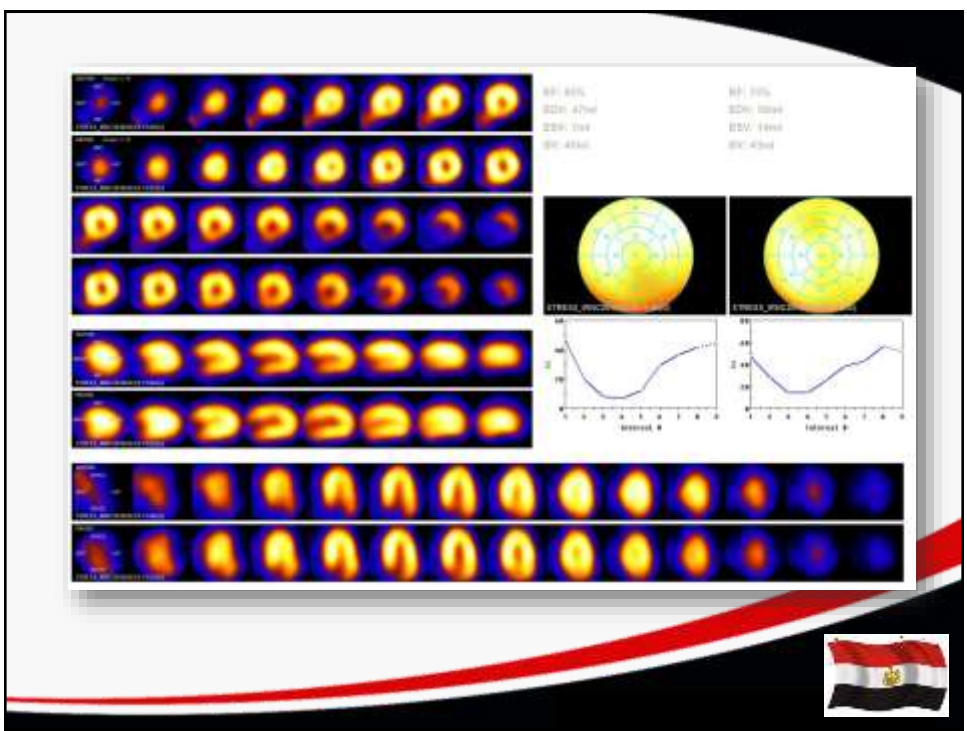
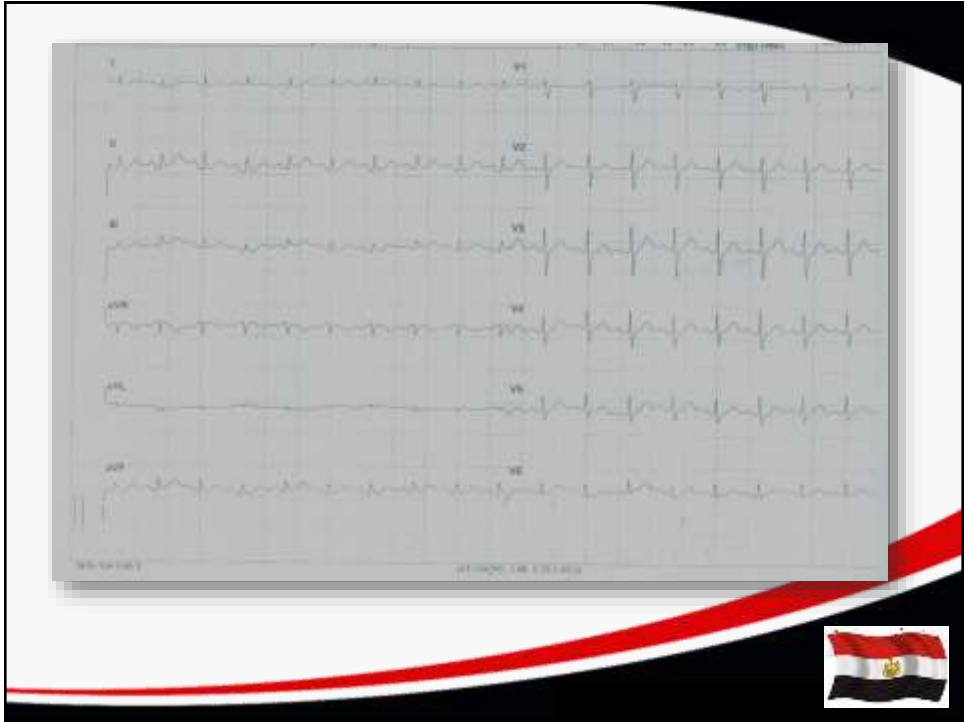


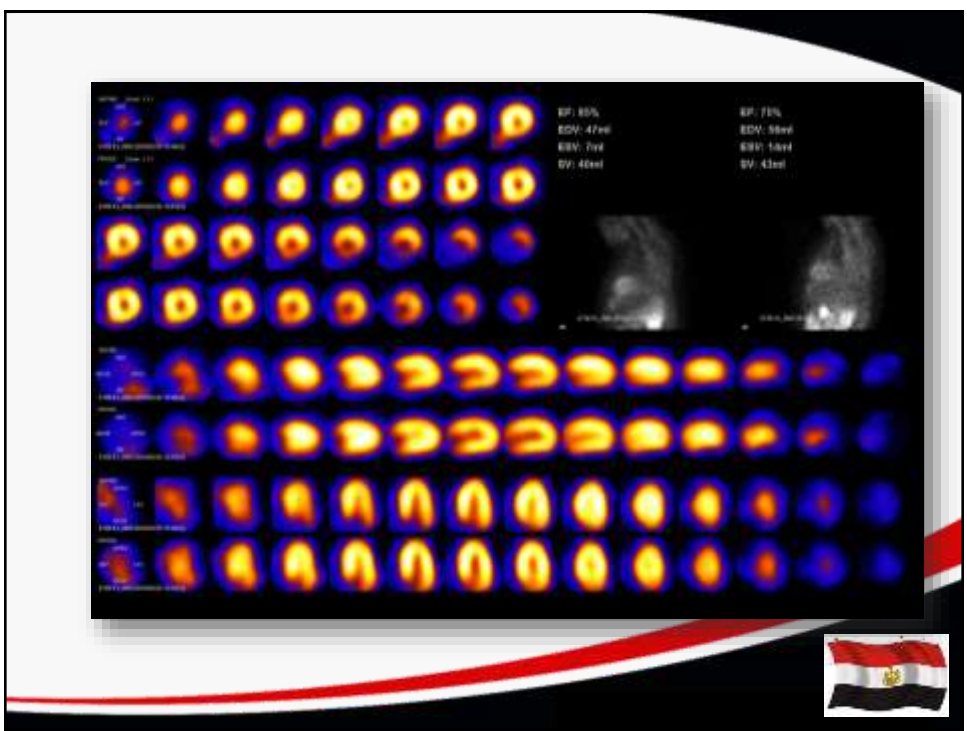
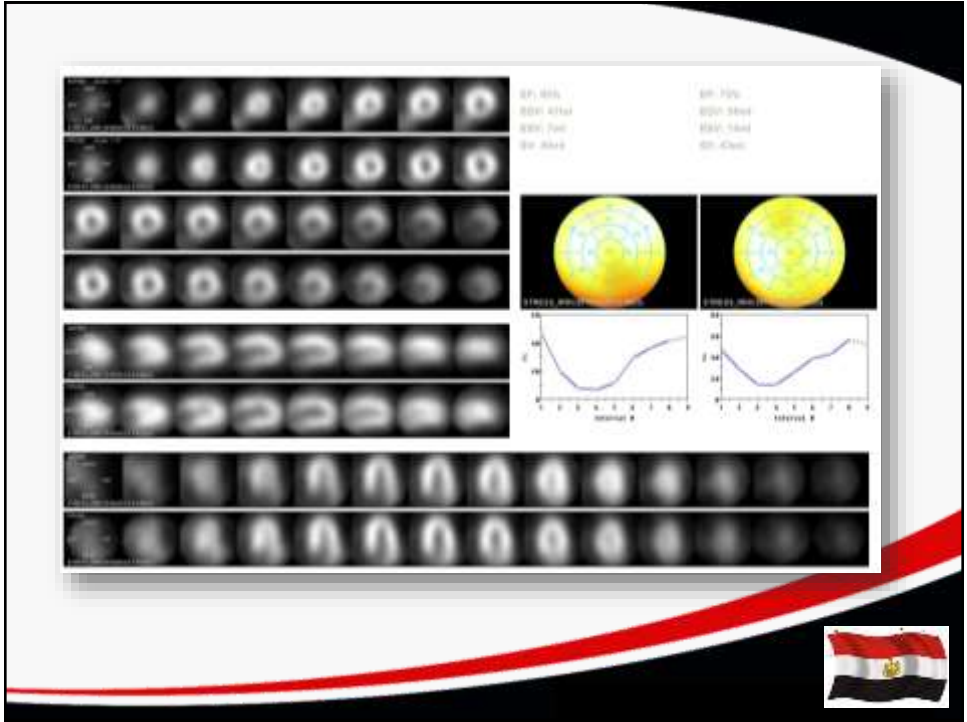


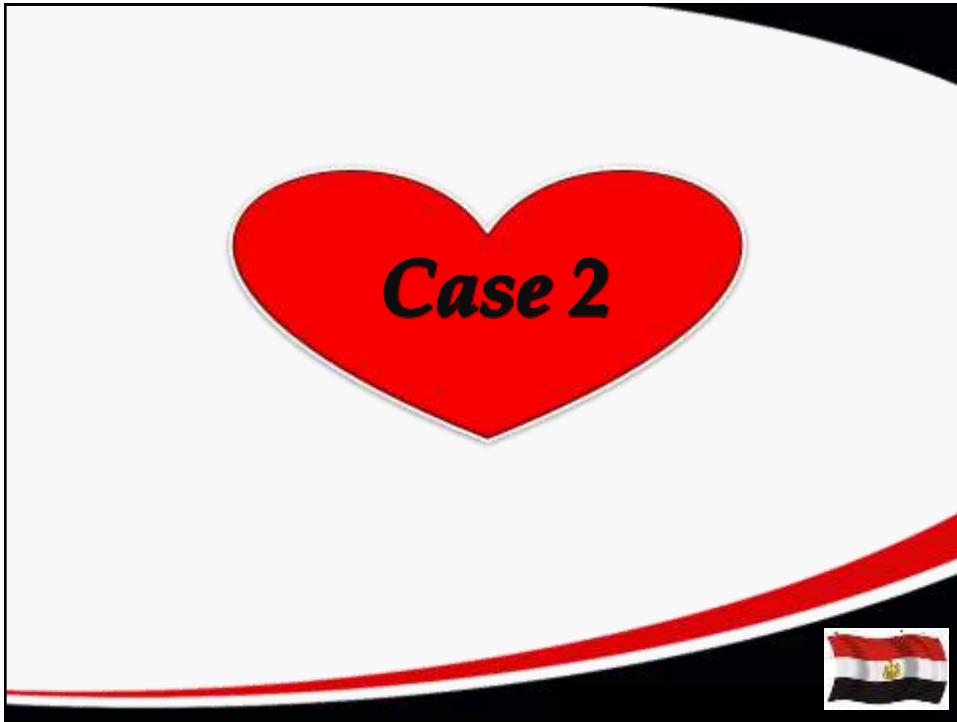



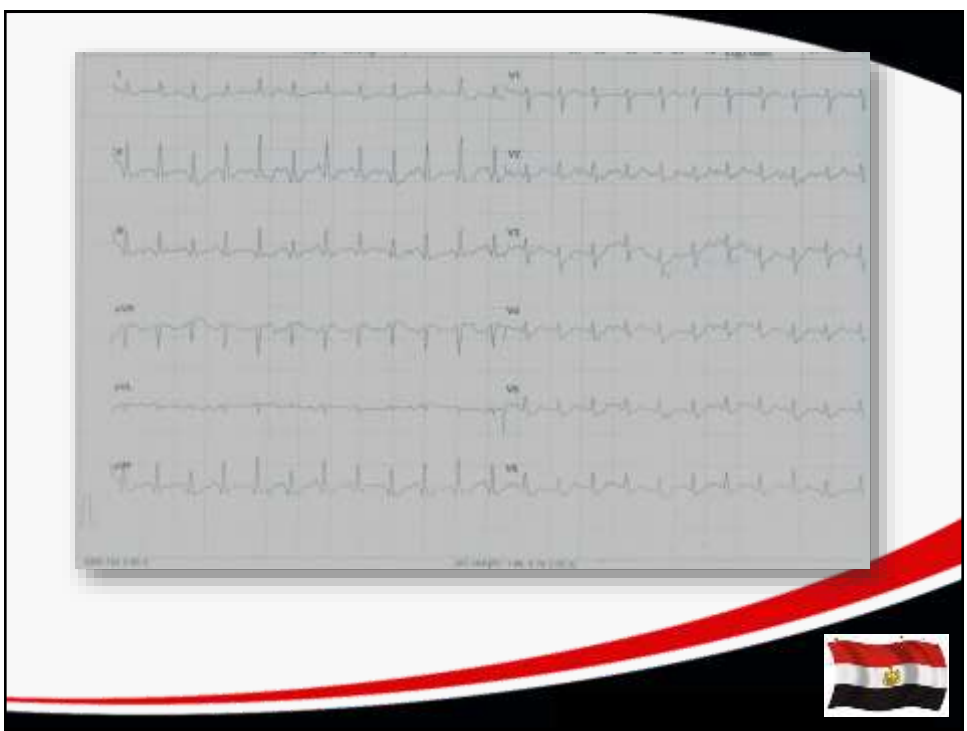
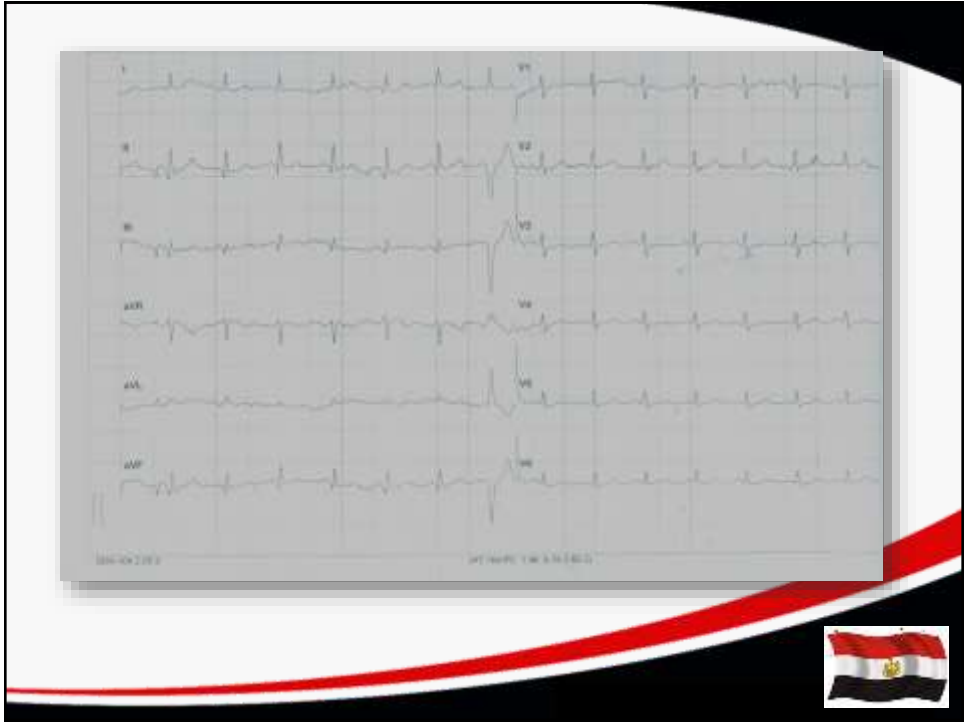


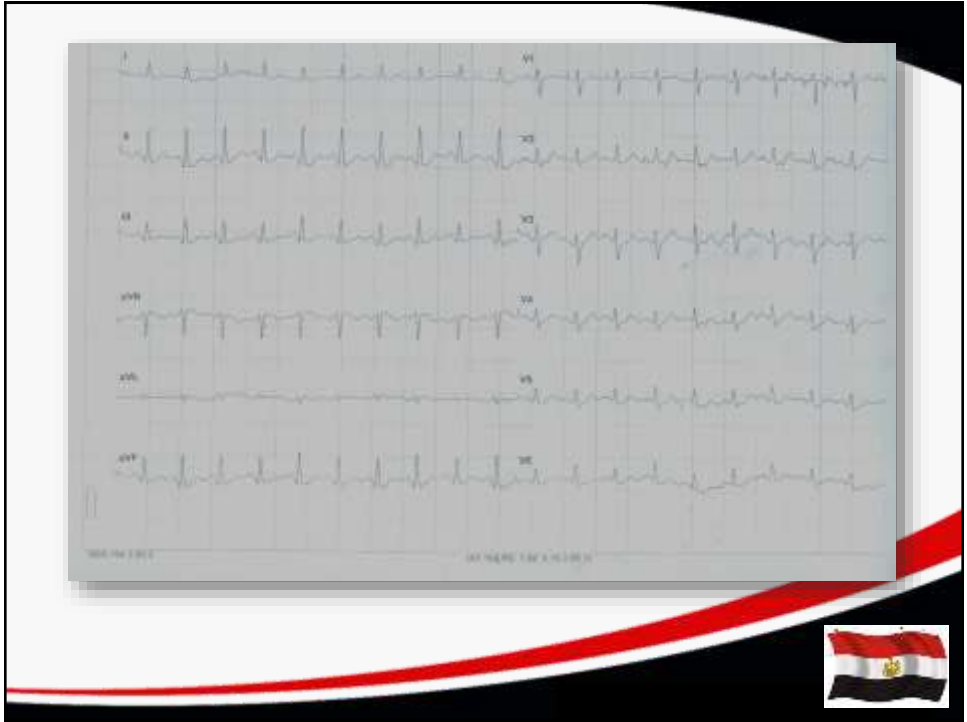
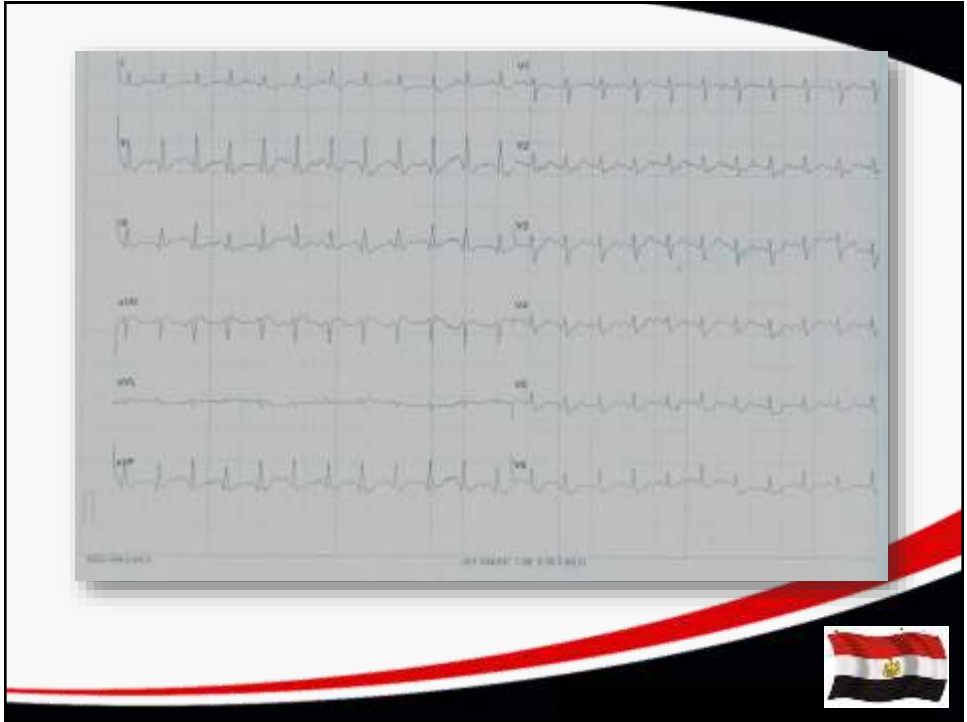


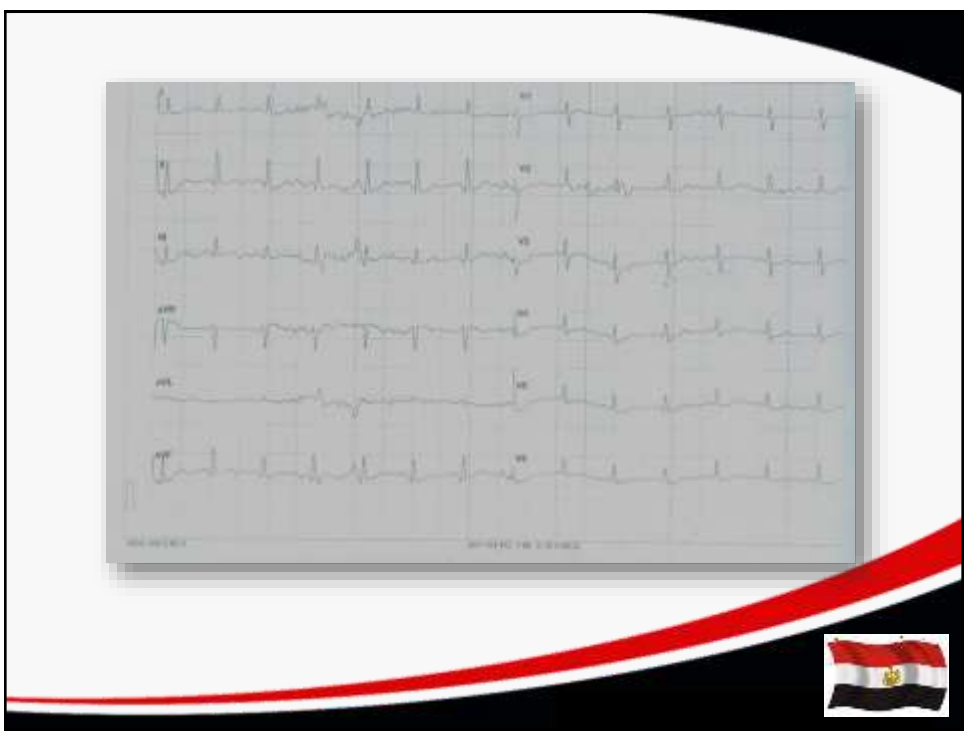
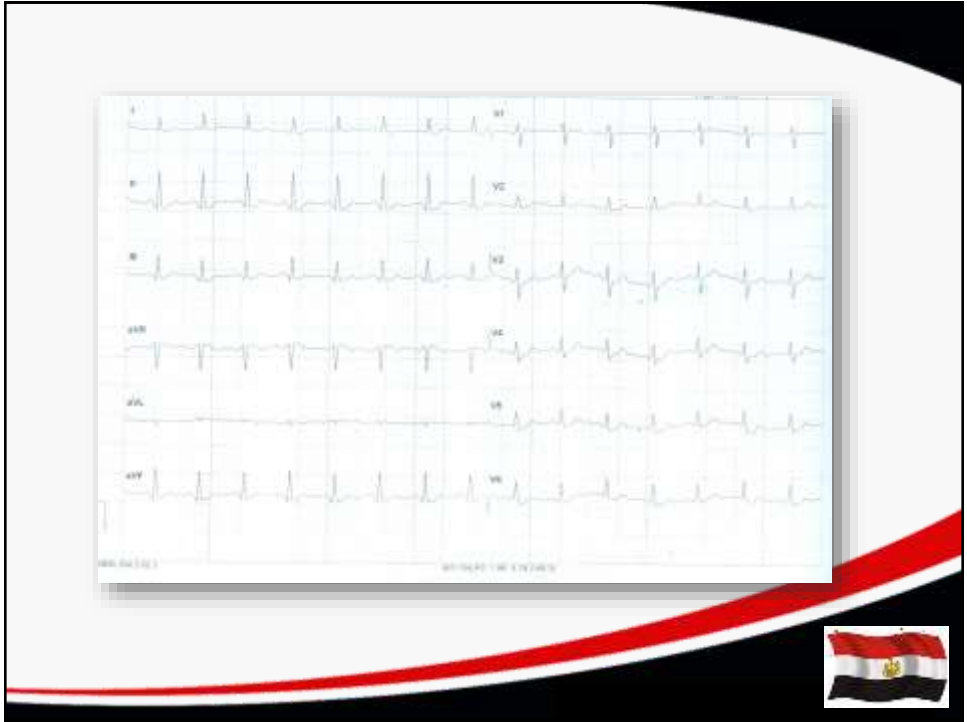


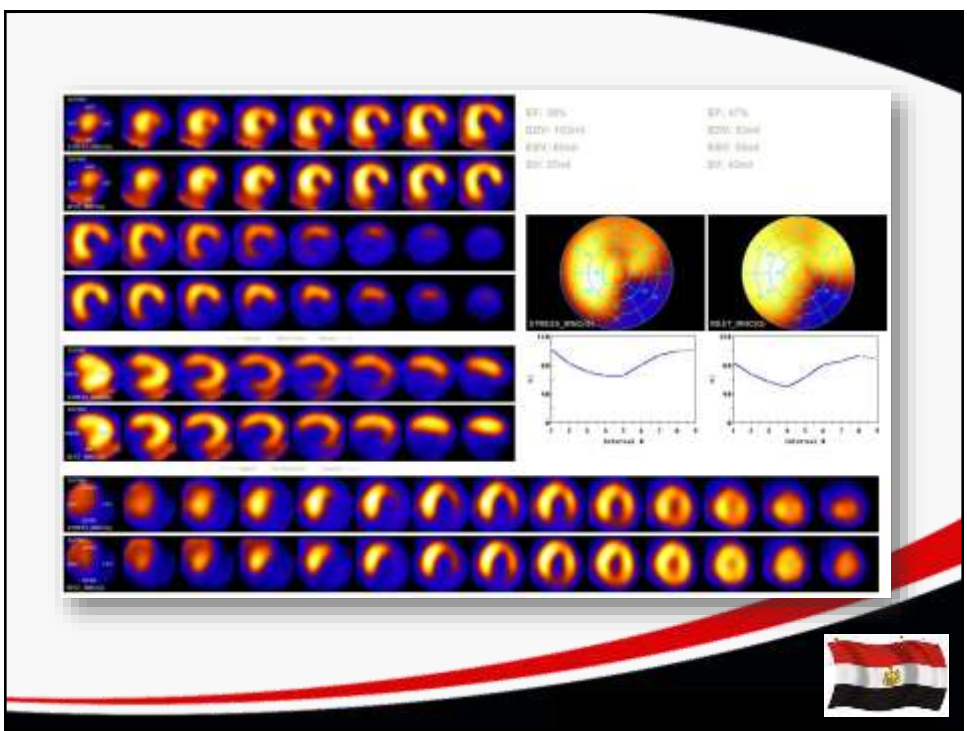
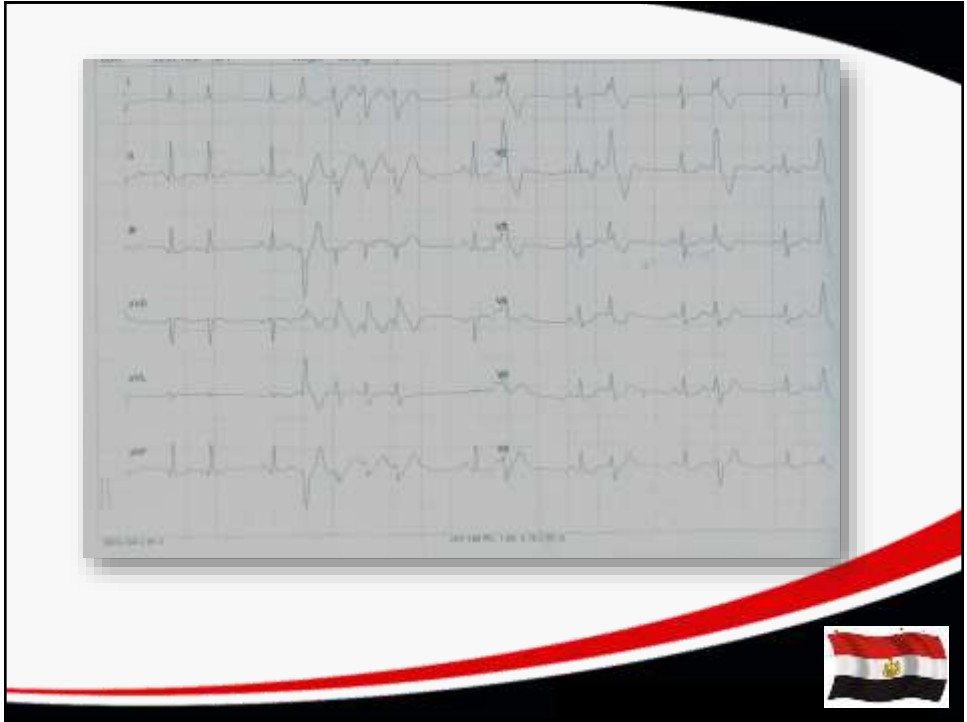


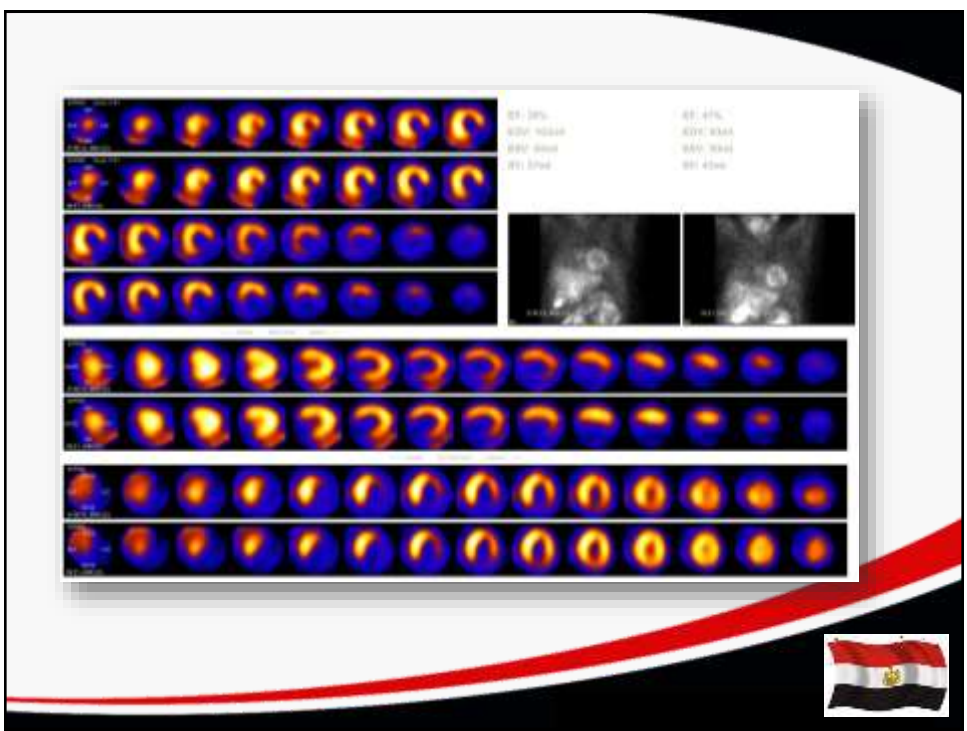
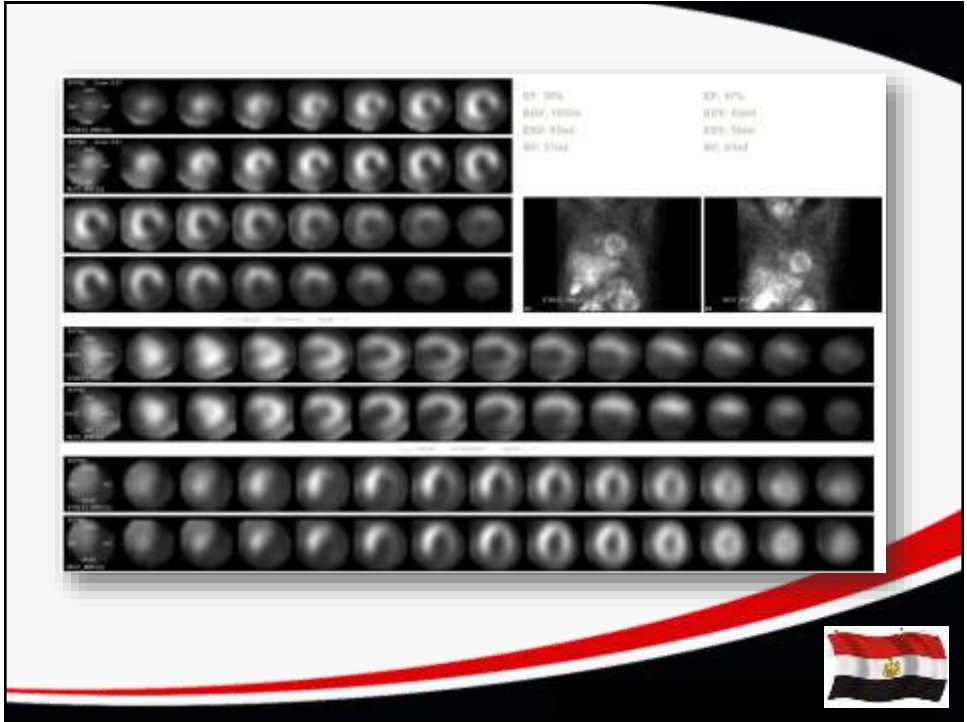- Female patient
- 59 years old
- She had ACS one year ago, CA: total LCX, insignificant LAD
- PCI to LCX was done
- C/O: Chest pain, post PCI evaluation
- Protocol of MPI:
 - Exercise stress
 - Gated SPECT
- Resting HR: 94 b/min Resting BP: 140/80 mmHg
- Resting ECG: Normal, infrequent PVCs Exercise protocol: Bruce
- Peak HR: 142 bpm %MPHR achieved: 89
- Total exercise time: 2 min 42 sec Max. BP: 180/100
- The test was terminated because of SOB
- ECG showed: runs of non sustained VT

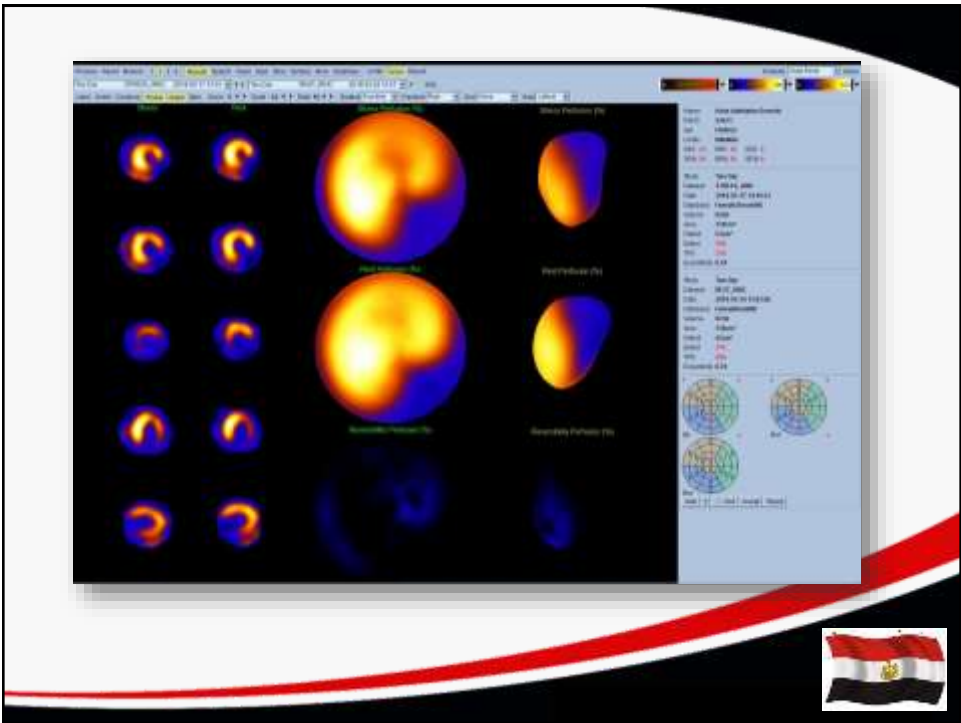
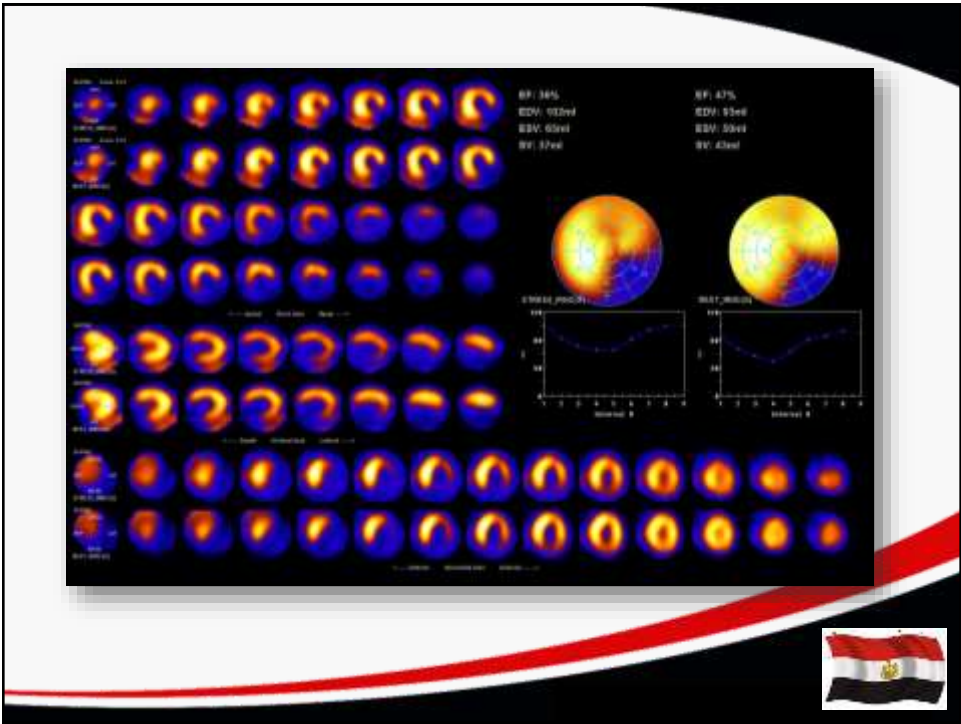


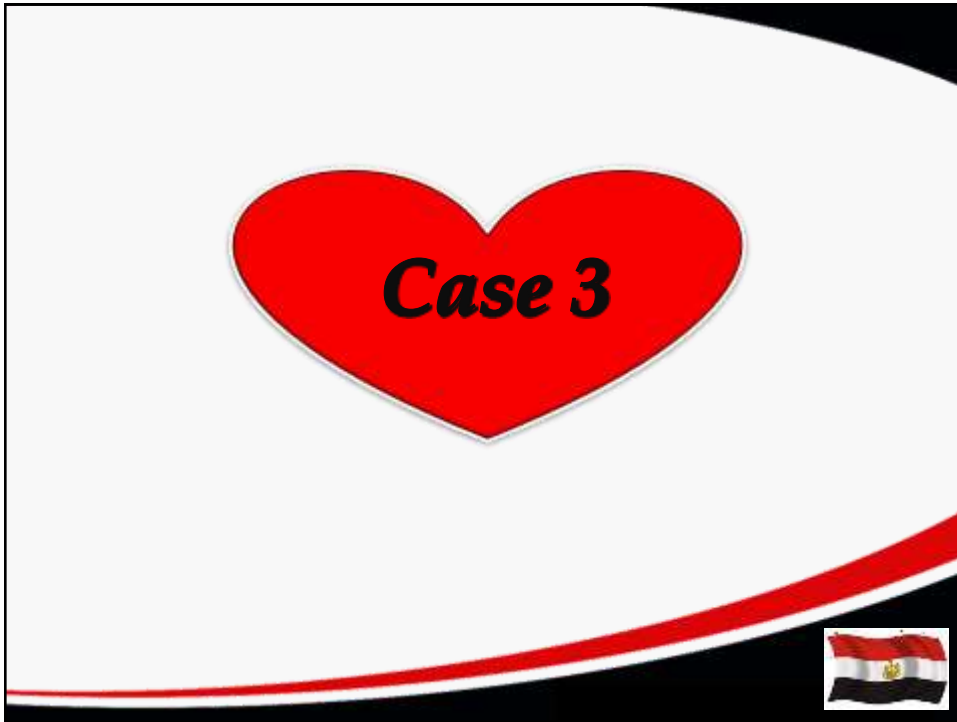











- Male patient
- 60 years old
- C/O: Chest pain post anterior MI
- Protocol of MPI:
 - Exercise stress
 - Gated SPECT
- Resting HR: 82b/min Resting BP: 140/80 mmHg
- Resting ECG: Normal Exercise protocol: Bruce
- Peak HR: 152bpm %MPHR achieved: 91
- Total exercise time: 4 min 42 sec Max. BP: 160/90
- The test was terminated because of chest pain

