

*Challenging diagnosis of cardiac  
mass*

*BY*

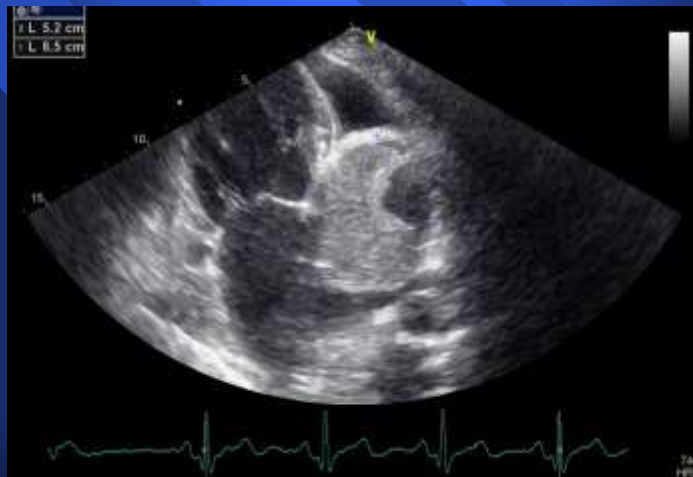*Dr. Mahmoud Kamel*

*Ass. Professor of cardiology  
Menofia university*

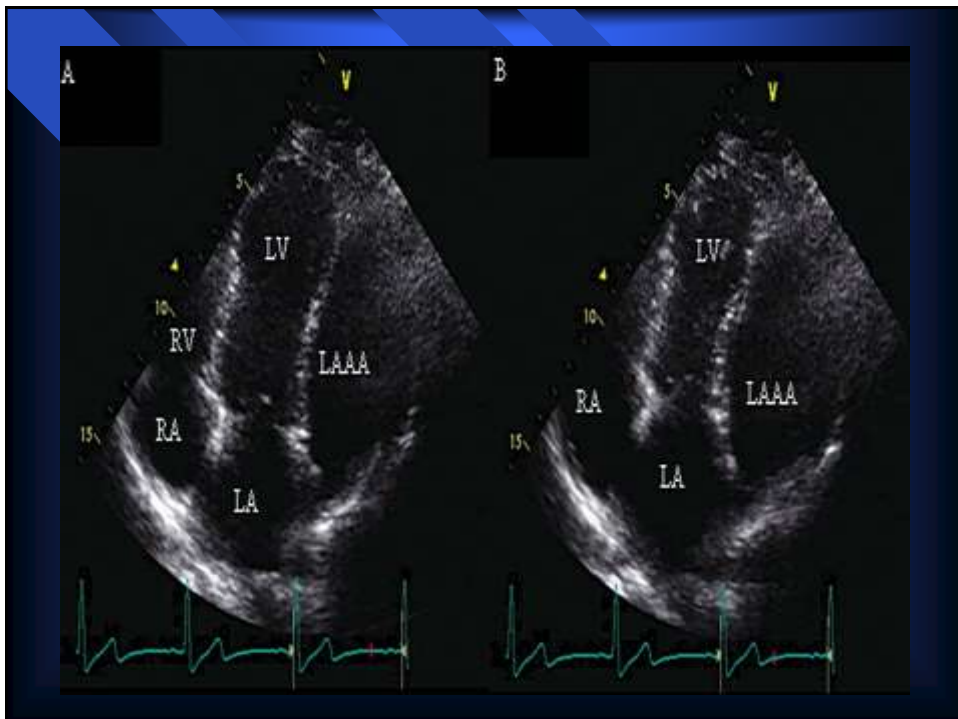
- 55 y old male patient known to be hypertensive , smoker, not diabetic came for routine echocardiographic examination before urological operation ( non obstructive kidney stone).
- History of mild dyspnea on exertion since 2y.
- No history of limiting chest pain.

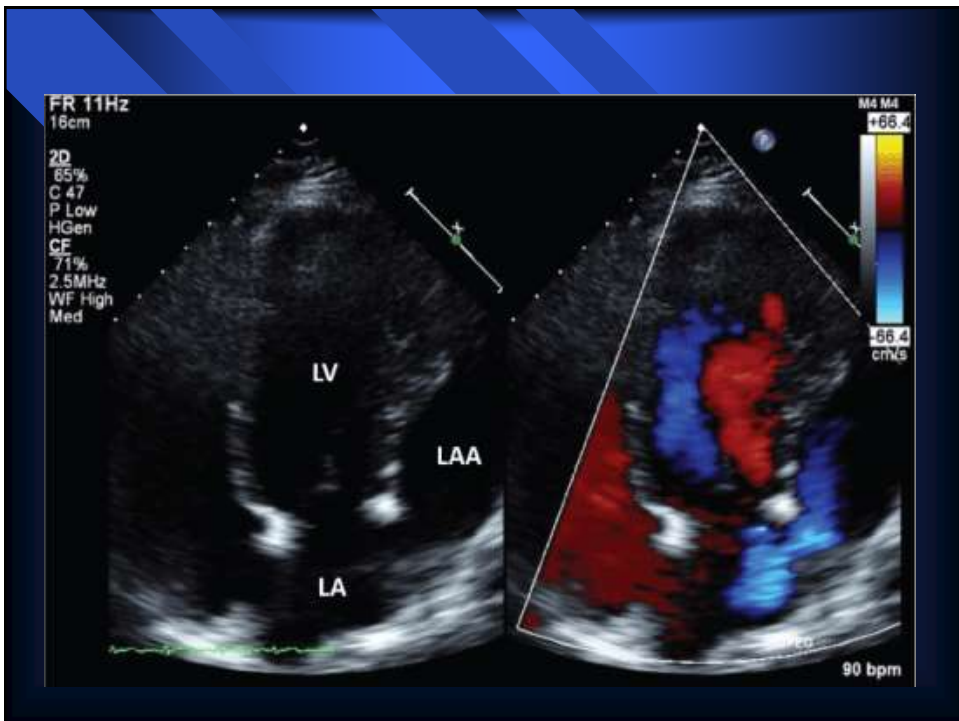
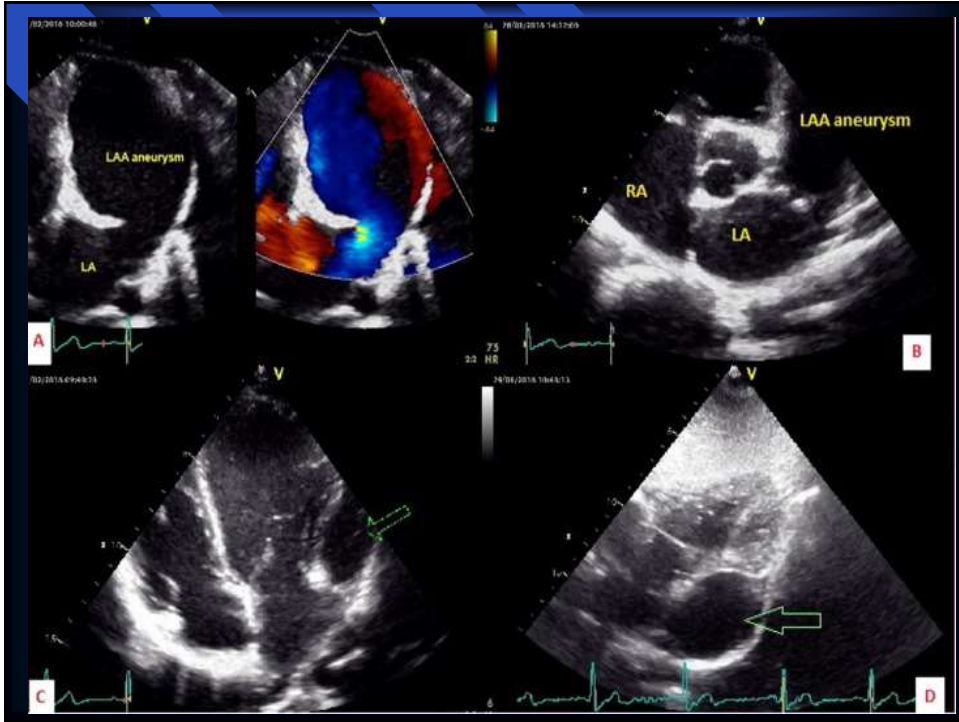
- Clinical examination was normal with controlled blood pressure on ACE inhibitor (zestril 20mg).
- ECG was done and demonstrate sinus rhythm with only LVH criteria.

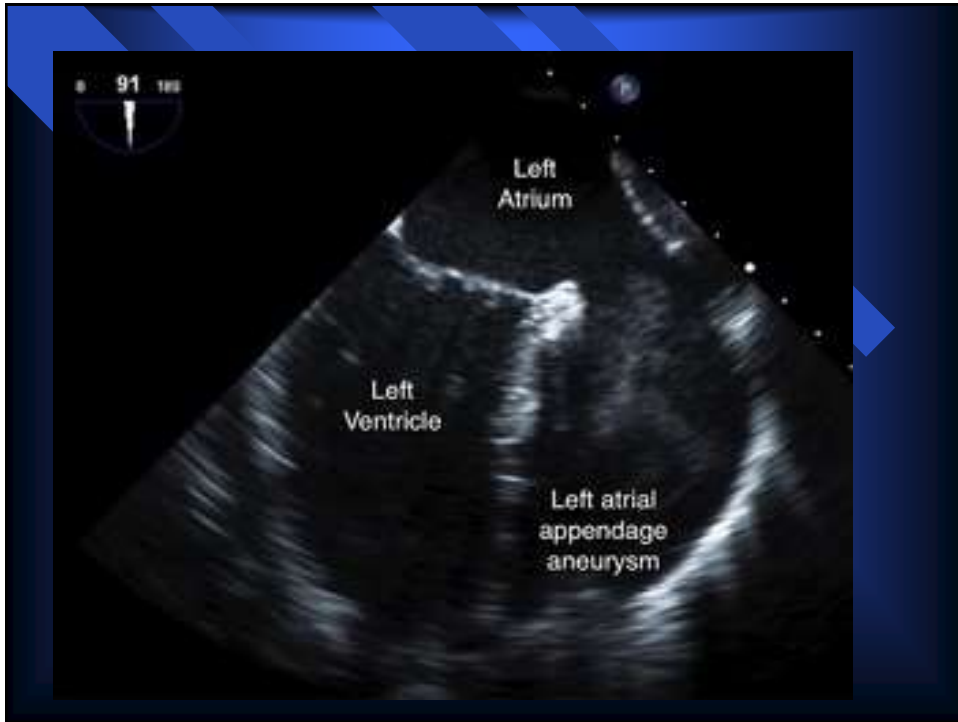# Echocardiography



- So what are the possibilities:
- Tumor
- Pericardial cyst.
- LV pseudo-aneurysm.
- LAA aneurysm.
- Coronary artery aneurysm.



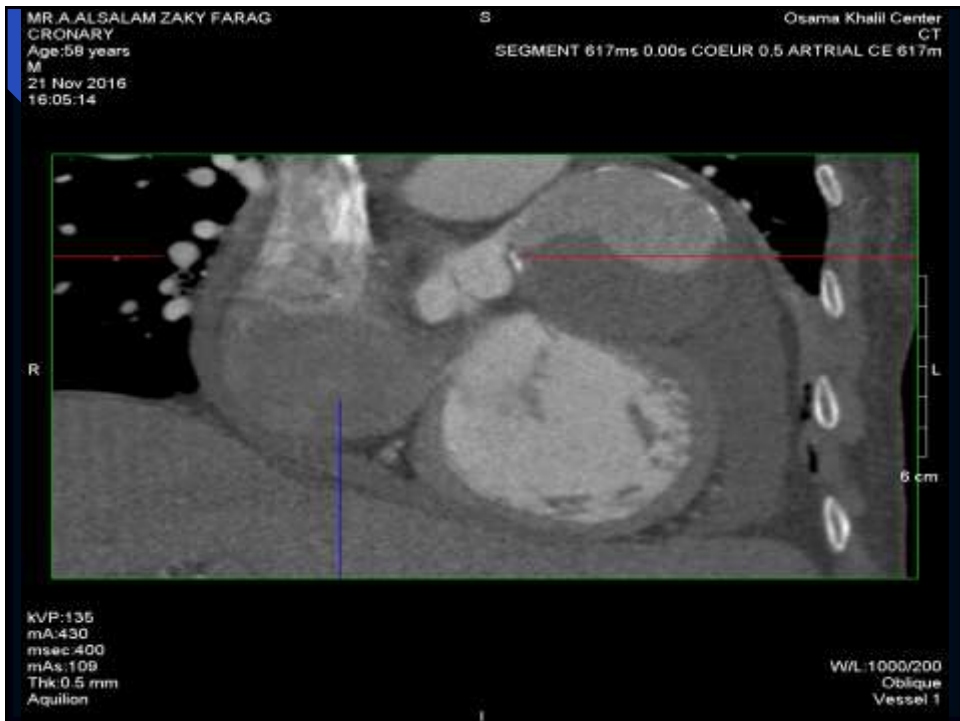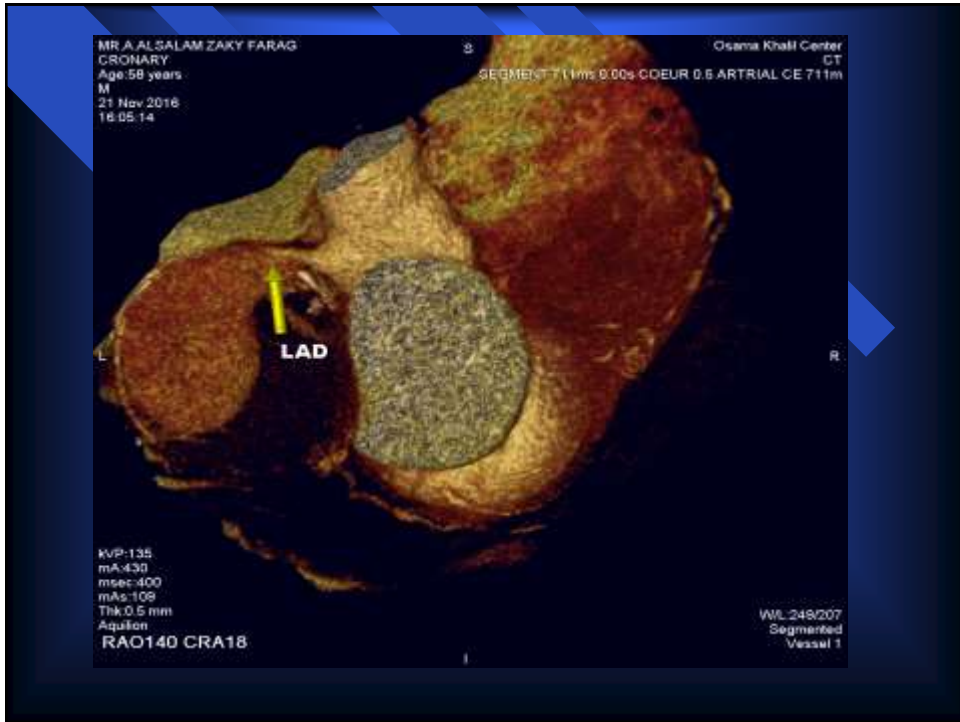




- So what are the possibilities:
- Tumor
- Pericardial cyst.
- LV pseudo-aneurysm.
- LAA aneurysm.
- Coronary artery aneurysm.

- C T chest with contrast was done with normal lung finding, no mass, no Lymph nodes, no tumors.
- Abnormal cardiac shadow.

- Multi-slices coronary angiography





## ■ Coronary angiography

## Coronary Artery Aneurysm (AAA)

- Coronary artery aneurysms (CAAs) are uncommon and describe a localized dilatation of a coronary artery segment more than 1.5-fold the normal size of adjacent normal segments.
- The overall incidence of CAAs ranges from 0.3 to 5.3%.
- The incidence of giant CAAs is as low as 0.02%, while the incidence of those associated with congenital artery fistulae are 5.9%.
- The incidence of CAA is higher in men than in women, 2.2 % versus 0.5%, respectively

- The right coronary artery is the most commonly affected, and it is involved in 40–70% of CAAs, left anterior descending artery (32.3%) and the left circumflex (23.4%) .
- Involvement of three coronary vessels or the left main is a much rarer occurrence (3.5%)

- Atherosclerotic or inflammatory coronary aneurysms are usually multiple and involve more than one coronary artery. In contrast, congenital, traumatic, or dissecting aneurysms typically involve a single artery.
- Causative factors include atherosclerosis, Takayasu arteritis, congenital disorders, Kawasaki disease (KD), and percutaneous coronary intervention.

## presentation

Most CAAs are asymptomatic, but some patients present with angina pectoris, myocardial infarction, sudden death, fistula formation, hemopericardium, tamponade, compression of surrounding structures, or congestive heart failure. Patients with giant CAAs can also present with superior vena cava syndrome or with a mediastinal mass that can be misdiagnosed as a cardiac tumor or thymoma

## Prognosis

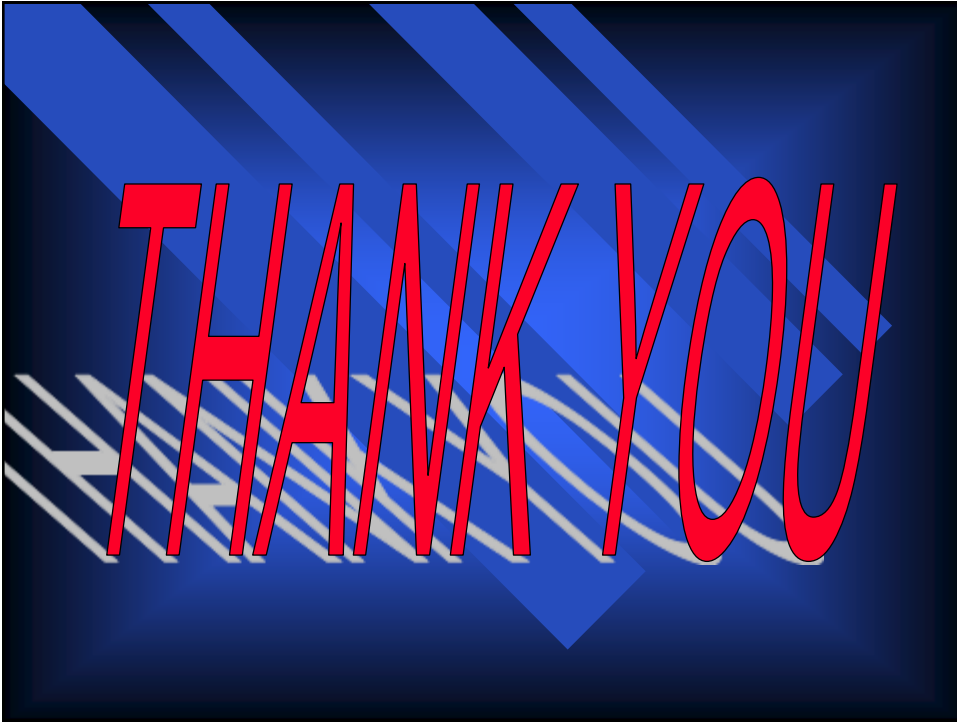Clinical sequelae of giant CAAs include thrombus formation, distal embolization of those thrombi, fistula formation, and rupture.

A frequent finding is the presence of thrombus within the aneurysm. The slow flow of the blood and the irregular internal surface of the aneurysmal wall predispose the lesion to this development

## Management

- Surgical correction is generally accepted as the preferred treatment for giant CAAs. Surgical tactics include aneurysm ligation with distal bypass grafting, isolated coronary artery bypass grafting, aneurysm plication, and saphenous vein patch repair of the aneurysm.
- These procedures are often performed as part of a multivessel bypass operation.

- In the absence of surgical correction, some authors support the use of antiplatelet or antithrombotic treatment (or both) for all large aneurysms, in order to reduce the risk of in situ thrombus or distal embolization.
- It is now possible to treat selected patients with percutaneous techniques that are less invasive; however long-term outcomes are still unknown. Percutaneous options include stent placement with or without coil embolization



Polytetrafluoroethylene (PTFE)-covered stents were introduced in the late 1990s and have been used for treatment of CAAs with some success. In one case, a PTFE-covered stent was used in a patient with a 16 × 22-mm giant CAA in the LAD just distal to a focal stenosis. The stent excluded the aneurysm and eliminated the corresponding stenosis. A follow-up angiogram continued to show exclusion of the aneurysm

- Szalat and associates reported successful treatment of a giant right CAA with a PTFE-coated stent and presented a review of patient who had surgical treatment of their CAAs, compare with those treated with covered stents. In this comparison, stent patients who had aneurysms larger than 10 mm had a higher restenosis rate than did those with a CAA smaller than 10 mm. Therefore, the less invasive, percutaneous approach to CAA exclusion seems reasonable for aneurysms greater than 5 mm but less than 10mm,