

# LEFT SIDED CARDIAC MASSES

BY

**Lamiaa Rashad Sallam**

Head of cardiology and ICU department

Alexandria Police Hospital

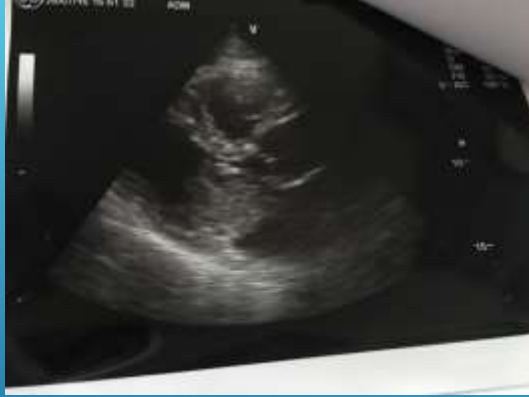## *CASE I*

**A 61 years old male presented to his health insurance doctor with**

- ▶ **dyspnea with effort**
- ▶ **2 episodes of syncope**

▶ **Patient was referred to our center for cardiac consultation**

▶ **Echocardiography was done**

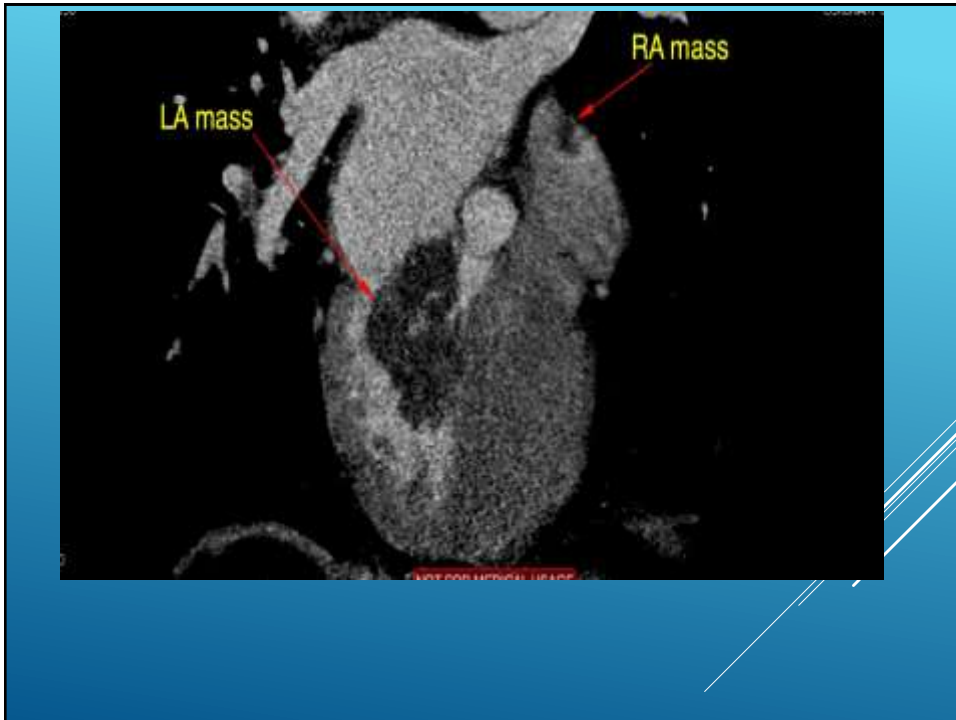


**left atrial large homogenous mass 66\*47 mm, freely mobile , prolapsing through the mitral valve into the left ventricular cavity, and with no calcifications.**

- ▶ **Patient was referred to perform CT coronary angiography for detection of coronary artery disease before open heart surgery for excision of the mass.**
- ▶ **CT angiography was performed using a 64 slice multi detector scanner, and patient received 90cc contrast.**

- ▶ The patient had a significant long distal stenosis of the right coronary artery, and no other lesions of the other coronaries.
- ▶ A large left atrial mass

**PLUS**



- ▶ CT showed the presence of a small right atrial mass 10\*6 mm at the roof of the right atrium
- ▶ The second mass showed the same density ,same HU of the left atrial mass.

- Patient underwent open heart surgery for removal of the two masses, with smooth post operative period
- Histopathological examination confirmed the diagnosis of cardiac myxoma

## MYXOMA

- ▶ The most common primary cardiac tumor in the Age > 35
- ▶ 75% in the Lt. Atrium near fossa ovalis
- ▶ 15% Rt. Atrium
- ▶ 5-10% Lt. Ventricle
- ▶ 5% multiple sites

This case shows the importance of cardiac CT in directing the management of cases with intracardiac mass, as this small mass may have been missed if the patient was referred for a preoperative invasive coronary angiography without performing a cardiac CT

## *CASE II*

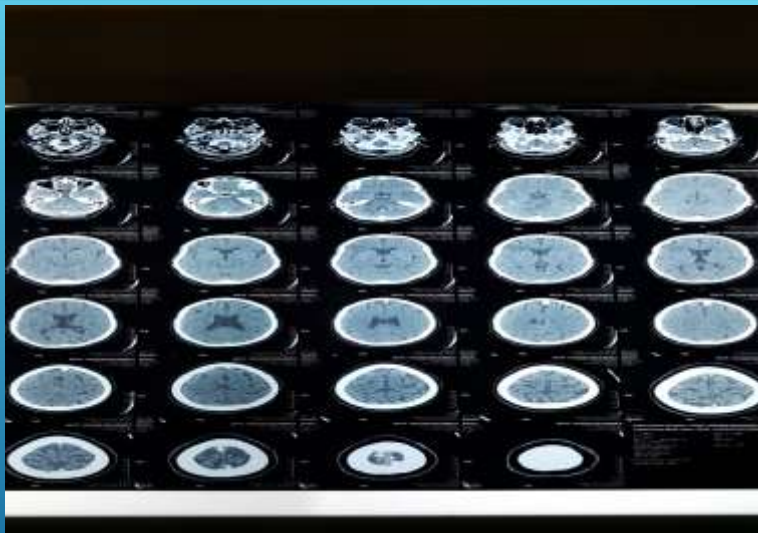
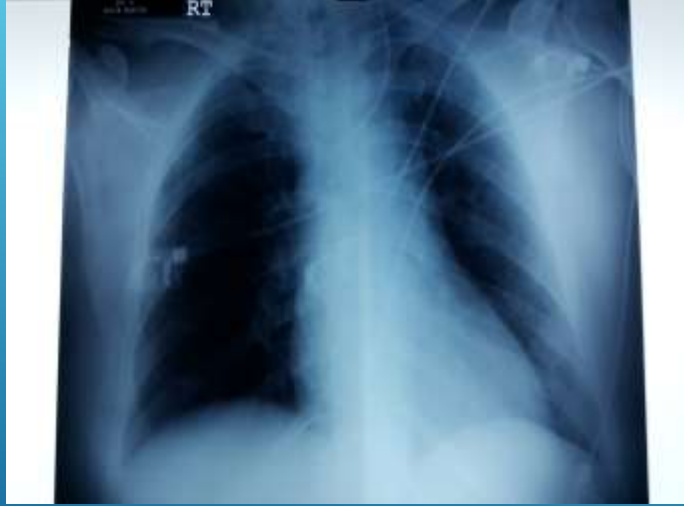47 years old female patient , smoker,  
Hypertensive controlled on medication

**Complaining of:**

- ▶ personality changes in the form of lack of concentration
- ▶ left upper limb weakness for few days....

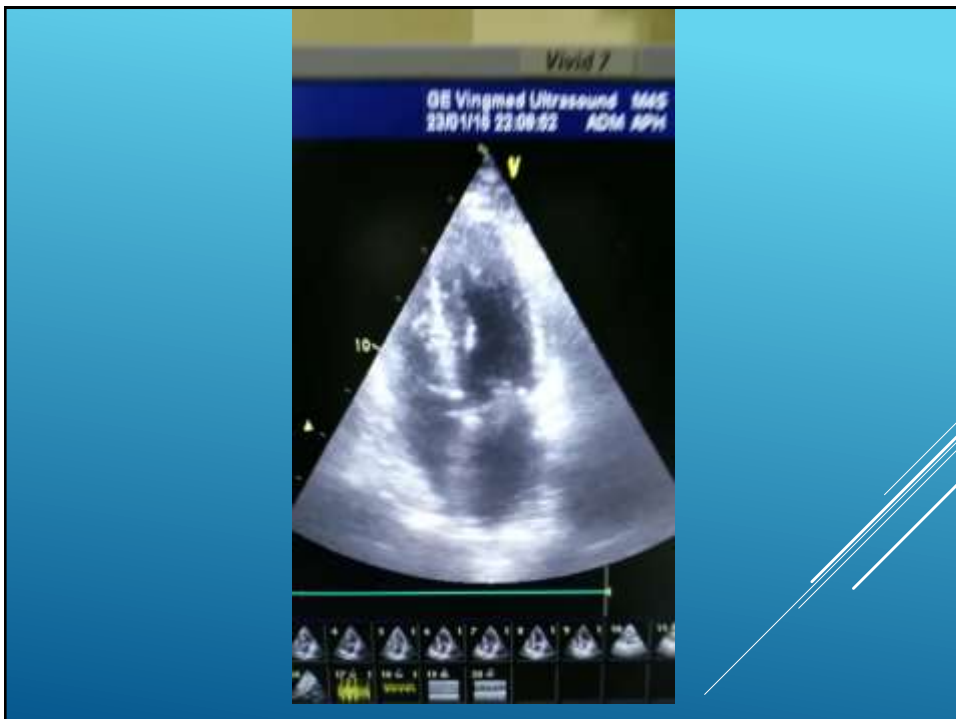
- ▶ No history of fever
- ▶ Vital signs : all within normal
- ▶ No signs of meningeal irritation





**CT BRAIN :  
RT SUBACUTE FRONTAL INFARCTION**

- ▶ ECG was done to exclude atrial fibrillation which showed normal sinus rhythm

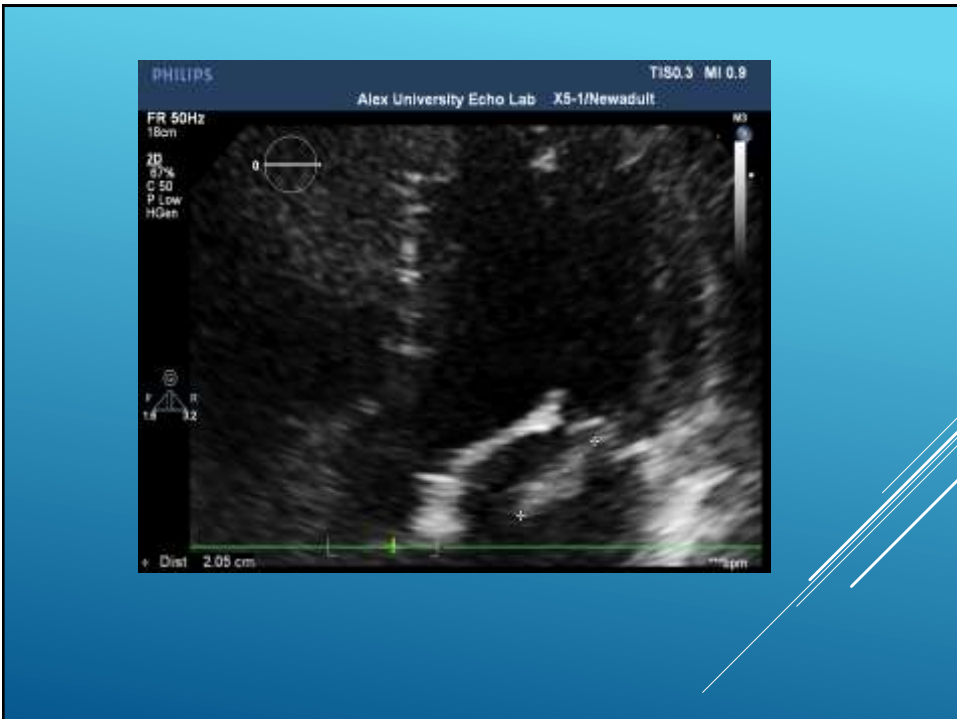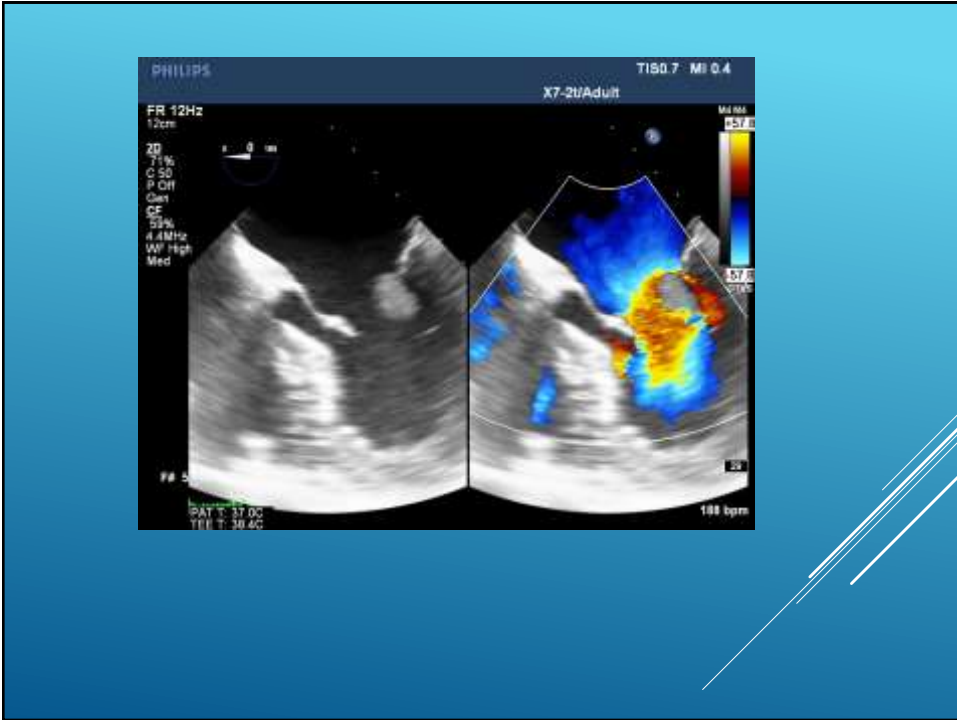


**Echocardiography showed:**

**Mass attached to the posterior mitral leaflet ..highly mobile for differential diagnosis & for further assessment with TEE**

**TEE:**

- ▶ **Highly mobile ecogenic mass with multiple mobile shreds attached to the atrial surface of the posterior leaflet at P2 Scallop ..**
- ▶ **Possible vegetation mesure 2x1 cm.**
- ▶ **There is Mild Mitral valve regurgitation**



**Labs :**

**CRP 24**

**WBC 14.000**

**Sterile blood culture**

**Contious level of the patient completely  
returned to the base line**

**Discharged to the ward**

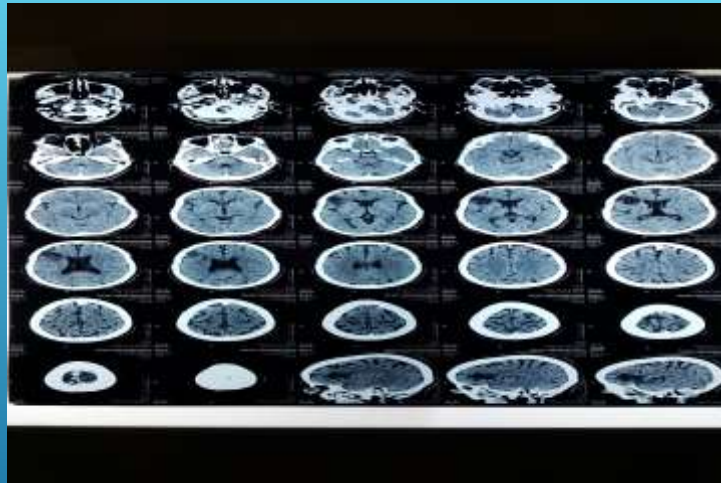
**Descesion was taken by our cardiology  
and critical care consultant:**

**For Urgent surgery due to the presence  
of symptoms of systemic embolization (MCA territory)**

**▶ Cardiothoracic consultation refuse the  
Urgent surgery due to the presence of  
sizable infarction**

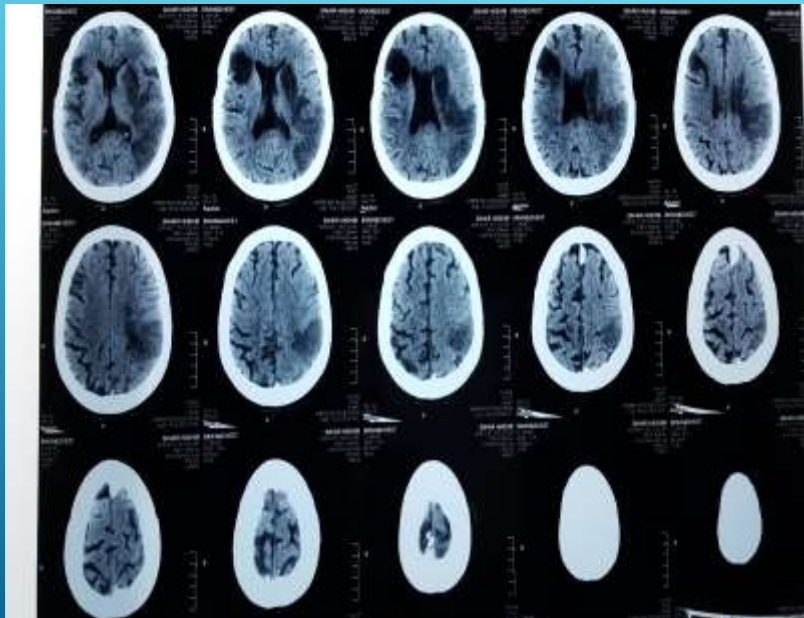
After 3 weeks from the admission date  
...the conscious level of the patient was  
deteriorated

Urgent CT Brain was done revealed  
Multipul recent left temporal hypodense  
areas



The old infarction

Another CT brain done two days latter





**MRI with Diffusion film :  
Acute & subacute left temporo parital  
infarction**

**No sign of the previously discovered mass**

Unfortunately the patient deteriorated stayed on mechanical ventilation for 2 months then arrested

## Papillary fibroelastoma

- ▶ Small tumors (<1cm) with homogeneous speckled pattern
- ▶ Commonly pedunculated with multiple fronds
- ▶ Affect the Lt and Rt sides with same frequency
- ▶ Attach to
  - ▶ Atrial surface of AV valves, and
  - ▶ Ventricular surface of semilunar valves

**Take home message**

**Never to delay surgical intervention with a valvular mobile mass with signs of systemic embolization**

**Thank you**