

# **Acute Coronary Syndrome with an unusual presentation**

**Ahmed Kamel,MD,FEBC,FSCAI**

**National Heart Institute**

**CardioEgypt**

**2018**

## **Clinical presentation**

My patient is an active 59 years old man , ex smoker,not diabetic or hypertensive

He hsa a positive family history of coronary artery disease ,his father died after a heart attack and his brother had CABG 3 years before presentation.

.

## Symptoms and investigations

He had an acute attack of resting retrosternal chest pain when he was at his office .He went to the ER where he had an ECG that was normal and one set of Troponin and CK MB that was negative.

He was discharged home and advised to have a stress test.

During the test , was able to run for 12 minutes just achieved 70 % of his age predicted target heart rate before he had angina and 1mm horizontal ST depression in the anterior leads. Duke treadmill score of -1

## Decision

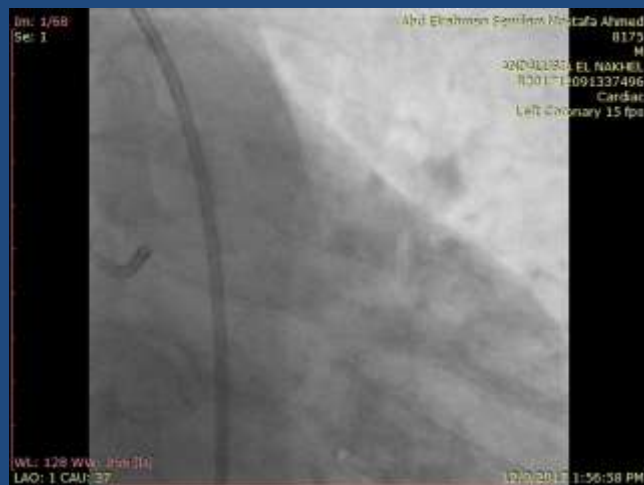He came to me with his stress test diagnosed as low risk positive test and was prescribed medical treatment ASA,Statin,B blocker,Nitrate .

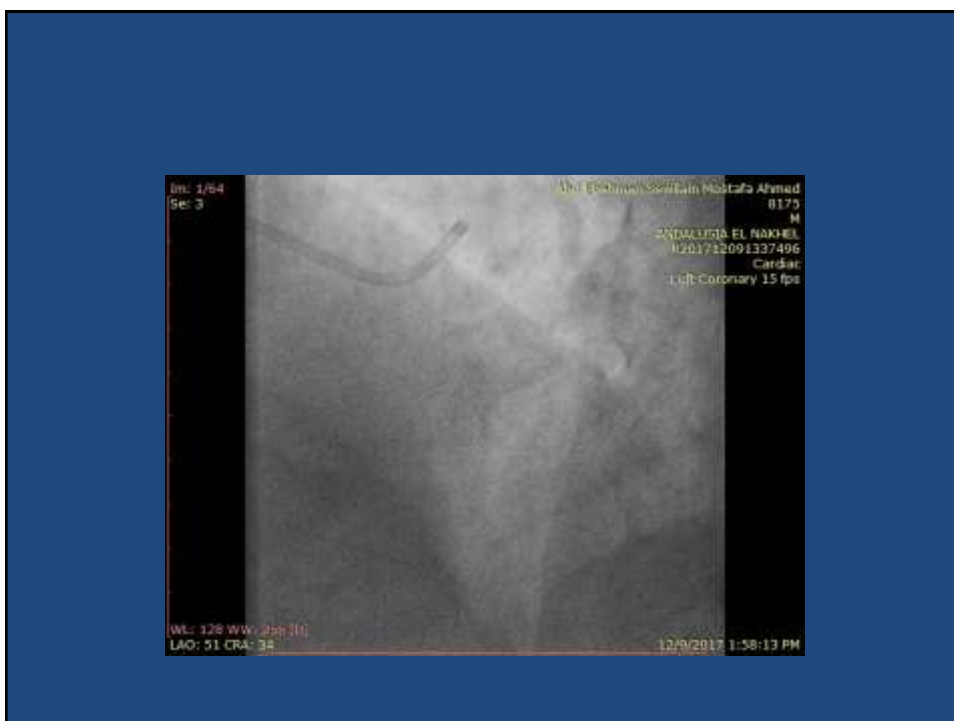
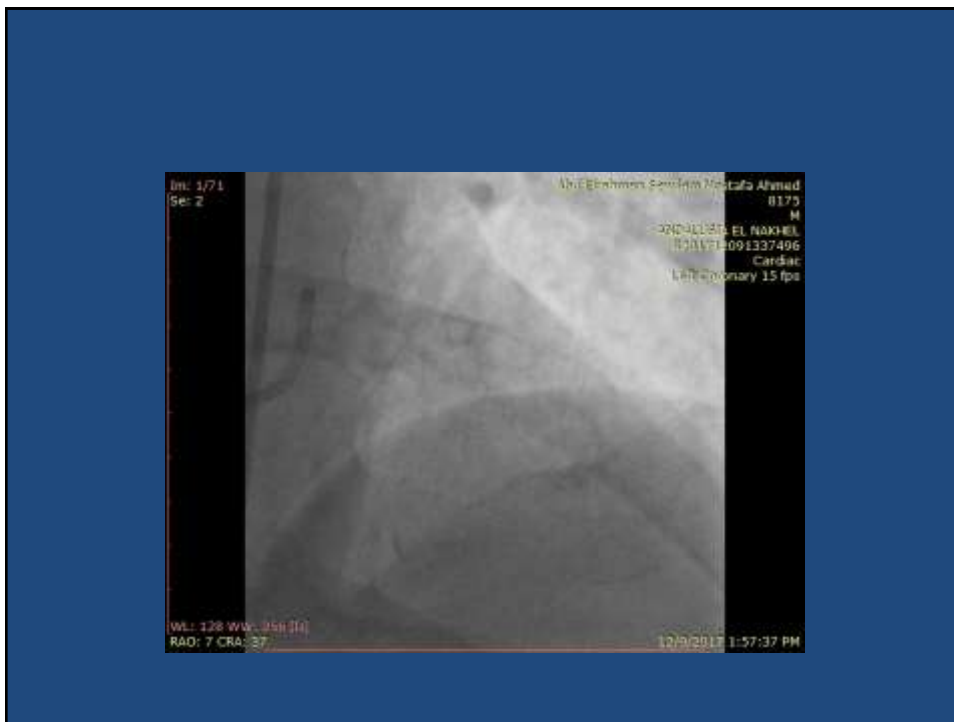
I advised him to come for a follow up visit after two weeks.

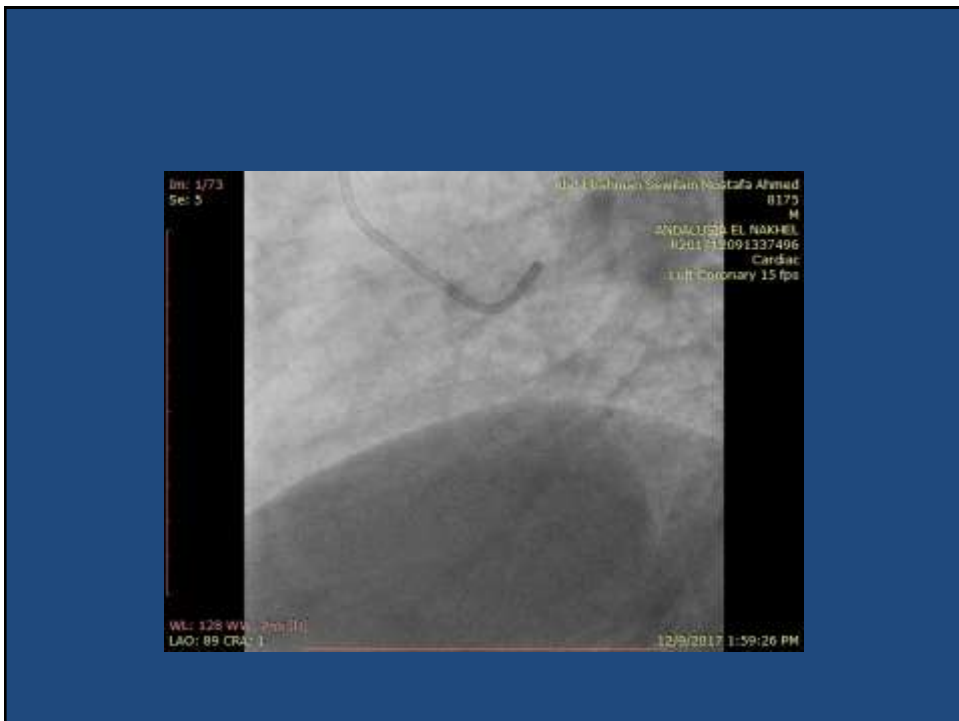
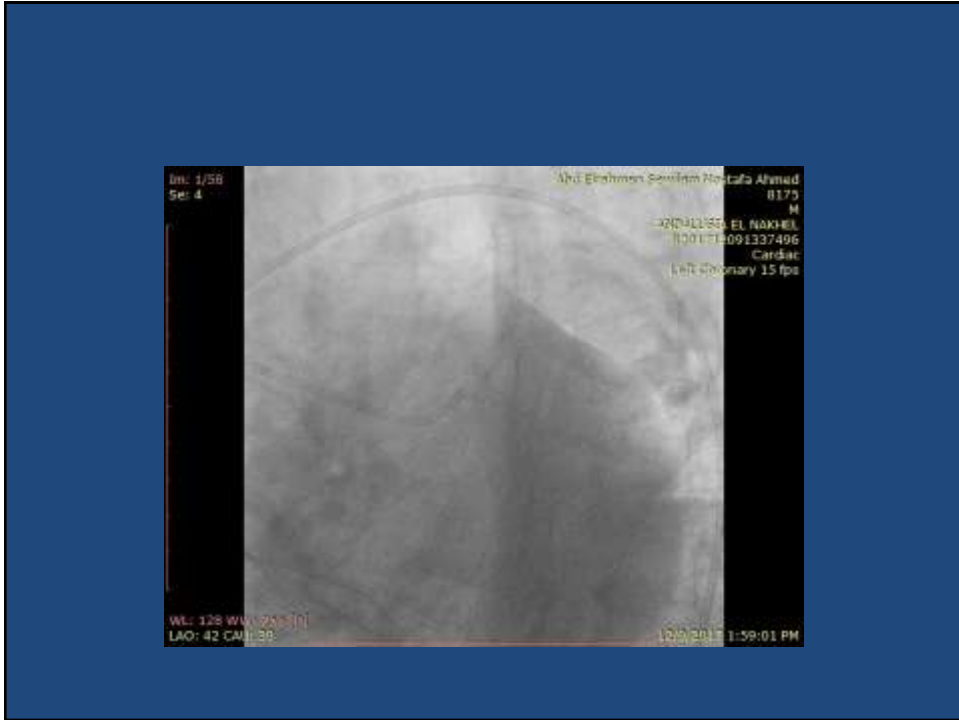
# Follow up

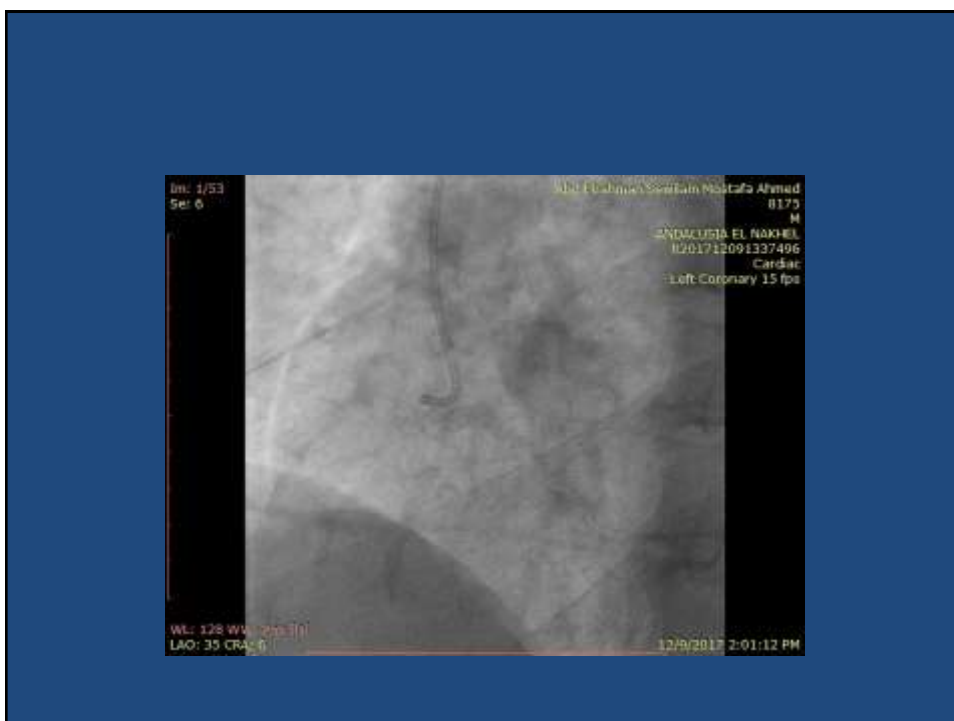
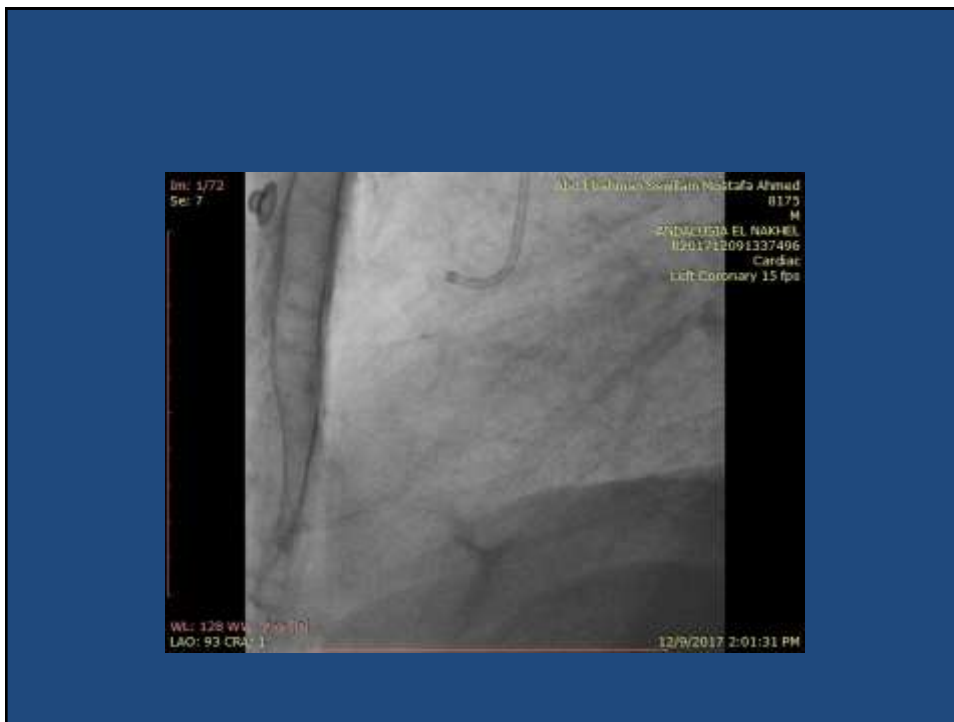
On follow up ,he was unable to perform his weekly work out for 2 weeks although he was compliant to his medications.

So we decided to go for coronary angiography.









## Coronary angiography

There is a proximal LAD tight stenotic lesion followed by a mid segment true bifurcation lesion involving the ostium of a very large diagonal branch which shows a proximal stenosis as well.

The LCX shows a proximal borderline stenotic lesion followed by another tight lesion before it gives a large OM branch that shows a very tight stenosis

The RCA shows a proximal non significant stenosis.

## Treatment plan

The patient has multi vessel coronary disease with proximal LAD tight stenosis followed by a true LAD,D1 bifurcation lesion.

The LCX is a co dominant vessel that shows a proximal borderline stenotic lesion followed by another tight lesion before it gives a large OM branch that shows a very tight stenosis

For total revascularization by either PCI or CABG.

## Decision

**Syntax score I** was calculated **23**

**Syntax score II** showed **nearly equal results with PCI or CABG**

The case was discussed with the patient and his family and they refused CABG so we prepared for PCI.

The 6 F sheath was replaced with a 7 F one .

## Another decision

- Is it better to start provisional or to do a two stent strategy?
- If provisional ,what will be my backup plan?
- If the decision is a two stent technique, which one?



## Nordic Bifurcation Study 5 years follow up

### Long-term results after simple versus complex stenting of coronary artery bifurcation lesions: Nordic Bifurcation Study 5-year follow-up results.

Maeros M<sup>1</sup>, Holm NR, Erola A, Kurwan J, Niemelä M, Kervinen K, Jensen JB, Galis A, Steigen TK, Wiseth B, Nørbulte J, Gunnas P, Mannwert J, Meyerliants O, Bottoyati S, Nikus K, Vilman S, Ravkilde J, James S, Aanes J, Ytalo A, Helqvist S, Bidoran J, Thavayen P, Virtanen K, Puhakka M, Araisanen J, Christiansen EH, Lassen JF, Thuesen L, Nordic-Baltic Percutaneous Coronary Intervention Study Group

#### Author information

#### Abstract

**OBJECTIVES:** This study sought to report the 5-year follow-up results of the Nordic Bifurcation Study.

**BACKGROUND:** Randomized clinical trials with short-term follow-up have indicated that coronary bifurcation lesions may be optimally treated using the optional side branch stenting strategy.

**METHODS:** A total of 413 patients with a coronary bifurcation lesion were randomly assigned to a simple stenting strategy of main vessel (MV) and optional stenting of side branch (SB) or to a complex stenting strategy, namely, stenting of both MV and SB.

**RESULTS:** Five-year clinical follow-up data were available for 404 (98%) patients. The combined safety and efficacy endpoint of cardiac death, non-procedure-related myocardial infarction, and target vessel revascularization were seen in 15.8% in the optional SB stenting group as compared to 21.8% in the MV and SB stenting group ( $p = 0.15$ ). All-cause death was seen in 5.9% versus 10.4% ( $p = 0.16$ ) and non-procedure-related myocardial infarction in 4% versus 7.9% ( $p = 0.09$ ) in the optional SB stenting group versus the MV and SB stenting group, respectively. The rates of target vessel revascularization were 13.4% versus 19.3% ( $p = 0.14$ ) and the rates of definite stent thrombosis were 3% versus 1.5% ( $p = 0.31$ ) in the optional SB stenting group versus the MV and SB stenting group, respectively.

**CONCLUSIONS:** At 5-year follow-up in the Nordic Bifurcation Study, the clinical outcomes after simple optional side branch stenting remained at least equal to the more complex strategy of planned stenting of both the main vessel and the side branch.

Copyright © 2013 American College of Cardiology Foundation. Published by Elsevier Inc. All rights reserved.

## Eurointervention 2016

### CLINICAL RESEARCH

Volume 11 | Issue 1 | 2016

### Percutaneous coronary intervention for coronary bifurcation disease: 11<sup>th</sup> consensus document from the European Bifurcation Club



Jens Flørsted Lassen<sup>1\*</sup>, MD, PhD, Niels Ramung Holm<sup>2</sup>, MD, Adrian Banning<sup>3</sup>, MD, PhD, Francesco Barzotta<sup>4</sup>, MD, PhD, Thierry Lefèvre<sup>5</sup>, MD, Alaide Claeffly<sup>6</sup>, MD, David Hildick-Smith<sup>7</sup>, MD, Yves Louvard<sup>8</sup>, MD, Goran Stankovic<sup>9</sup>, MD, PhD

<sup>1</sup> Department of Cardiology, The Heart Centre, Rigshospitalet, University of Copenhagen, Copenhagen, Denmark; <sup>2</sup> Department of Cardiology, Aarhus University Hospital, Skejby, Aarhus, Denmark; <sup>3</sup> Cardiovascular Medicine Division, Radcliffe Department of Medicine, John Radcliffe Hospital, Oxford, United Kingdom; <sup>4</sup> Institute of Cardiology, Catholic University of the Sacred Heart, Rome, Italy; <sup>5</sup> Institut Cardiovasculaire Paris Sud, Massy, France; <sup>6</sup> Interventional Cardiology, University of Turin, Turin, Italy; <sup>7</sup> University of Liverpool, Liverpool, United Kingdom; <sup>8</sup> Institut de Cardiologie de Paris, Paris, France; <sup>9</sup> Department of Cardiology, University of Zagreb, Zagreb, Croatia

## When is the provisional approach not appropriate?

The recent EBC II trial provides insight into the provisional technique vs. culotte two-stent technique in bifurcation lesions (SB  $\geq 2.50$  mm and more than 50% SB diameter stenosis): it confirms that a minority of bifurcation lesions requires a “two-stent strategy”. However, lesions with difficult wiring or large SB with extensive disease extending  $>5$ -10 mm beyond the bifurcation may be best approached electively with a two-stent technique.

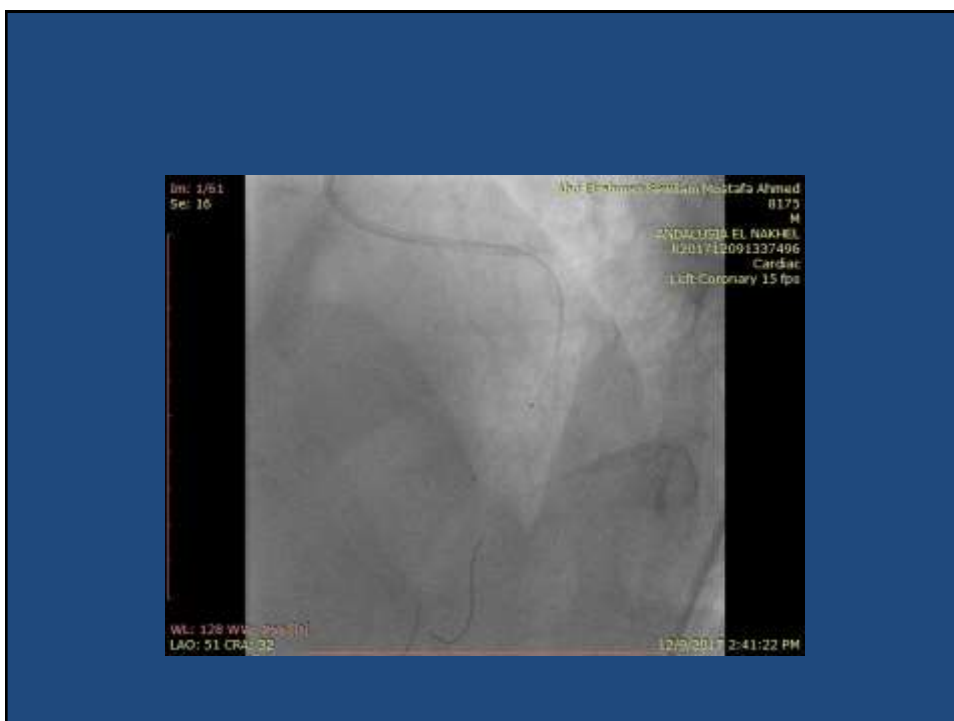
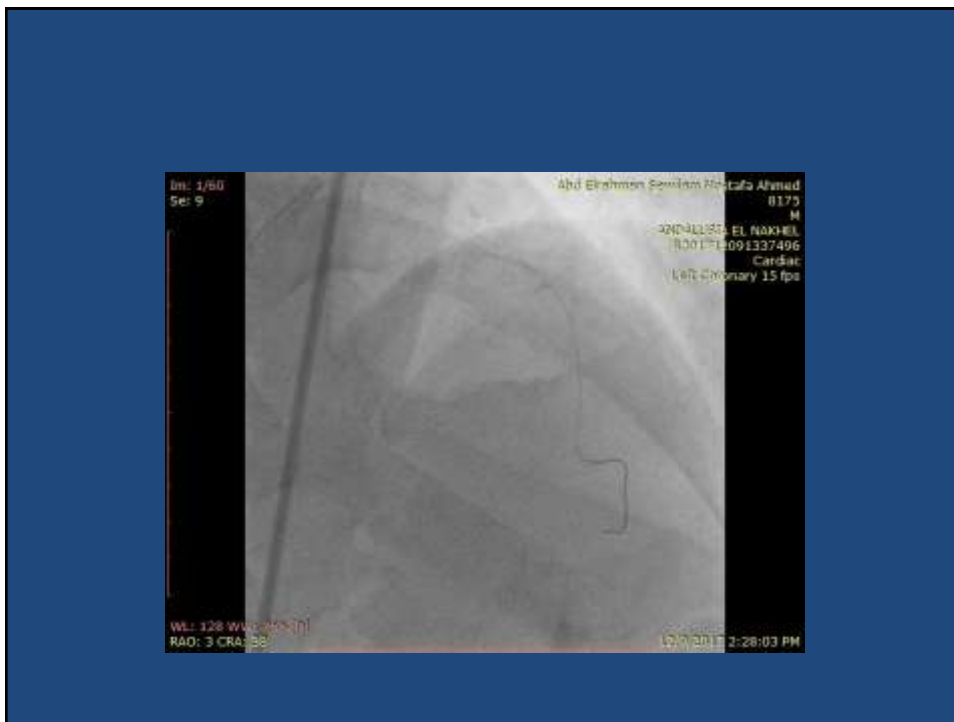
## Eurointervention 2018

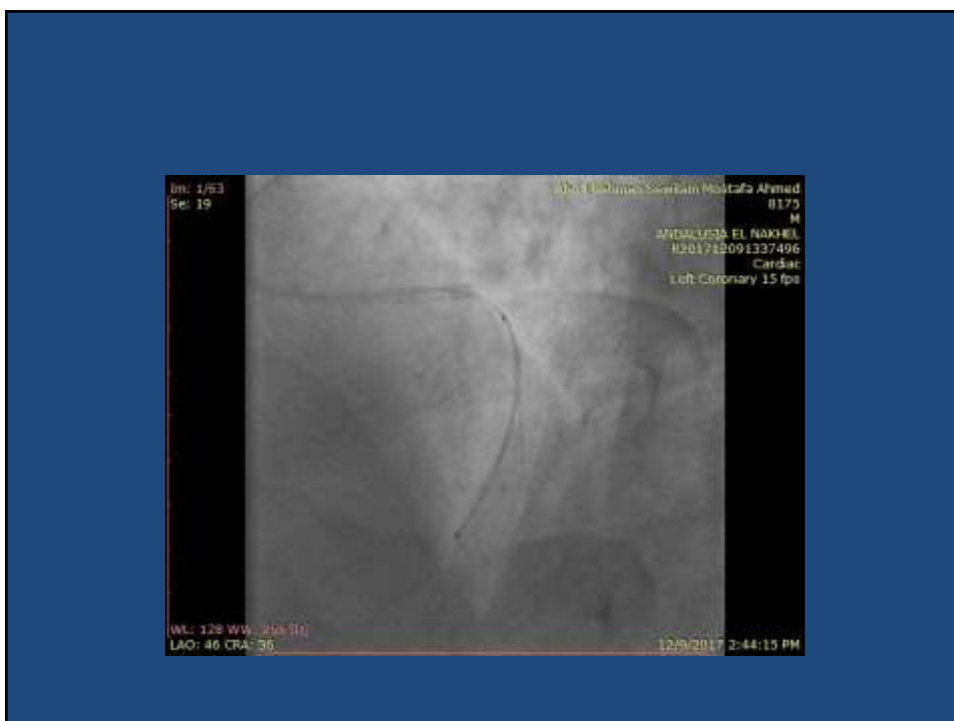
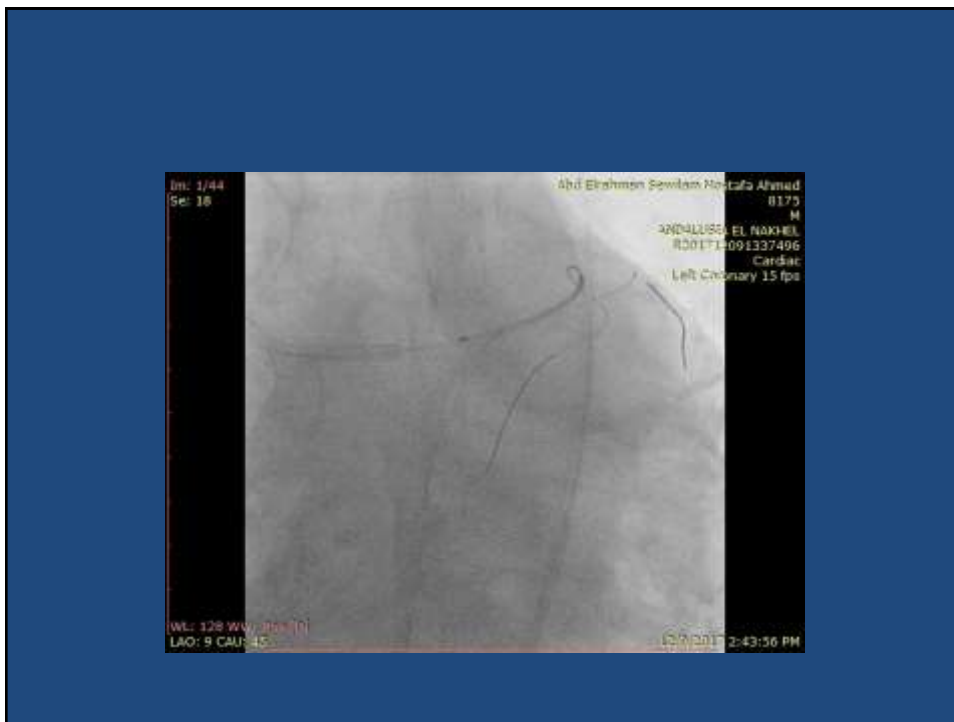
### Step-by-step manual for planning and performing bifurcation PCI: a resource-tailored approach

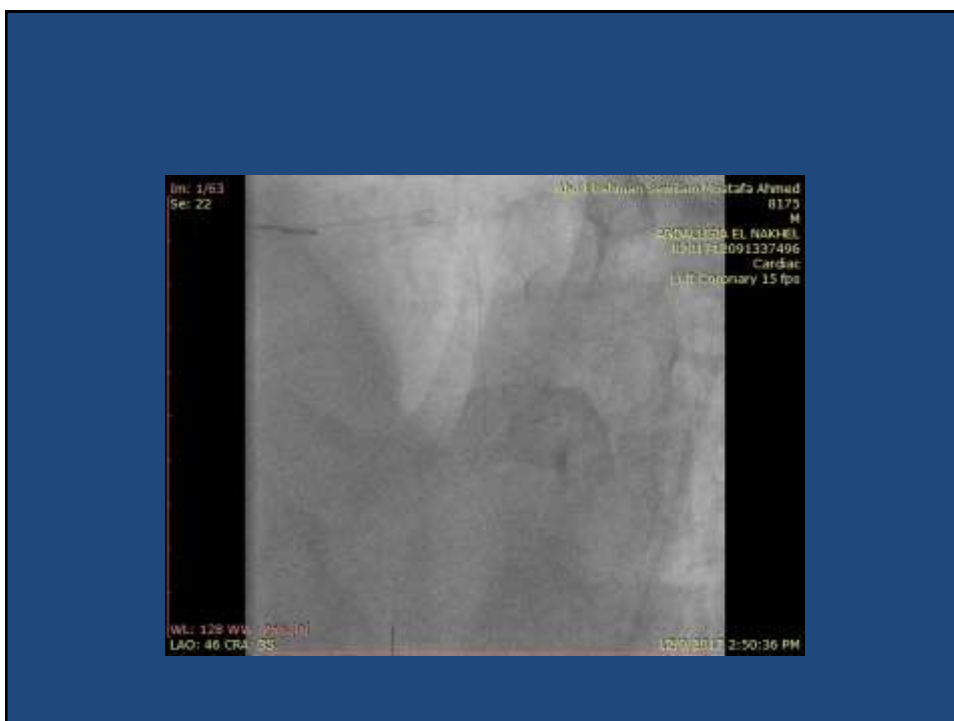
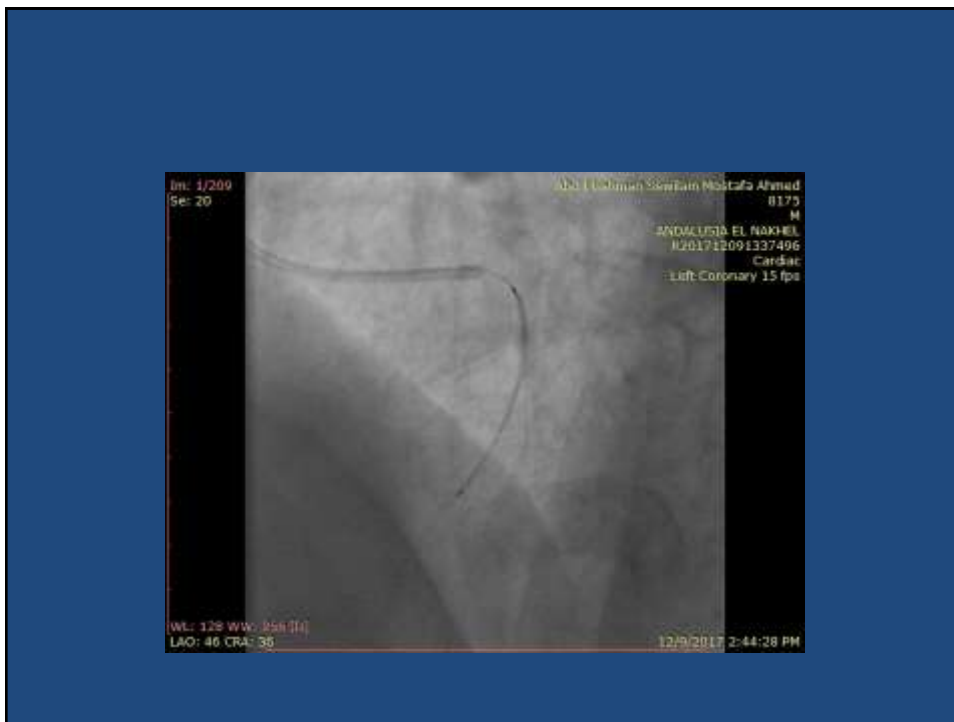


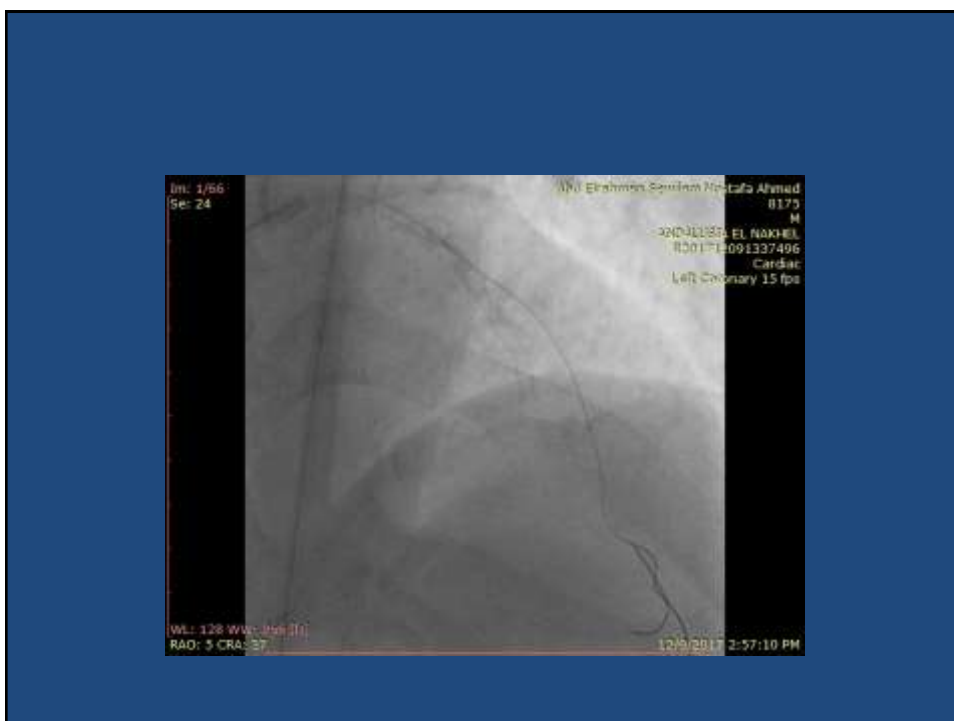
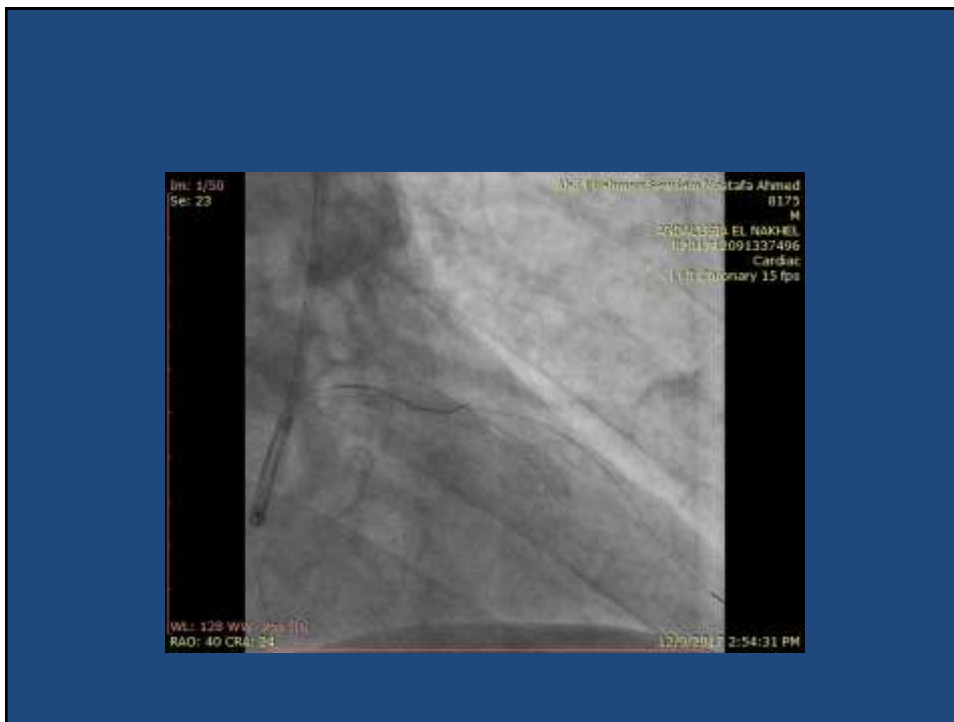
Dejan Milasinovic<sup>1</sup>, MD; William Wijns<sup>2,3</sup>, MD, PhD; Mpiko Ntsekhe<sup>4</sup>, MD, PhD; Farrel Hellig<sup>5</sup>, BSc, MBBCh, FCP(SA), FSCAI; Awad Mohamed<sup>6</sup>, MSc, MD, FRCP; Goran Stankovic<sup>1,7\*</sup>, MD, PhD

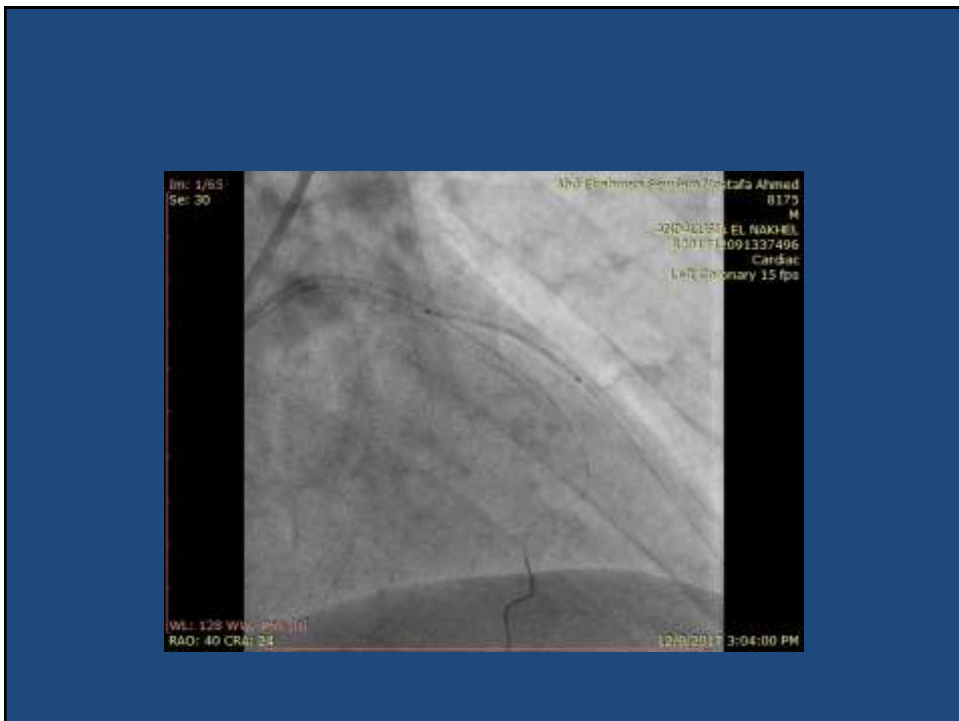
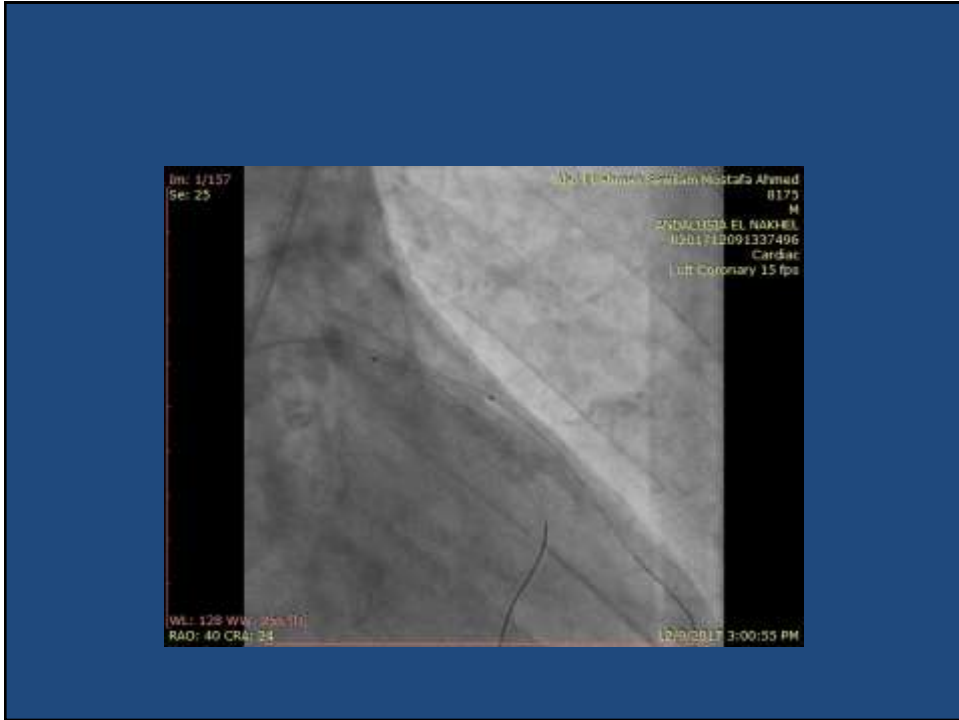
*1. Department of Cardiology, Clinical Center of Serbia, Belgrade, Serbia; 2. The Lambé Institute for Translational Medicine and Care, National University of Ireland, Galway, Ireland; 3. Saolta University Healthcare Group, Galway, Ireland; 4. Division of Cardiology, University of Cape Town, Cape Town, South Africa; 5. Division of Cardiology, University of Cape Town, Cape Town, South Africa, and Stanninghill Hospital, Johannesburg, South Africa; 6. Department of Medicine, University of Khartoum, Khartoum, Sudan; 7. Faculty of Medicine, University of Belgrade, Belgrade, Serbia*

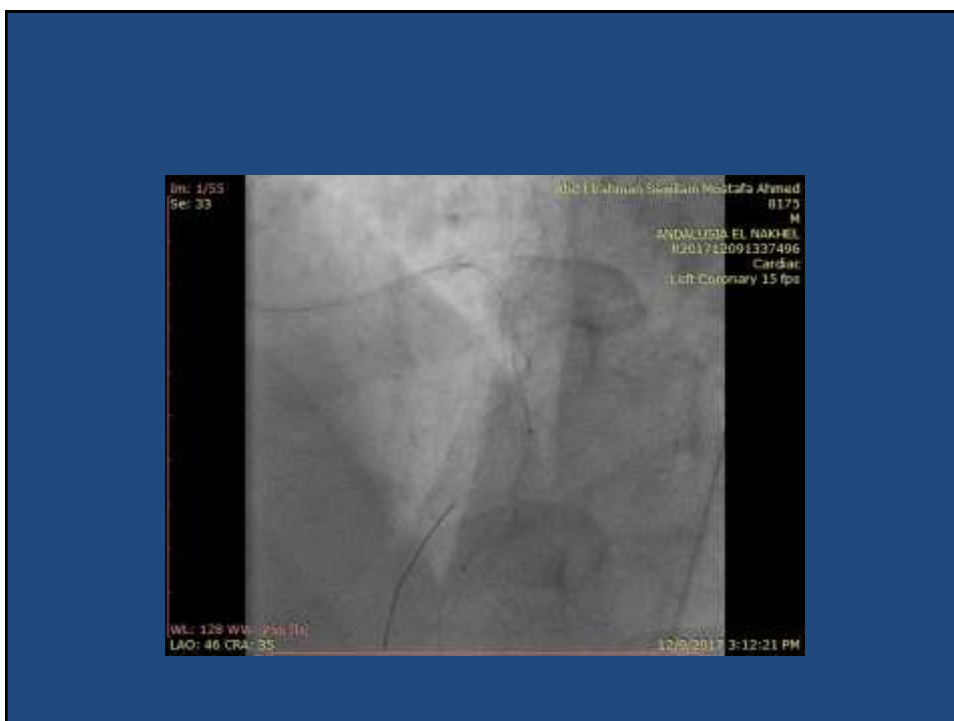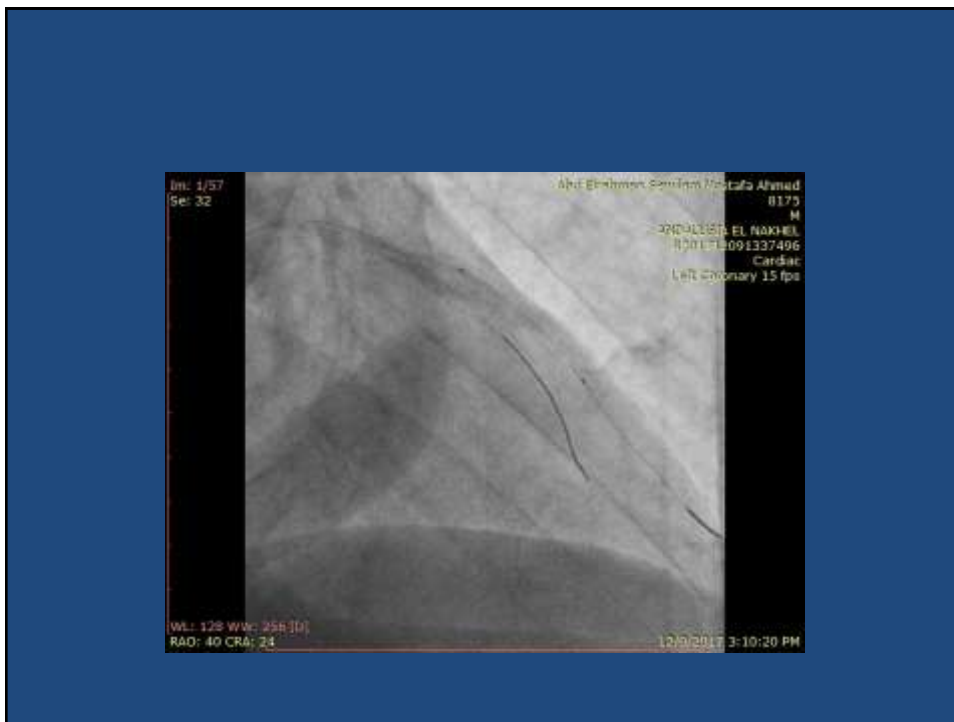




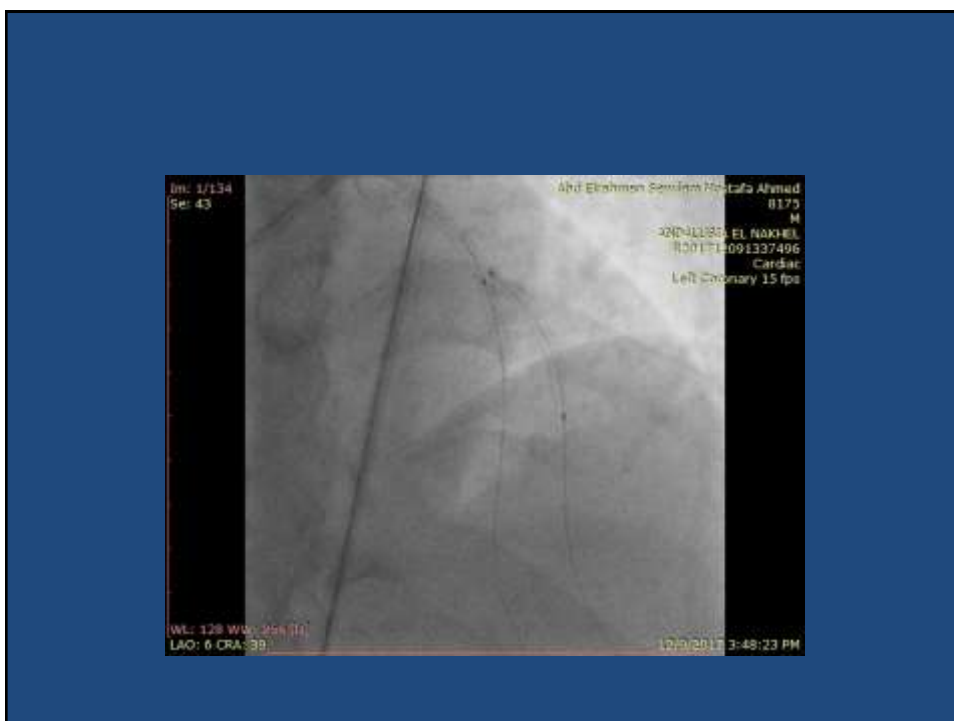
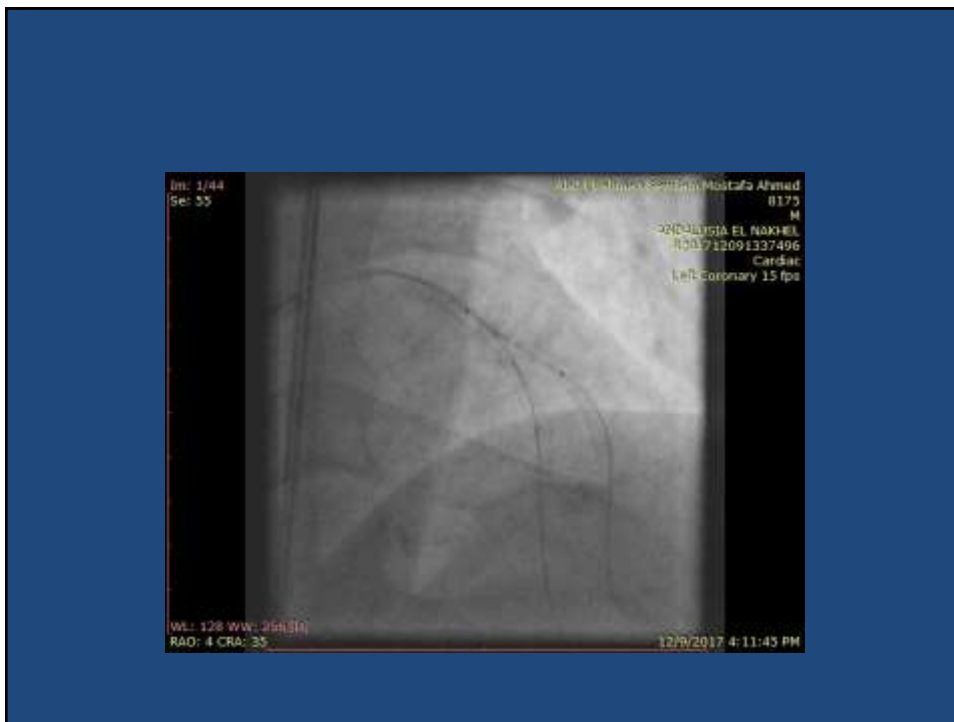


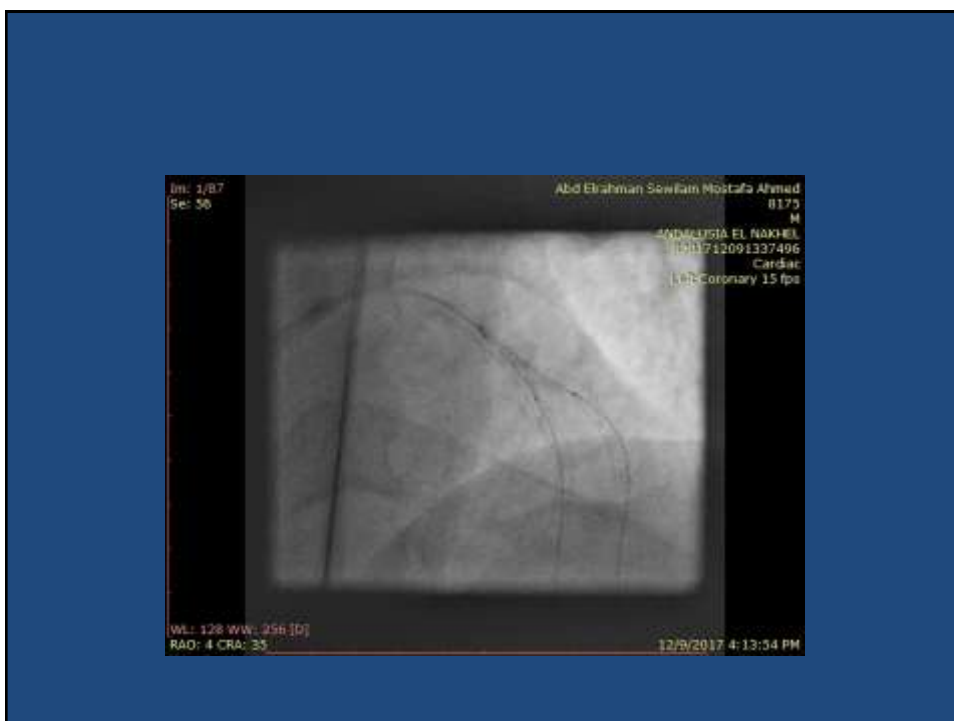
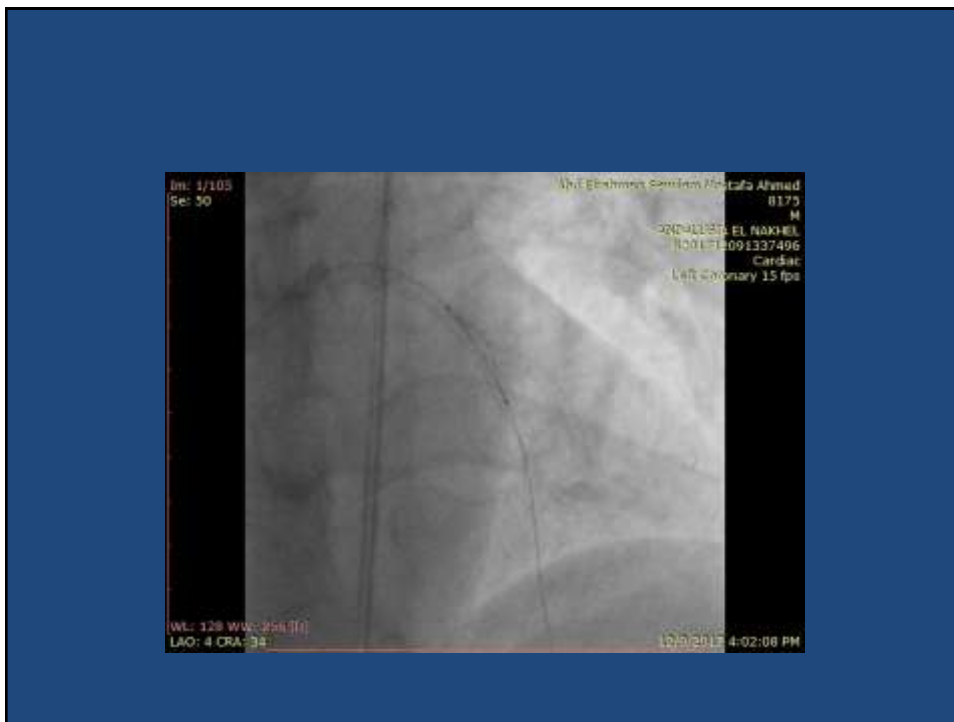


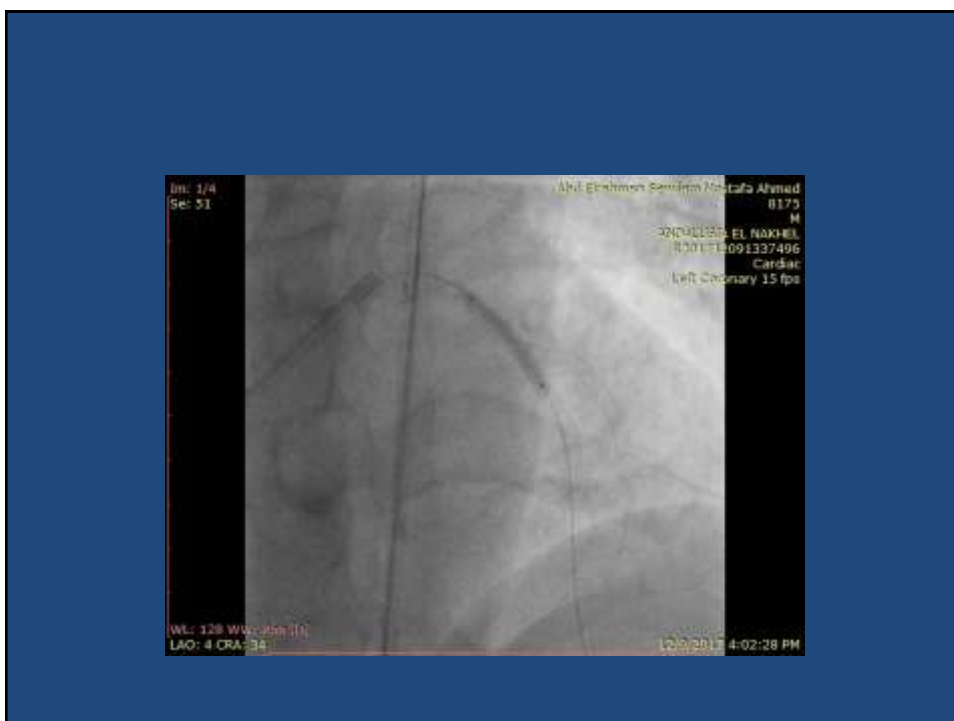
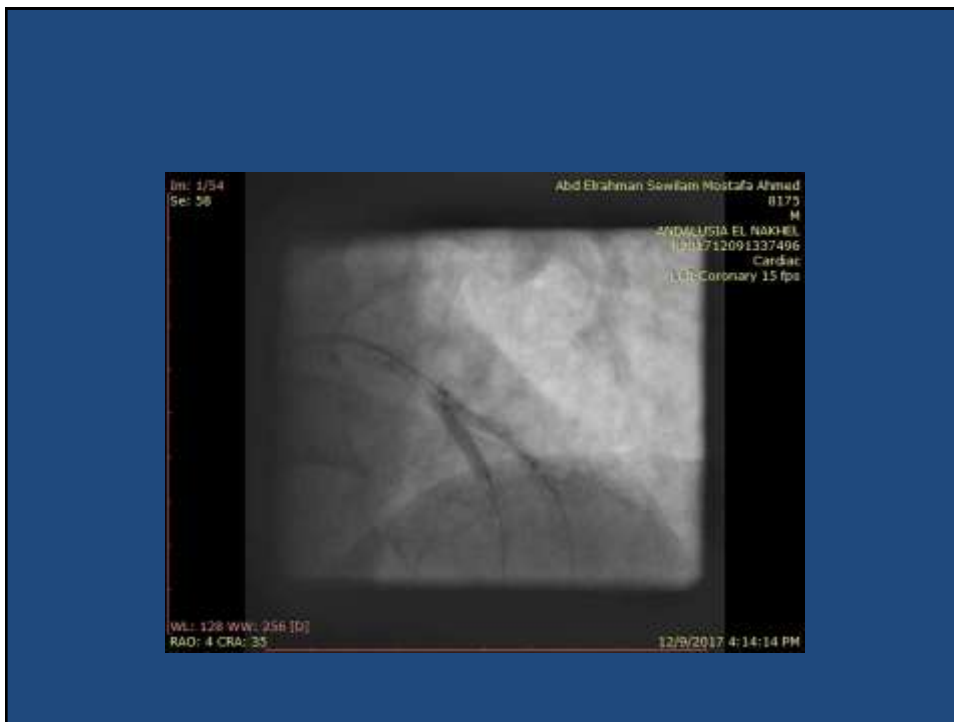


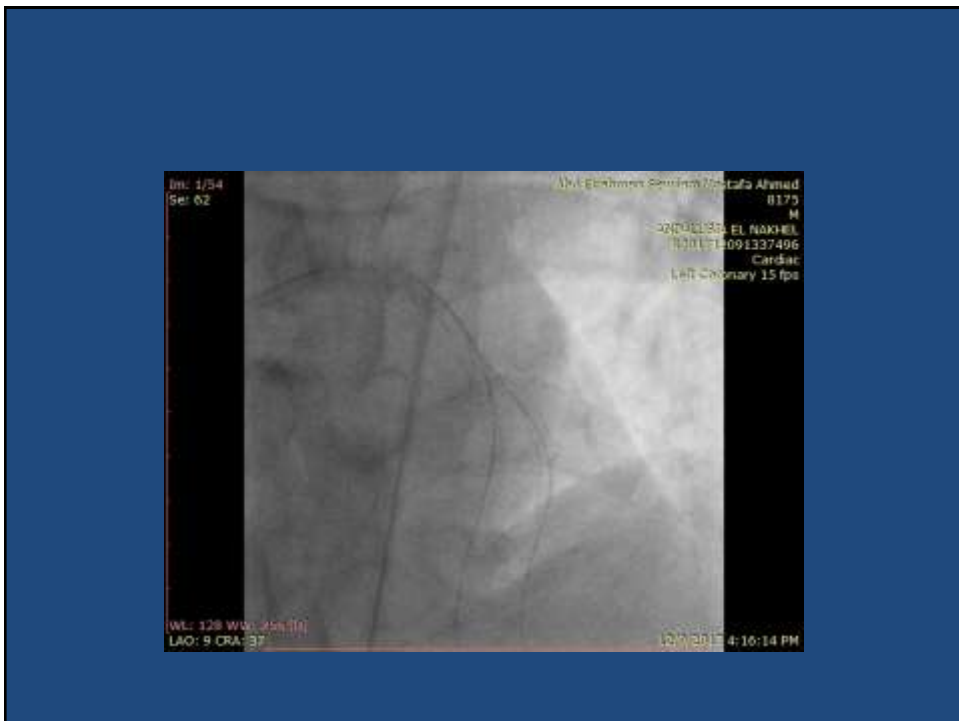
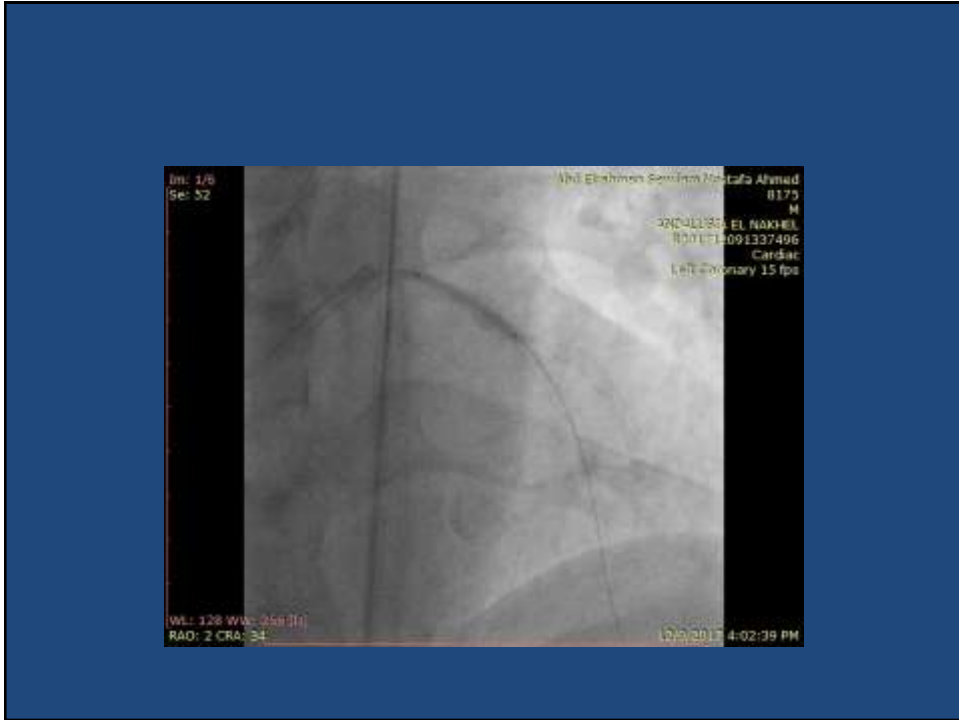


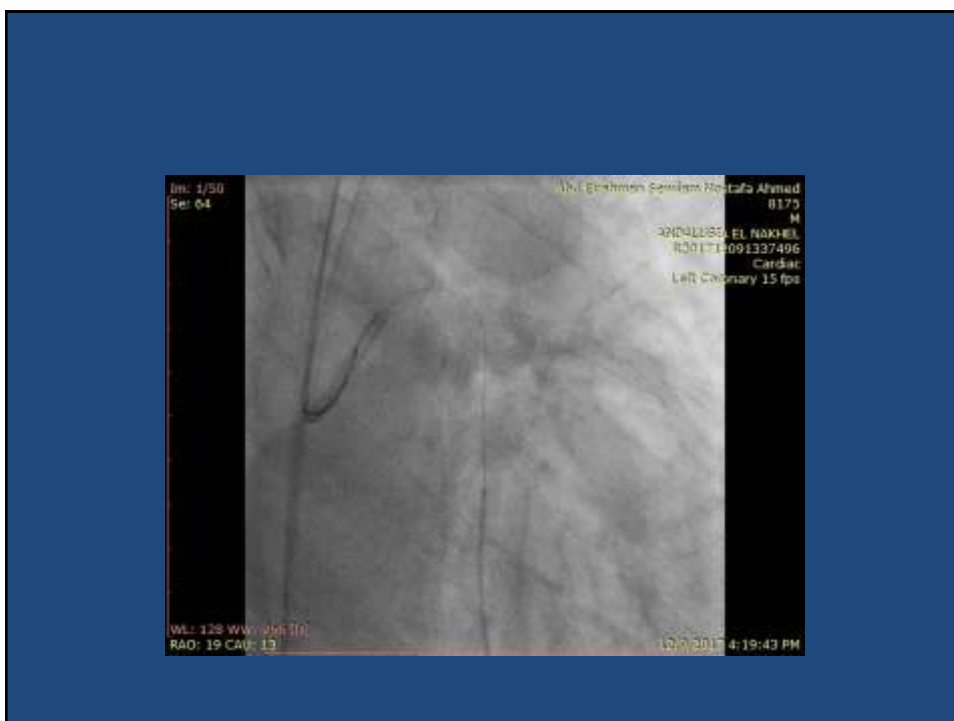
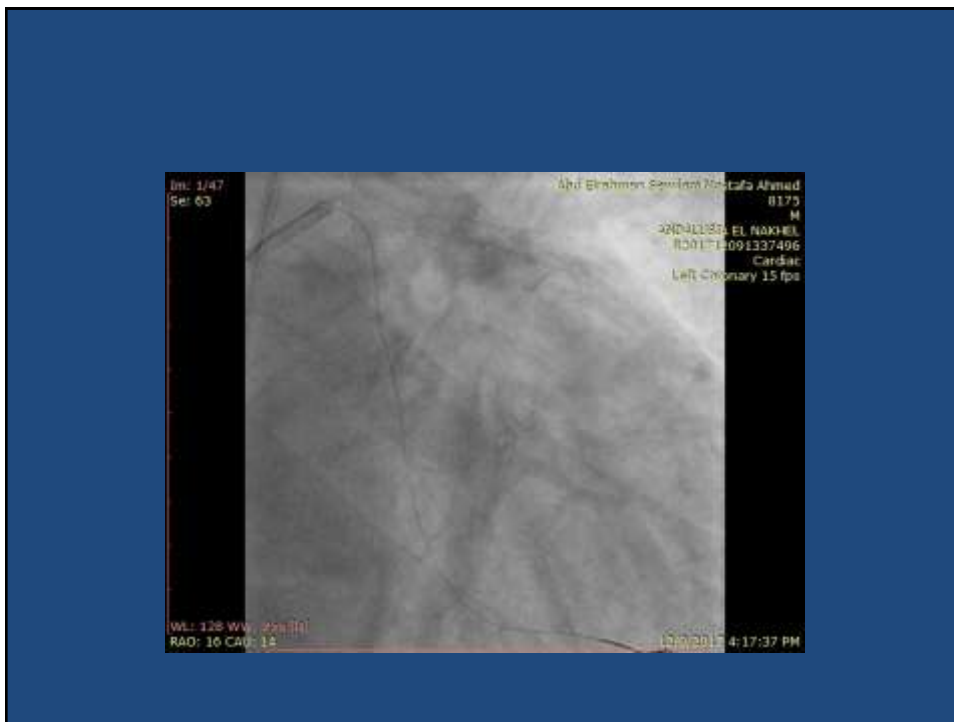


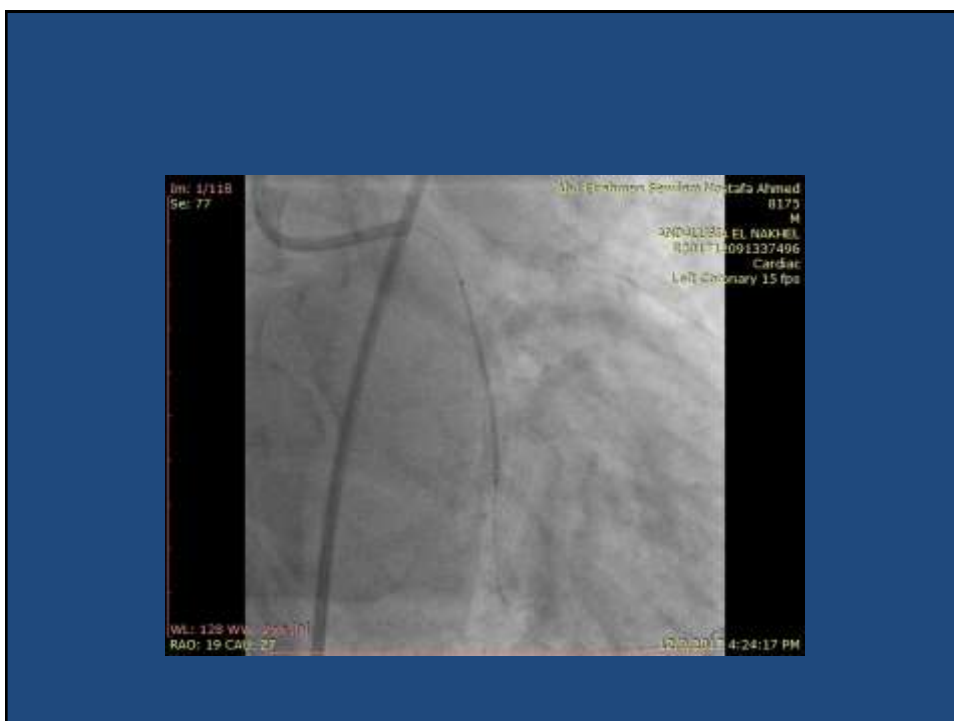
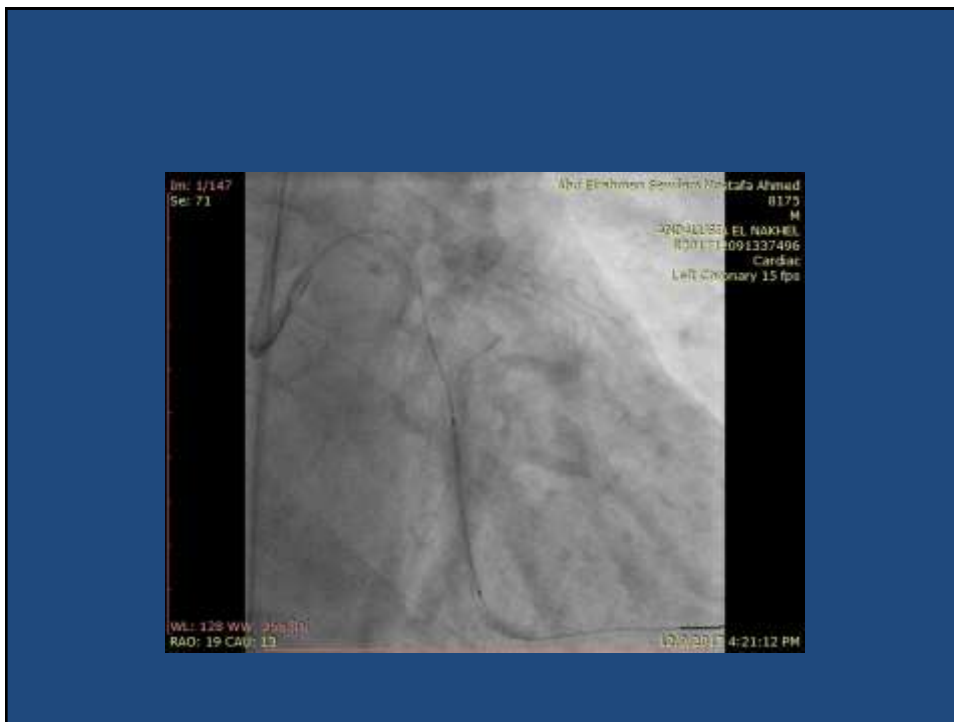


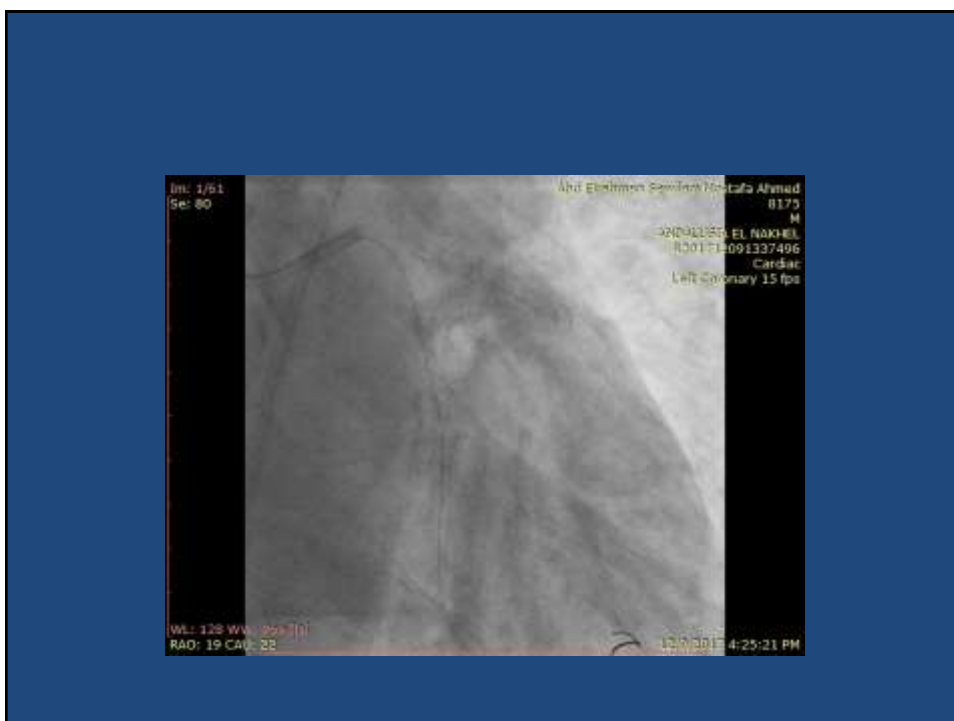
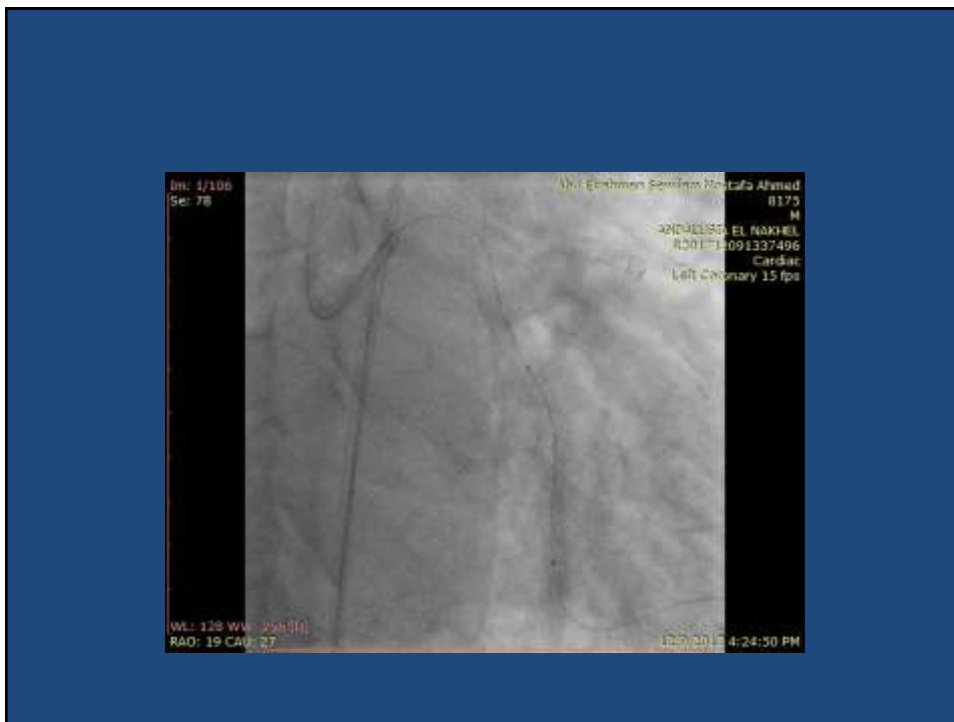












## The take home message

1. Non invasive tests are very Important for proper diagnosis and risk stratification of low risk ACS patients.

2. In patients with multivessel coronary artery disease with complex anatomy it is better not to do ad hoc PCI, heart team discussion is mandatory with calculation of the risk scores as Syntax score I and II, Euro score and STS score.

## Take home message

- 3. Bifurcation PCI is complex and technically demanding, provisional stenting is preferred over two stent strategy except in some cases where the side branch is big with extensive disease that extends > 10 mm distal to the SB ostium.
- 4. There are many techniques for performing a two stent strategy as mini crush, DK crush and Culotte techniques, mastering of these techniques is mandatory for all interventional cardiologists.



## Take home message

5- Proper judgment and decision making based on guidelines and experience are much more important than hand skills alone.

