

Case Presentation

Mohammed Osheiba

**Assistant lecturer of cardiovascular medicine,
Tanta University**

History

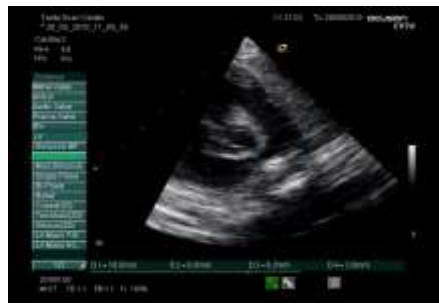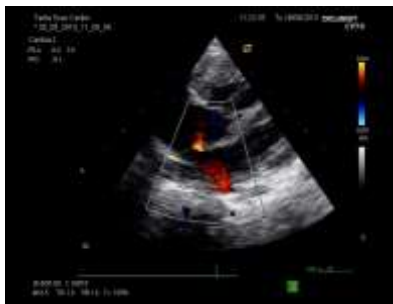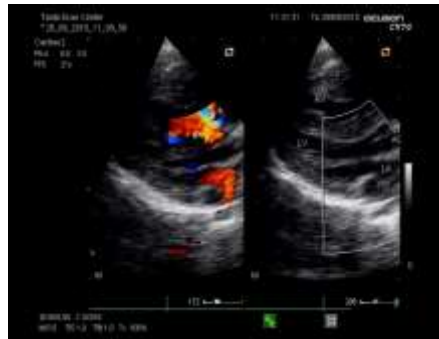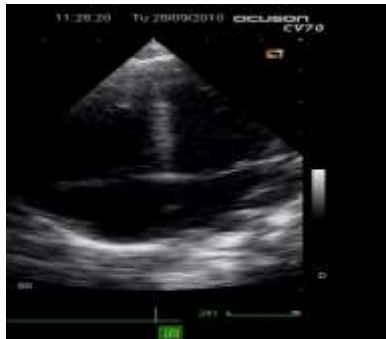- Female child aged 1.5 Y. referred for echocardiography by her pediatric doctor
- The mother was complaining that she is easy fatigable and tachypnic with mild effort and delayed growth

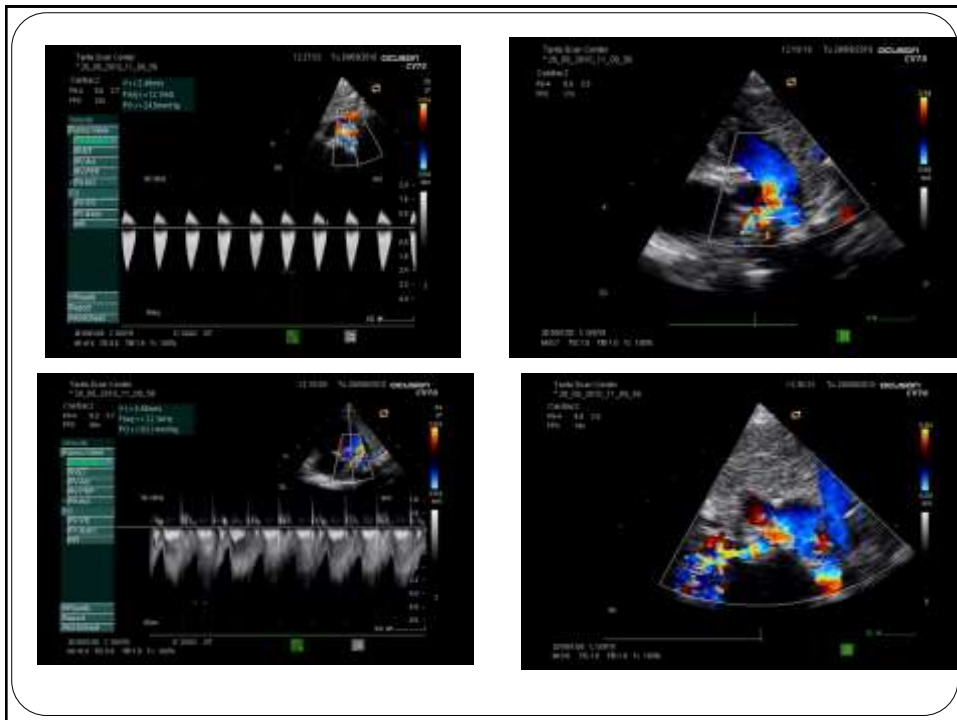
EX:

- Looks underweight(8.5Kg),and malnourished.
- Has large forehead and deep-set eyes.
- Delayed milestone as she can just sit alone but can't stand alone and delayed teeth eruption.

Echocardiographic Data

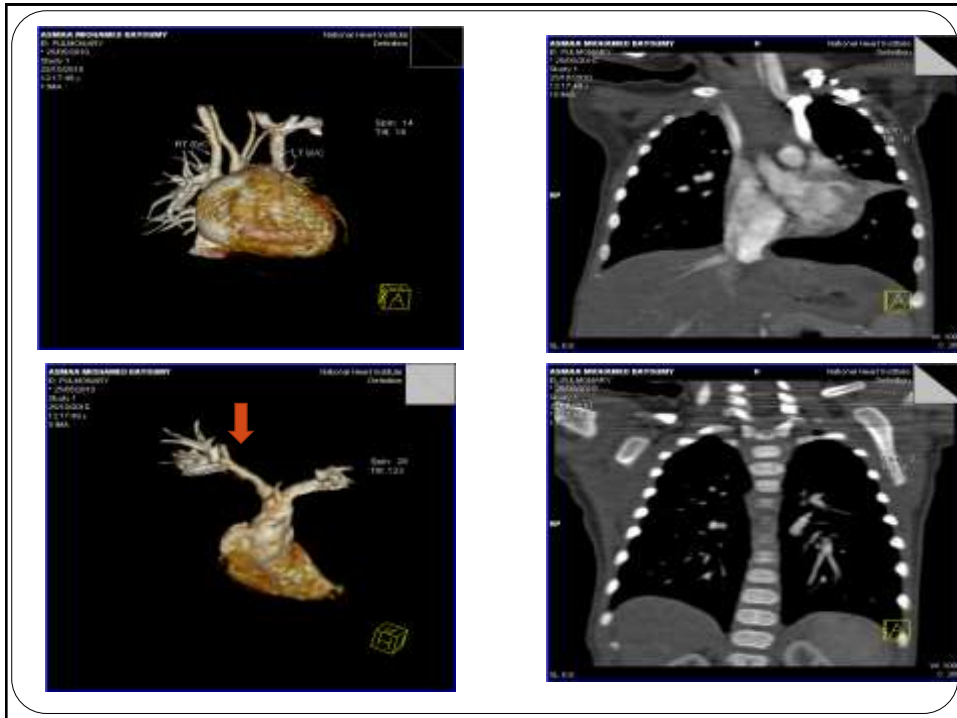
- Mild dilation of right sided cardiac structure for age with good function.
- Aneurismal inter-atrial septum with 4 mm PFO caused mild shunt through it.
- Confluent pulmonary artery and proximal part of its branches, average morphology pulmonary valve.
- Small caliber mid right branch that showed increased gradient to record PG about: 45 mmHg. While RVOT maximum PG: 11 mmHg, mean PG: 5.6mmHg & VTI: 23.7 cm.
- High suspicious of persistent left SVC drain into dilated coronary sinusous.
- Other segmental analysis data are with in normal.





MS CT was done and showed:

- Cardiomegaly with right atrio-ventricular hypertrophy.
- Confluent pulmonary arteries, with ante-grade continuity between RV and main PA.
- Patent uniform caliber LPA & proximal RPA.
- Markedly hypoplastic RPA branch measuring 0.3 cm.
- No MAPCAs noted. Small ASD.
- Double SVC with Lt SVC drain into dilated coronary sinus.
- Normal origin of the coronary arteries.



The diagnosis was high suspicious of Alagille syndrome :

- Alagille syndrome is an autosomal dominant disorder associated with abnormalities of the liver, heart, skeleton, eye, and kidneys and a characteristic facial appearance.
- Caused by mutations in the gene, JAG1 (95%) or Notch2.
- Both genes make proteins that are involved in human fetal development.
- Chromosomal analysis and DNA sequence analysis for mutations within the JAG1 gene are needed to confirm diagnosis.



- **The important ? Now**

- What is your next step ?

- Follow Up with medical management.....
- Cardiac catheterization and re-evaluation.....
- Surgical intervention.....

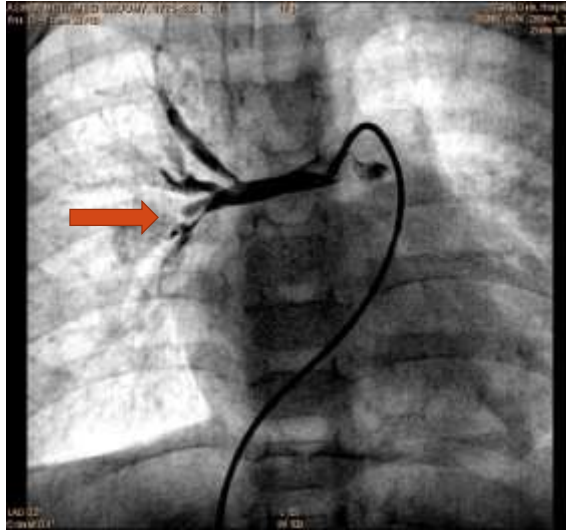
The clinical suspicion of peripheral pulmonary stenosis usually requires cardiac catheterization to confirm the diagnosis as well as to determine the severity and exact anatomy . So, Cardiac catheterization and re-evaluation.....

Pre cath Laboratory data

- All data were within normal range for age:
- CBC, RFT, LFT, Na, K, ABG,RBS.
- Only CRP that was over rang:
44 mg/L for which the patient received anti-biotic, one week later it become 6mg/L .

- Control angiography was taken for: Haemodynamic & angiographic assessment that showed:
- Persistent LT SVC that drain into dilated coronary sinus.

- Selective right pulmonary artery injection showed nearly sub-total stenosis of the origin of right lower lobe pulmonary branch, with PG between MPA & RPA about 37 mmHg.
- and non significant mid right PA stenosis about 20-30%.

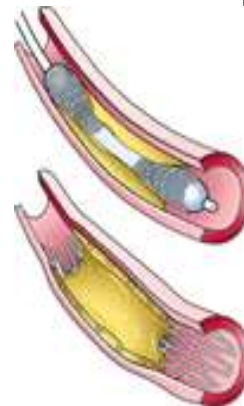


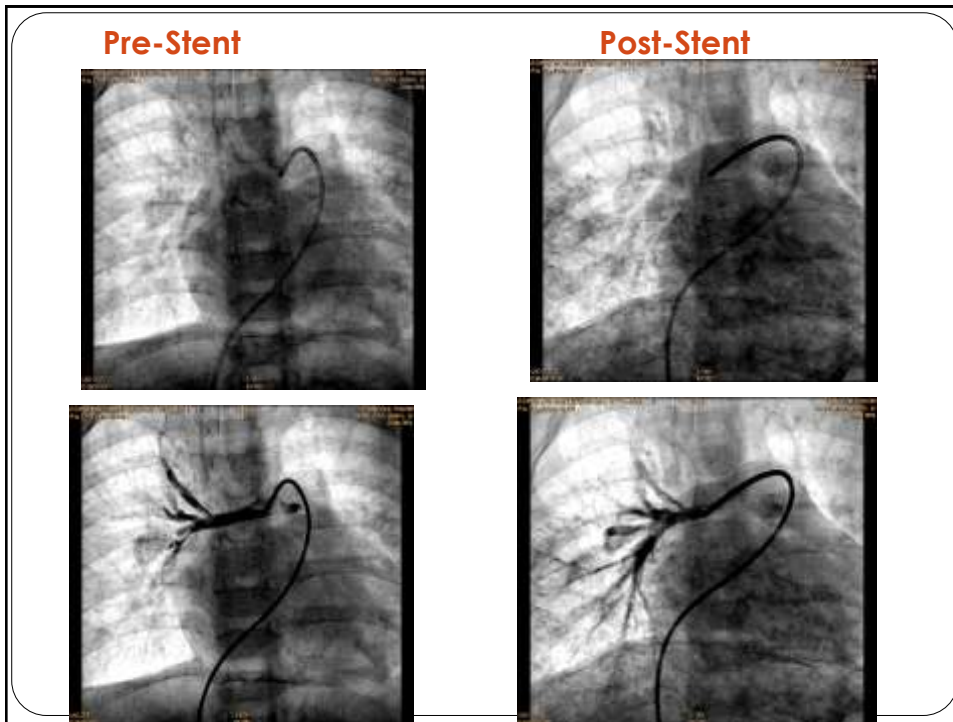
- **The Second important ?**

- To be continue with stent deployment ?
- To abort the procedure & continue Medical?
- Or to refer to Surgery ?

To be continue with stent deployment

- **Took the measurement of:**
 - Maximum proximal & distal normal caliber.
 - The length between them.
 - The diameter & length of stenotic area.
 - Long, stiff wire, as distal as possible.
 - Accordingly choose the stent and deployed it.





- The stent was Coroflex balloon expandable chosen according to the distal end of the lesion, it was 4.5X14mm.
- The patient took heparin in full therapeutic dose for BW (100mg/kg), as well as antibiotic and clopidogril.
- During recovery from anesthesia she developed SVT that was not sustained & gave a good response to B blocker .

Pulmonary artery stenosis

- **Congenital**
 - ♥ Hypoplasia of pulmonary arteries
 - ♥ Small branches underdeveloped
 - ♥ Supravalvar pulmonary stenosis
 - ♥ Multiple stenosis
 - ♥ Circumscribed stenosis

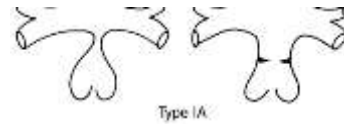
- **Association with other CHD.**

- **Syndromes:** (Williams, Noonan, Alagille): natural PA stenoses (multiple & peripheral)

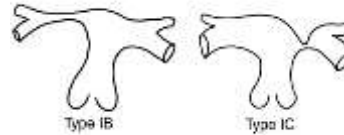
- **Acquired in patients with repair of:**

- ♥ Tetralogy of Fallot
- ♥ Pulmonary atresia
- ♥ Post trunk repair
- ♥ Post Glenn
- ♥ Arterial switch

Type I Involves a single stenosis of the main, right, or left pulmonary arteries, without peripheral branch involvement.



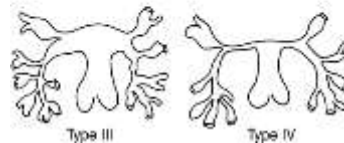
Type II Involves stenosis at the bifurcation of the pulmonary trunk extending into the origins of the right and left pulmonary arteries, without peripheral branch involvement.



Type III Involves multiple stenoses of the peripheral pulmonary artery branches, without central involvement.



Type IV Involves a combination of central and peripheral pulmonary artery stenoses.



Gay & Oram et al 1964

Comprehensive management of branch pulmonary artery stenosis.

- Balloon dilation
 - * High pressure
 - * Cutting balloon
- Stent placement
- Needle or RFA perforation & BD/ stenting (for complete occlusion)
- A combined transcatheter and surgical approach is essential for many patients with PA stenosis, particularly in complex forms of tetralogy of Fallot.

Bacha et al 2001

Stent Complications

- Death
- Rupture of vessel
- Stent thrombosis
- Stent dislocation
- Balloon rupture
- Dissection of vessel
- Aneurysm formation
- Stent fracture
- Intimal proliferation

- **Reviewing the literatures:**

- **Ziyad M. Hijazi** studied **26** patients underwent an attempt at stent implantation (11 in Boston; group 1 and 15 in Riyadh; group 2).
- PBS were either: post surgical repair of tetralogy of Fallot, after Fontan operation, native BPAS, or Williams syndrome and Alagille syndrome.
- A total of 37 stents were implanted successfully in 25 patients (16 in group 1 and 21 in group 2).
- The systolic gradient across the stenosis fell from a median of 40 ± 22 to 9 ± 6 mmHg, $p < 0.001$ and the diameter of the narrowest segment improved from 4.7 ± 0.4 to 10.8 ± 0.4 mm, $p < 0.001$.

- **Complications** included 2 patients where the balloon ruptured prior to full stent inflation,.
- Quantitative lung perfusion scan was performed pre and post stent deployment in 9 patients. This showed significant improvement of pulmonary blood flow in patients receiving unilateral stent.
- One patient developed significant restenosis secondary to intimal proliferation at the stent site, this was redilated successfully.
- **They conclude that** balloon expandable stents are safe and effective in relieving BPAS. Stents should be considered the treatment of choice for most patients with BPAS.

Copyright © 1995 American College of Cardiology Published by Elsevier.

- **Ralf J** published data that were prospectively collected using a multi-center registry (Congenital Cardiac Catheterization Project on Outcomes). All cases that included balloon angioplasty and/or stent implantation in a proximal or lobar PA branch position were included.
- Multivariate analysis was used to evaluate for independent predictors of ADVERS EVENTS and need for early re-intervention.
- Between February 2007 and December 2009, 8 institutions submitted details on 1315 procedures with a PA intervention. An AE was documented in 22%.
- Types of AE included vascular/cardiac trauma (19%), technical AE (15%), arrhythmias (15%), hemodynamic AE (14%), bleeding via endotracheal tube/reperfusion injury (12%), and **other** AE (24%).

Ralf et al 2011 American Heart Association.

- **Alcibar J Concluded that:**

- Implantation of the Palmaz stent is a useful procedure for the treatment of native or post-operative pulmonary stenosis. It is possible to apply it to hypoplastic and ostial pulmonary stenosis. They confirm the effectiveness of re-dilatation at mid term.

Rev Esp Cardiol. 1997 Mar;50(3):179-86

- While measure the gradients across the right ventricular outflow tract (RVOT), the pulmonic valve (PV) and the right and left branches of the pulmonary arteries, any gradient more than 16 mmHg is considered abnormal.

Heart defects, for everyone, February 26, 2010

- **Patel et al**, compared children who need reintervention and the mean time of reintervention after surgical branch pulmonary arterioplasty and branch PA stent placement between January 2008 and May 2012 at a single tertiary center 37 patients were included (surgery n = 18, stent n = 19). 50 % (9 of 18) of the surgery group and 5.3 % (1 of 19) of the stent group required reintervention ($p = 0.002$). Mean time to reintervention for the surgery cohort was 272 ± 162 days and for the single stent cohort it was 150 days.

Patel et al Pediatr Cardiol (2014)

Take home message

- Presentation of Alagille syndrome varies. Some patients are diagnosed after prolonged neonatal jaundice, and others may be diagnosed during evaluation for right-sided heart disease. Some individuals are diagnosed by careful examination after an index case is identified in the family.
- Angiocardigraphy is the best tool in the diagnosis of peripheral PA stenosis. The exact location, extent, and distribution of the lesions can be easily visualized with selective injections proximal to the site of obstruction.
- Branch pulmonary artery stenting is effective and feasible treatment option for BPS

THANKS FOR YOUR ATTENTION