



Coarctoplasty & Stenting in a case of VSD: A clinical Dilemma

By

Islam Galal Ismail , MD

Lecturer of Cardiology



Introduction

Association among congenital cardiopathies may be:

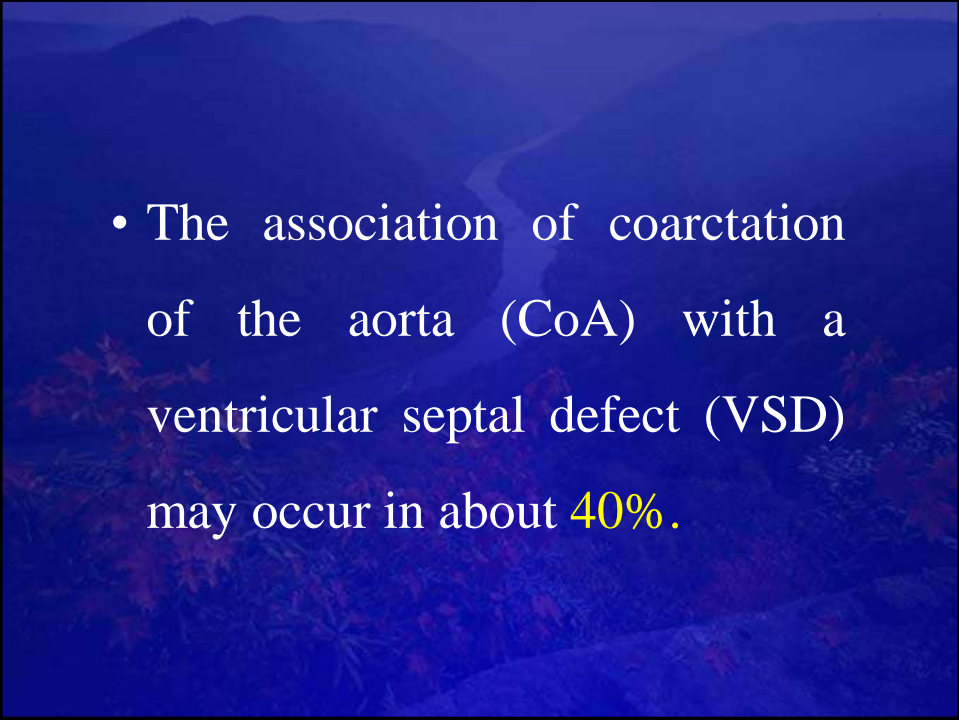
1. Accidental, i.e. VSD with coarctation.
2. Obligate, i.e. tricuspid atresia with ASD
3. Secondary to hemodynamic disturbances due to the primary cardiopathies, i.e. ASD and mitral valve prolapse.
4. Secondary to alterations of anatomical structures, whose embryological origin is similar, i.e. aneurysm of the sinus of Valsalva with aortic insufficiency or VSD.

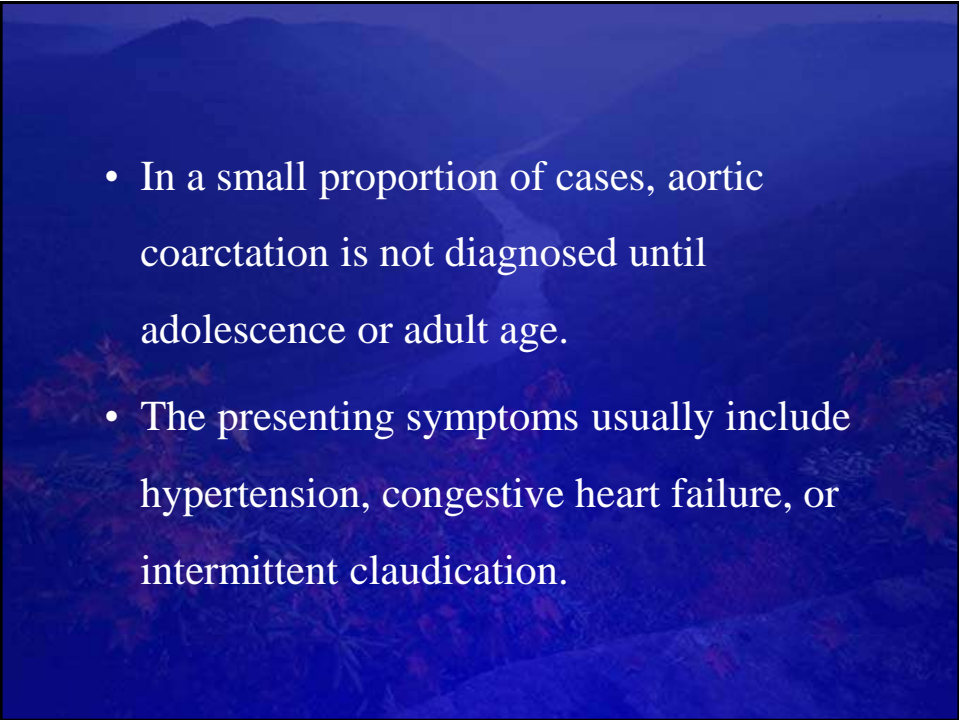
- The anatomical and physiologic size of one could contribute hemodynamically to the other and the reverse is true.

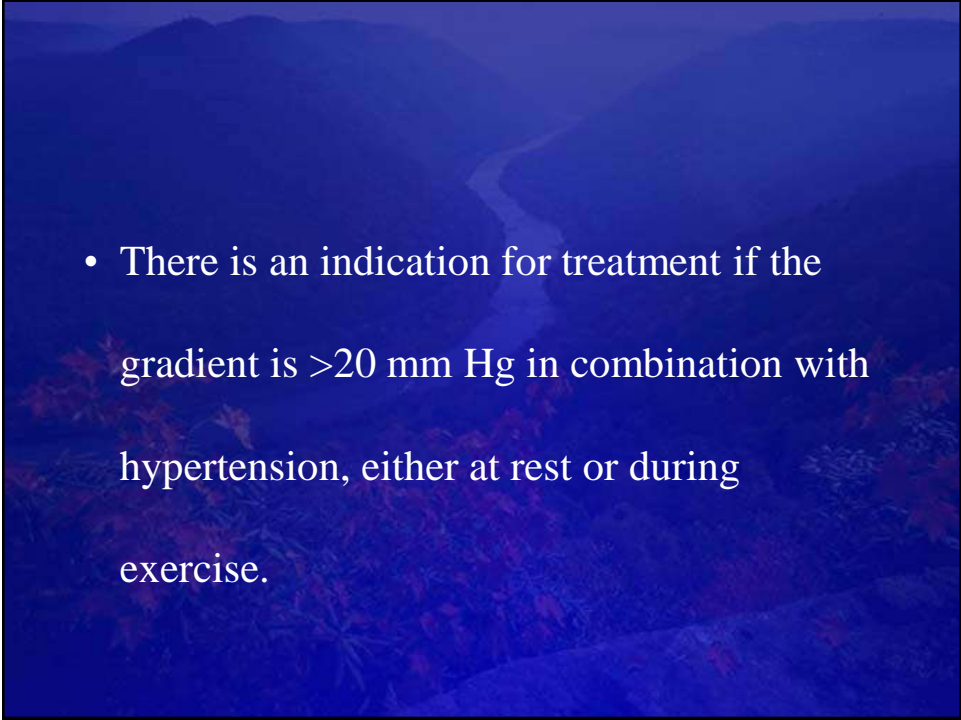
Coarctation

- Coarctation of the aorta (CoA) is a common form of congenital heart disease, which may be diagnosed over a wide range of ages and with varying severity.

- It accounts for 5% to 8% of all CHD and may be associated with additional cardiac abnormalities including:
 - **Bicuspid aortic valve**
 - **VSD**
 - **PDA, and**
 - **More complex cardiac malformations.**

- 
- The association of coarctation of the aorta (CoA) with a ventricular septal defect (VSD) may occur in about 40%.

- 
- In a small proportion of cases, aortic coarctation is not diagnosed until adolescence or adult age.
 - The presenting symptoms usually include hypertension, congestive heart failure, or intermittent claudication.

- 
- There is an indication for treatment if the gradient is >20 mm Hg in combination with hypertension, either at rest or during exercise.



The case

المركز التخصصي للقلب بالشرقية
 (مركز القلب - ش. الجلاء)
 (مركز جميع التخصصات)

Echocardiography Report

Name: Asmaa Gamal Reada Age: 22 Years Date: 22 August 2016
 Referred by: Prof. Dr. Ahmed Shalabi

2D AND M-MODE MEASUREMENTS:

Ao root	25	(23-27)mm	LV IVD	47	(34-47)mm
LA	32	(29-40)mm	LV IVD ₂	29	(21-30)mm
Ao dia.	17	(15-23)mm	E.E.	56	60-70%
MVD	25	(20-27)mm	P.E.	48	55-65%
DVT	5	(5-11)mm	MVA	Normal	≥4 cm ²
PWT	8	(5-11)mm	EPV	Normal	≤8 mm

DOPPLER AND CFM STUDY:

CF valve	CF valve & JVC	Approach	Acquisition	Max. V. (m/s)	Max. STV	Reverse
Mitral	Normal	Trichal	Aortic	---	---	Normal
Trikuspid	Normal	Mitral	Pulmonary	1.18	Normal	No

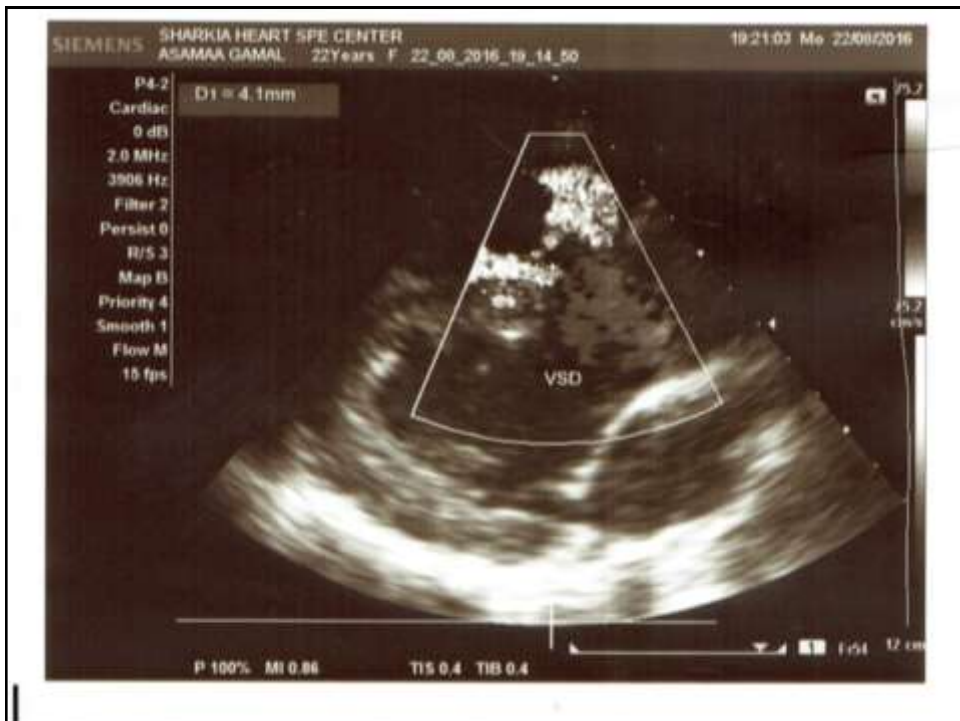Observations:

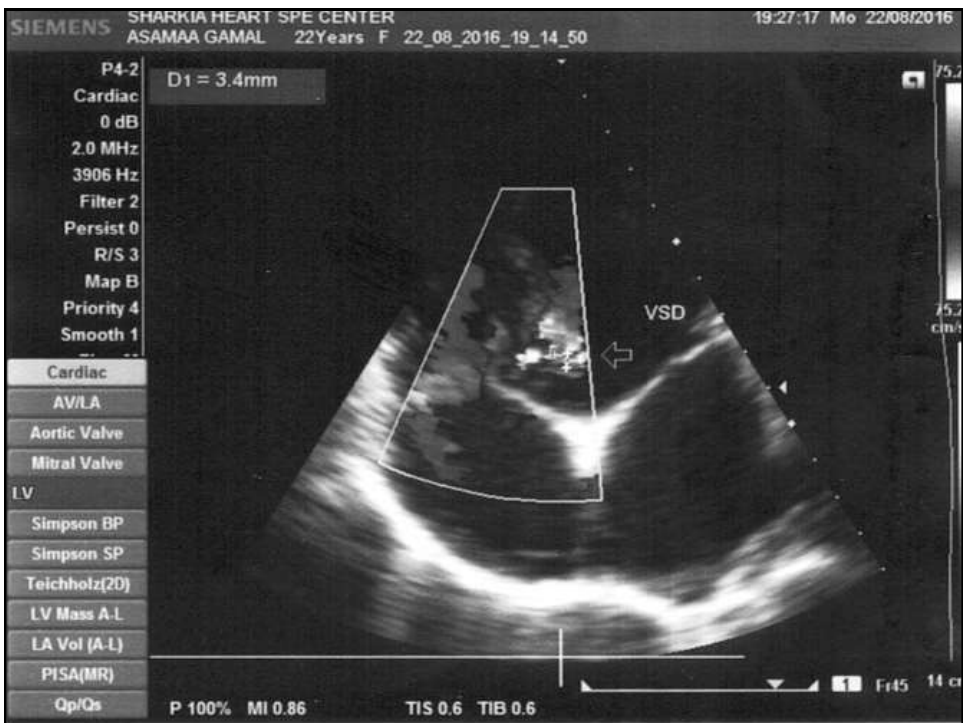
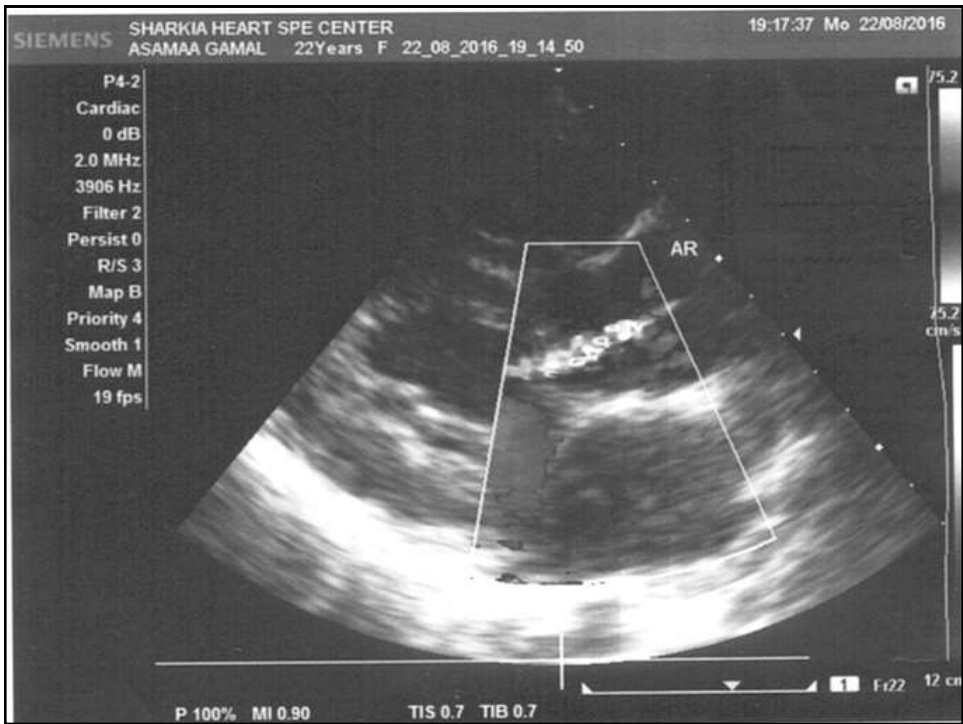
- Sinus rhythm.
- Ventricular, atrioventricular and ventriculoarterial concordance.
- Small subaortic perimembranous VSD with muscular extension measuring 4 mm with left to right shunt. PG across the ventricles.
- Mitral valve leaflets are normally thick with normal healing in to LA cavity.
- Normal PA pressure.
- Normal LV internal dimensions, wall thickness and function.
- Intact interatrial septum.
- No aortic coarctation.
- Free pericardium.

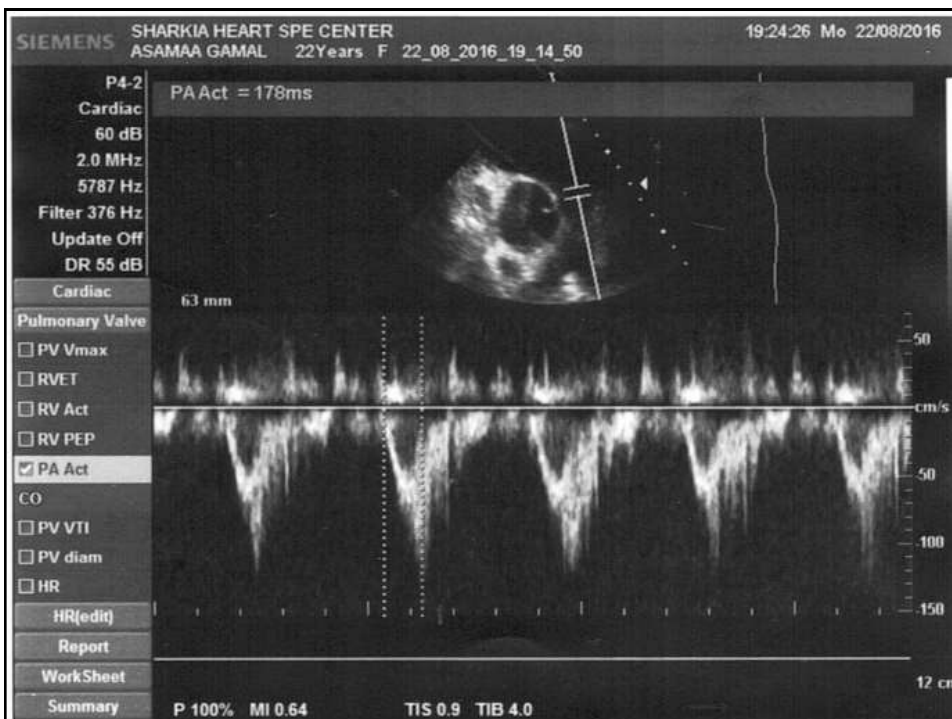
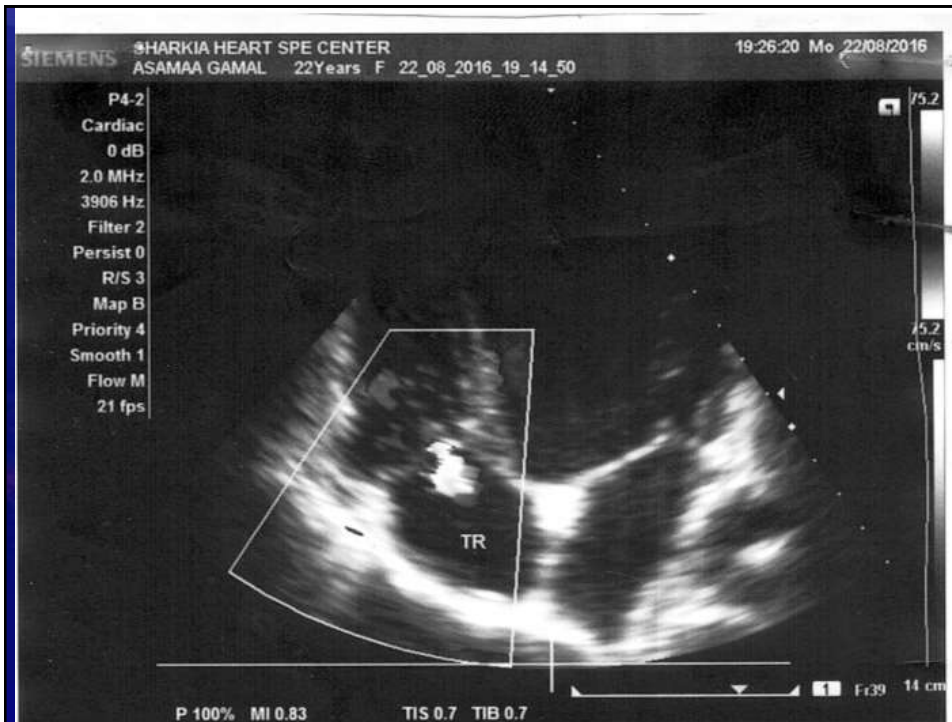
Conclusion: Congenital heart disease:
 Small subaortic perimembranous ventricular septal defect with muscular extension

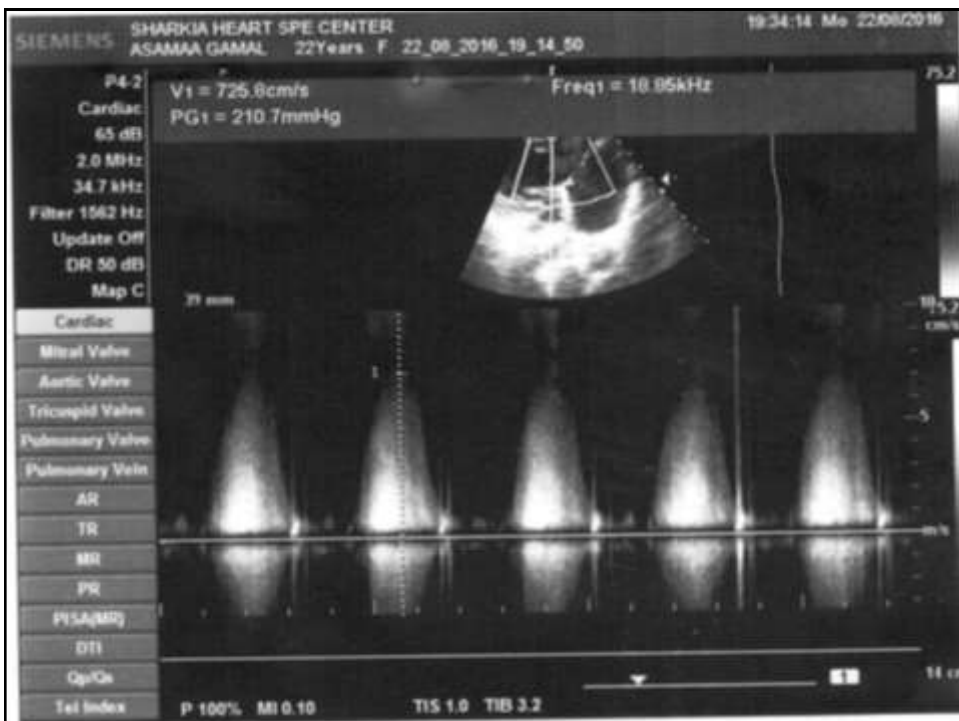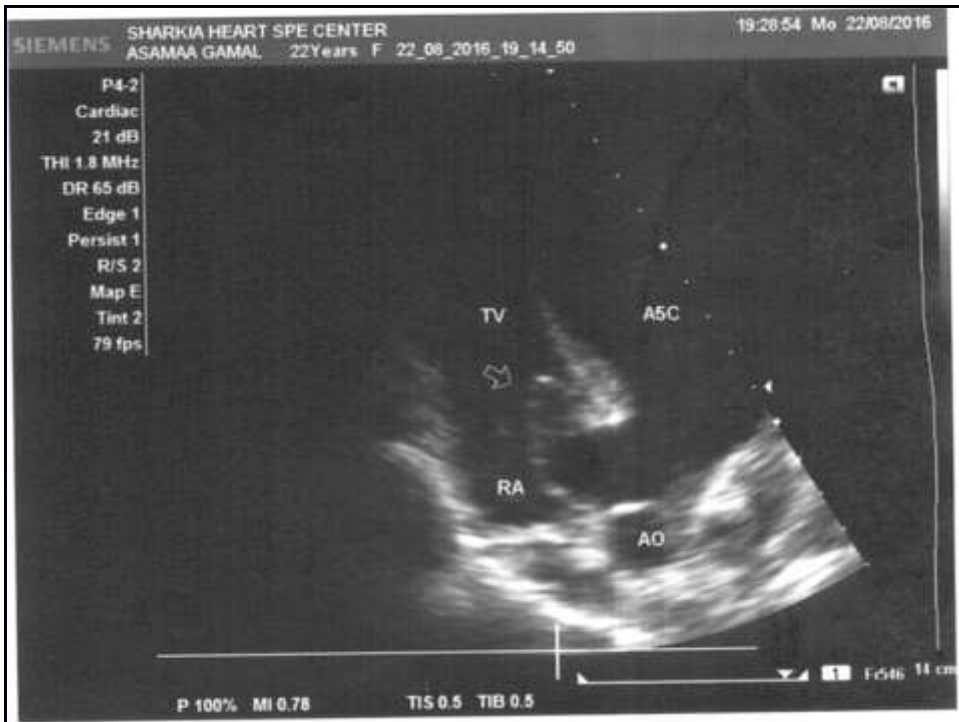Signature
 Dr. Aysan Tawfeeq
 (MD Cardiology)

الطبيب: أ.م.م. عصير الطويران - ش. الجلاء
 ٢٢٠١٤٩٦







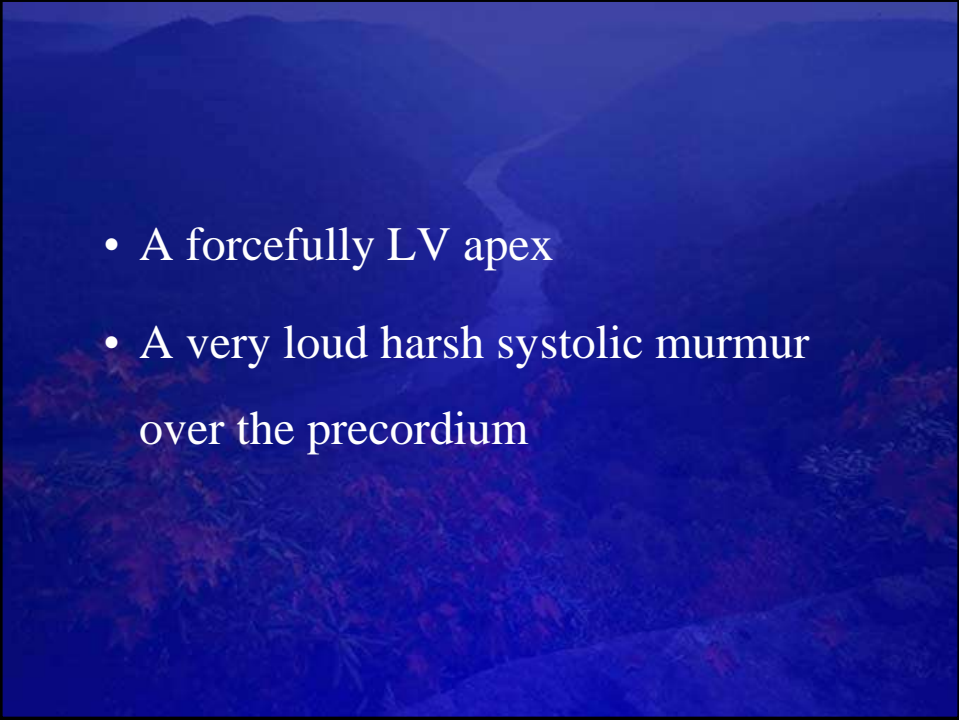


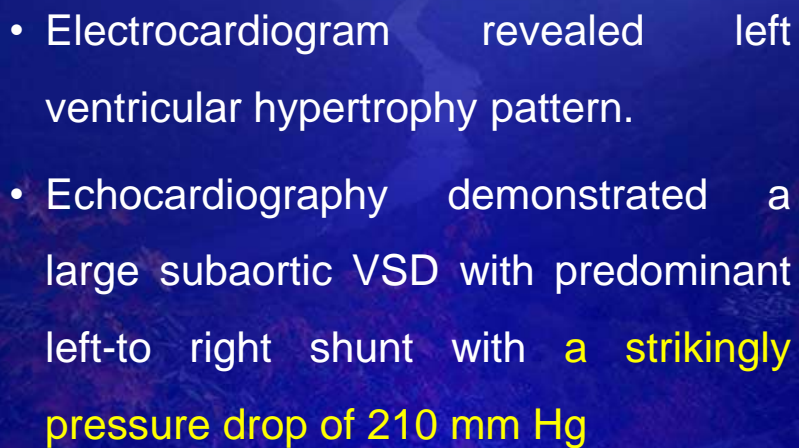
Patient's history

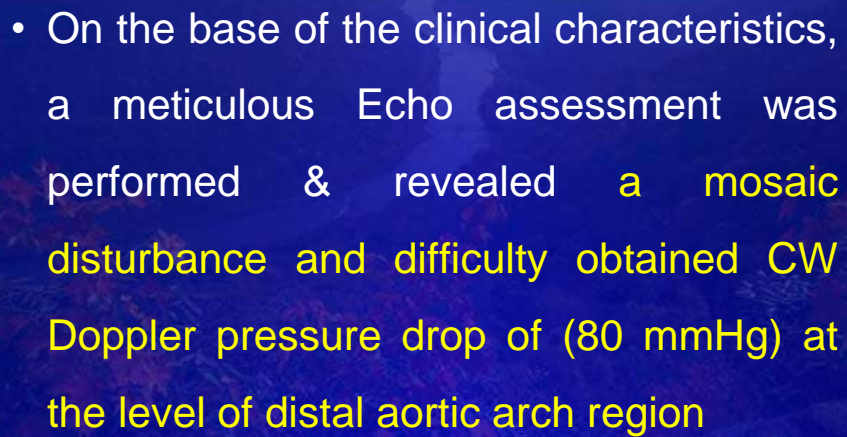
- A 23-year-old female presented with lower limb claudication and effort intolerance of the last 9 months.
- She was known to have congenital heart disease, consisting of VSD since childhood.

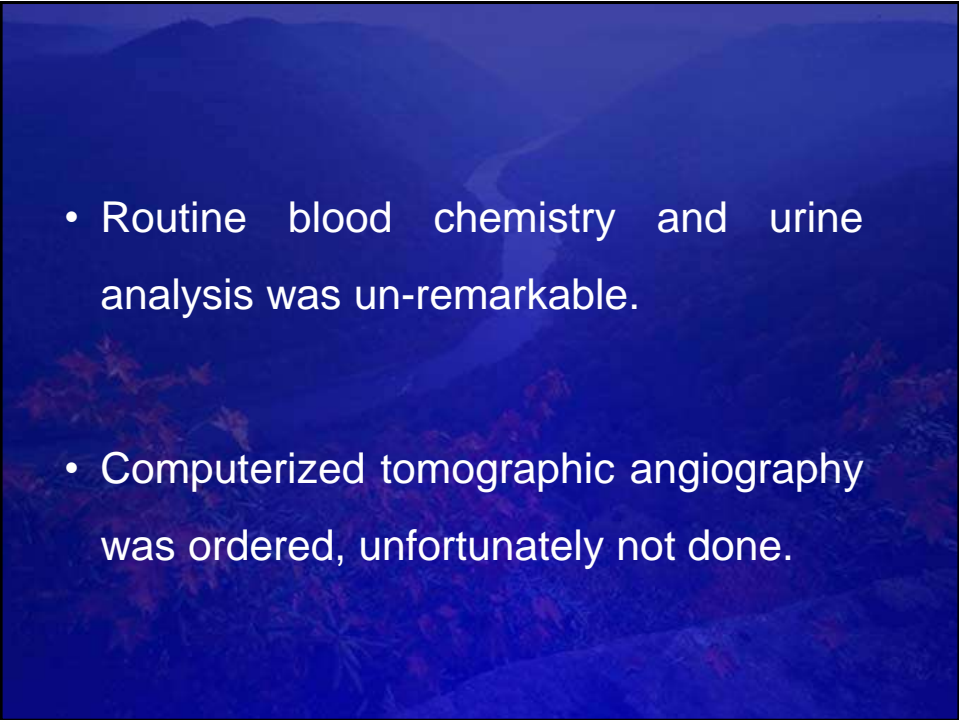
On physical examination:

- Bp in the right upper limb was 170/90 mm Hg.
- A radio-femoral delay was apparent and a pressure difference of 80 mm Hg was noted between the upper and lower extremities.
- The pulsations in the LLs were faint, *while interestingly*, left radial pulse was nearly not palpated.

- 
- A forcefully LV apex
 - A very loud harsh systolic murmur over the precordium

- 
- Electrocardiogram revealed left ventricular hypertrophy pattern.
 - Echocardiography demonstrated a large subaortic VSD with predominant left-to right shunt with a strikingly pressure drop of 210 mm Hg

- 
- On the base of the clinical characteristics, a meticulous Echo assessment was performed & revealed a mosaic disturbance and difficulty obtained CW Doppler pressure drop of (80 mmHg) at the level of distal aortic arch region

- 
- Routine blood chemistry and urine analysis was un-remarkable.
 - Computerized tomographic angiography was ordered, unfortunately not done.

Clinical dilemma

- Whether to go ahead with coarctoplasty and stenting or not as there was the theoretical possibility that right-to-left intracardiac shunting, or
- Devise closure of VSD, or
- **Intervention for both.**

- As she had significant leg claudication, restrictive VSD and no signs of pulmonary hypertension, *Ultimately we decided to go ahead with coarctoplasty and stenting.*

Aortic Analysis

- The necessary information to plan the stenting was obtained through evaluation of the aortographic data.
- At first, we evaluated the entire aorta, which provided a rapid assessment of the main anatomic features

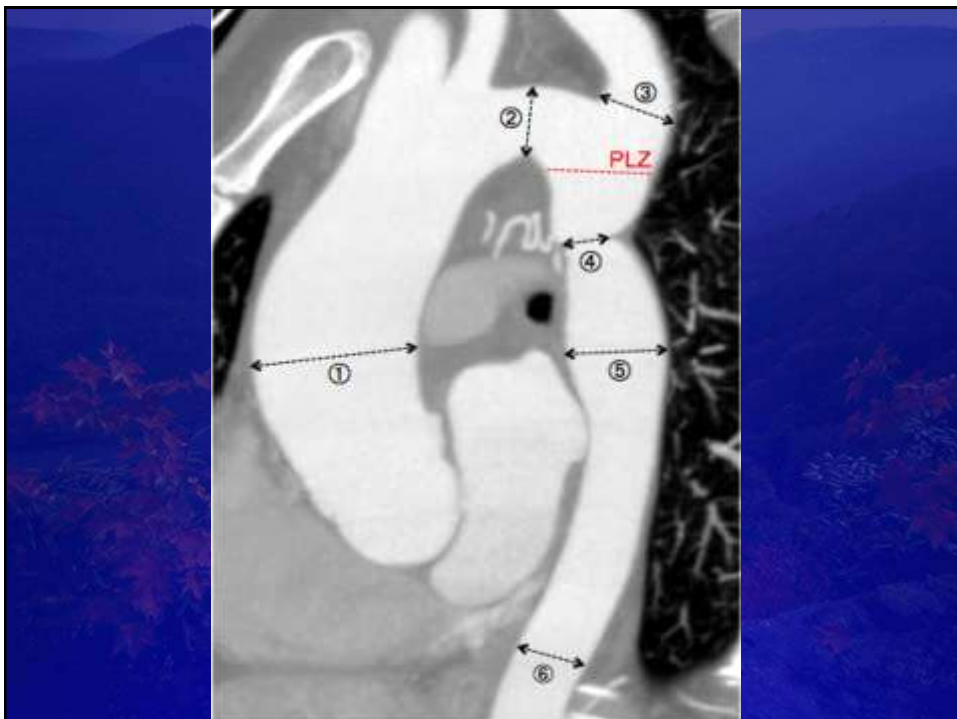
Aortic Analysis.....

- Focus on the severity and localization of the CoA and its position in relation to the neck vessels and distal aortic arch.
- Evaluation of the quality of the aortic proximal and distal landing zone focusing on the presence of calcific and atherosclerotic lesions and poststenotic dilatation.

Aortic Analysis

In fact, all these conditions may:

1. hamper stent sealing,
2. Lead to wall apposition, and
3. lead to increased aortic fragility.



Stent diameter

- The stent diameter must not exceed the diameter of the descending aorta at the level of the diaphragm, in order to avoid aneurysm formation or rupture.
- Stent diameter is selected based on the diameter of the proximal aorta – mainly transverse or distal arch diameter – or 1–2 mm larger.

Stent diameter.....

- Another approach is to use the average of the aortic isthmus (or transverse aortic arch) and the descending aorta at the level of diaphragm.
- The ratio of expanded stent diameter to that of coarcted segment is frequently around 2–3.5 and should be < 3.5

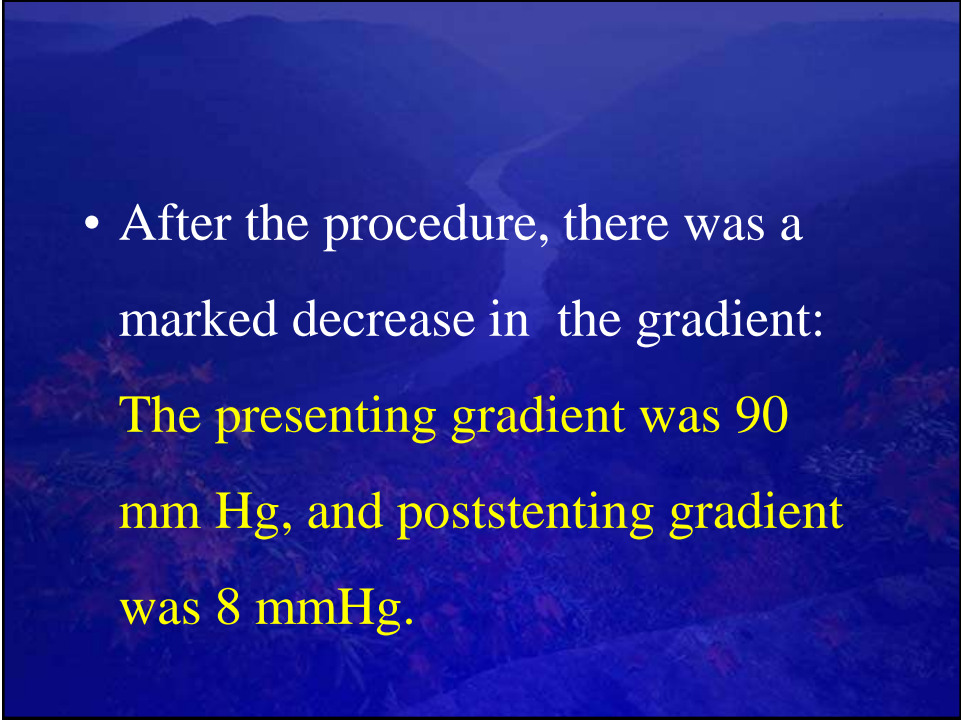
- Balloon diameter was selected to match the size of the distal aortic arch at the origin of the left subclavian artery.
- The ratio between the CoA diameter and the descending aorta at the level of the diaphragm in systole was recorded to assess the severity of the lesion and immediate angiographic results.

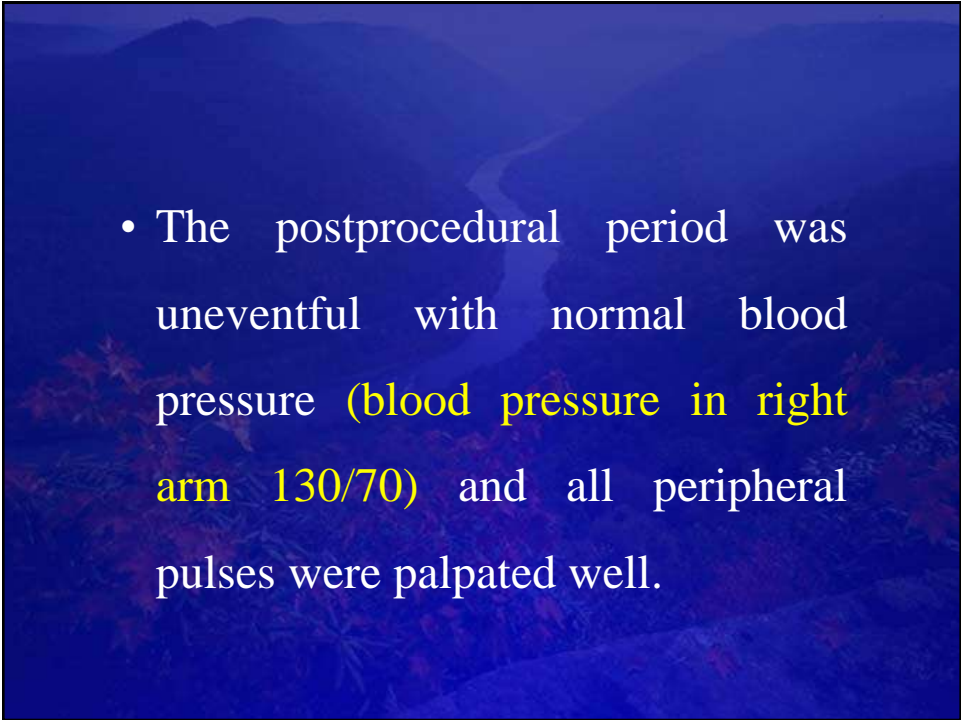
- The stent implantation procedure is classically considered successful if the residual gradient is ≤ 20 [some: if < 10 mmHg], with an improvement in diameter to $\geq 90\%$ of the normal adjacent aortic arch vessel

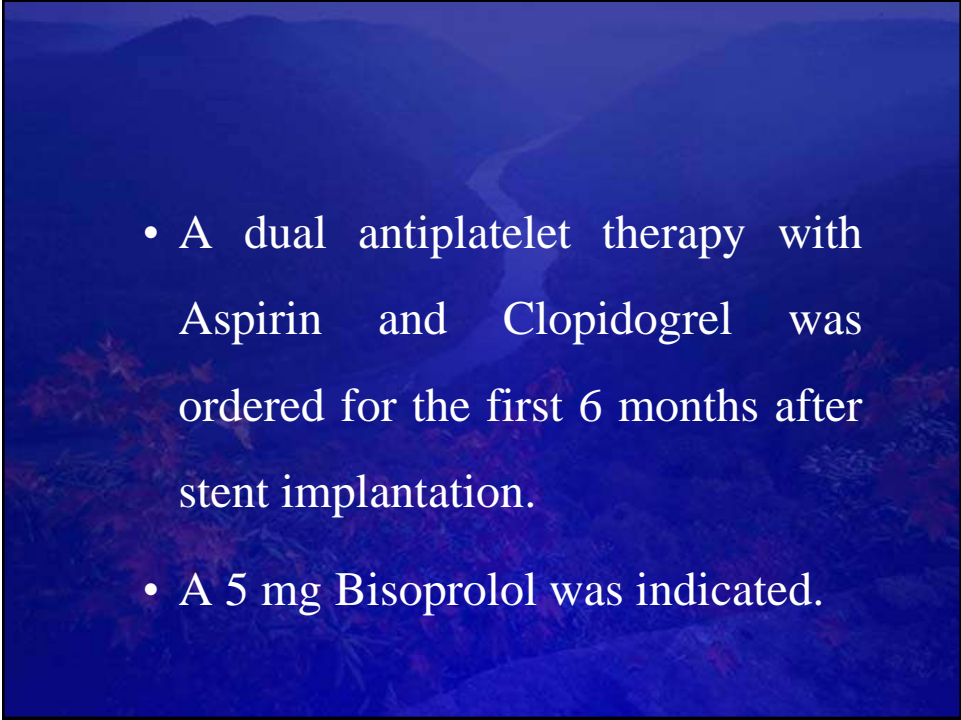
The procedure

- A 14 F sheath was placed in the right femoral artery. An initial angiogram revealed a blind end at the level of the coarctation
- The lesion was predilated with a 14 mm **CRISTAL** balloon, after which stent deployment was carried out using a balloon mounted 33 mm

- The stent was advanced along the stiff guidewire and across the CoA.
- A starting position was achieved through a aortography.

- 
- After the procedure, there was a marked decrease in the gradient:
The presenting gradient was 90 mm Hg, and poststenting gradient was 8 mmHg.

- 
- The postprocedural period was uneventful with normal blood pressure (blood pressure in right arm 130/70) and all peripheral pulses were palpated well.

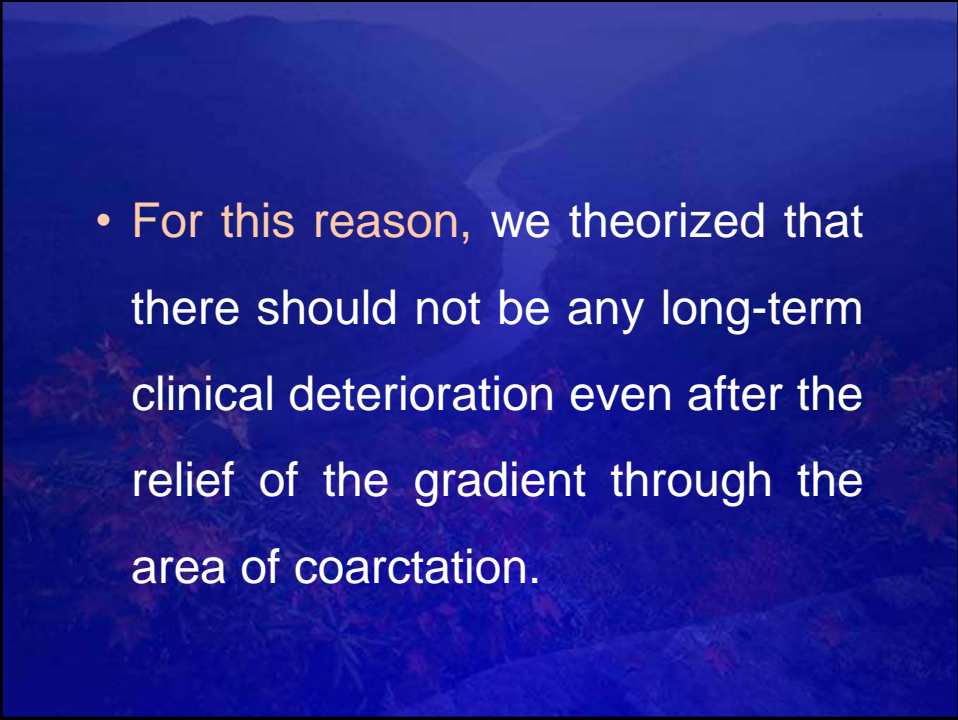
- 
- A dual antiplatelet therapy with Aspirin and Clopidogrel was ordered for the first 6 months after stent implantation.
 - A 5 mg Bisoprolol was indicated.



The comment

- The concern in this case was the possibility of clinical deterioration after relief of the gradient across the coarctation as the right-to-left intracardiac shunt could occur as a consequence of reducing systemic ventricular outflow obstruction.

- Alternatively, we believed that RV pressure would not reach supra-systemic level *as the VSD was restrictive and careful examination revealed that there was a large aneurysm, with 2 defects [each 2, 3 mm]* .

- 
- For this reason, we theorized that there should not be any long-term clinical deterioration even after the relief of the gradient through the area of coarctation.

Three months later....

- Pulses were palpated well in all limbs
- Blood pressure:
 - Right arm: 130/75 mmHg
 - Left arm: 130/70 mmHg
- The following study was obtained:

