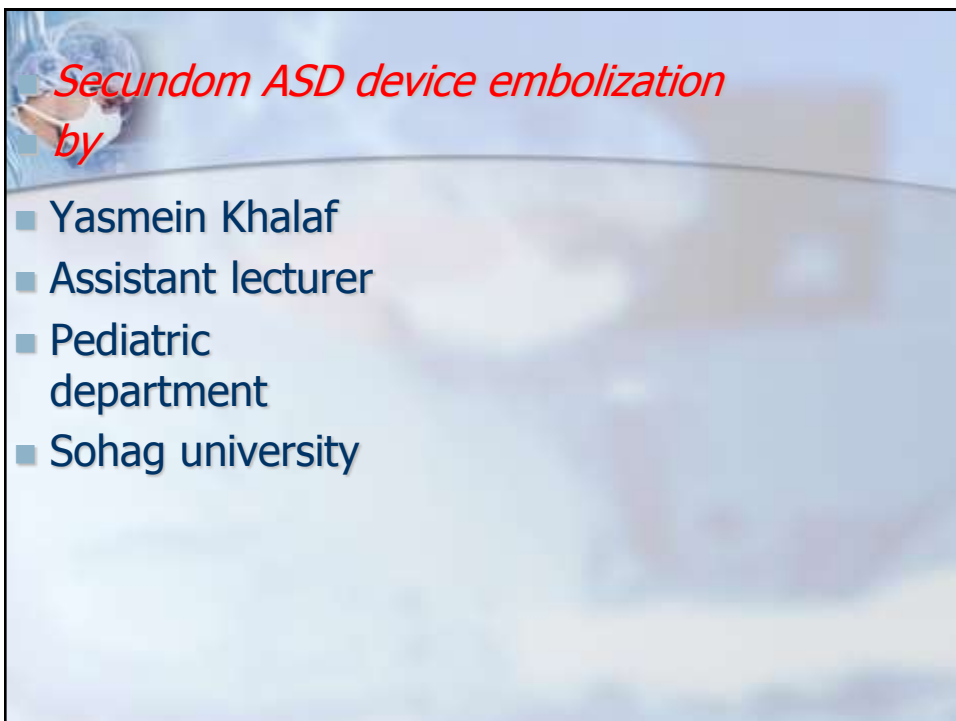
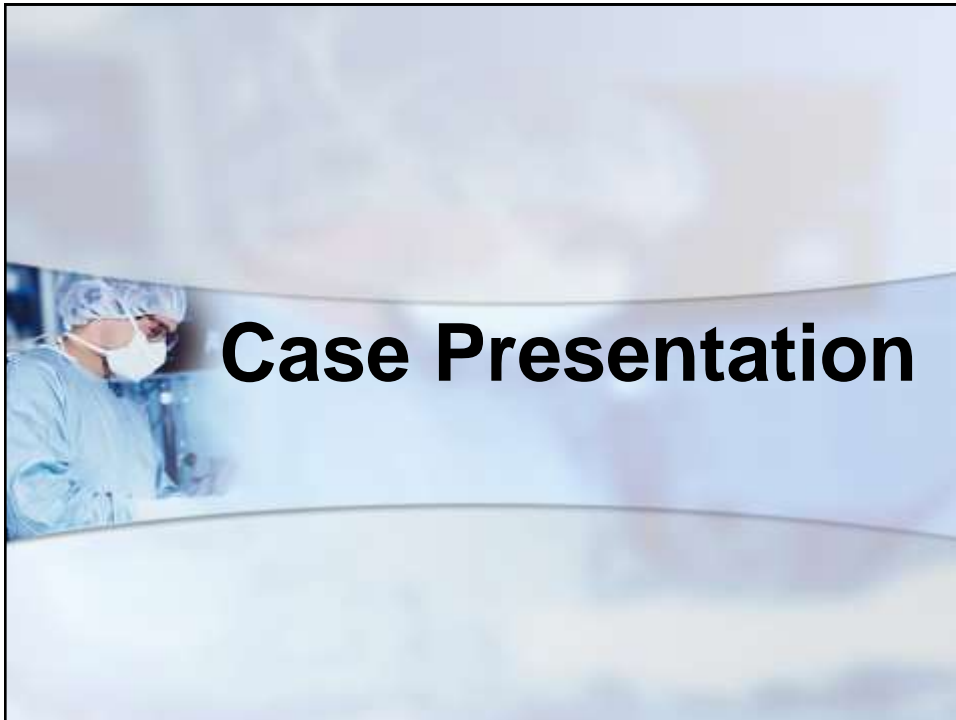


Personal History

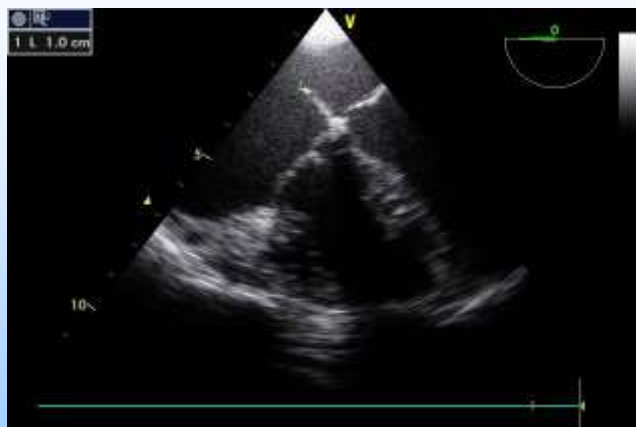- Male patient , 14 years old from sohag ,Patient was diagnosed to have secundum ASD byTTE,15mm with left to right shunt.
- Prepared for percutaneous closure of defect in our Cath lab.

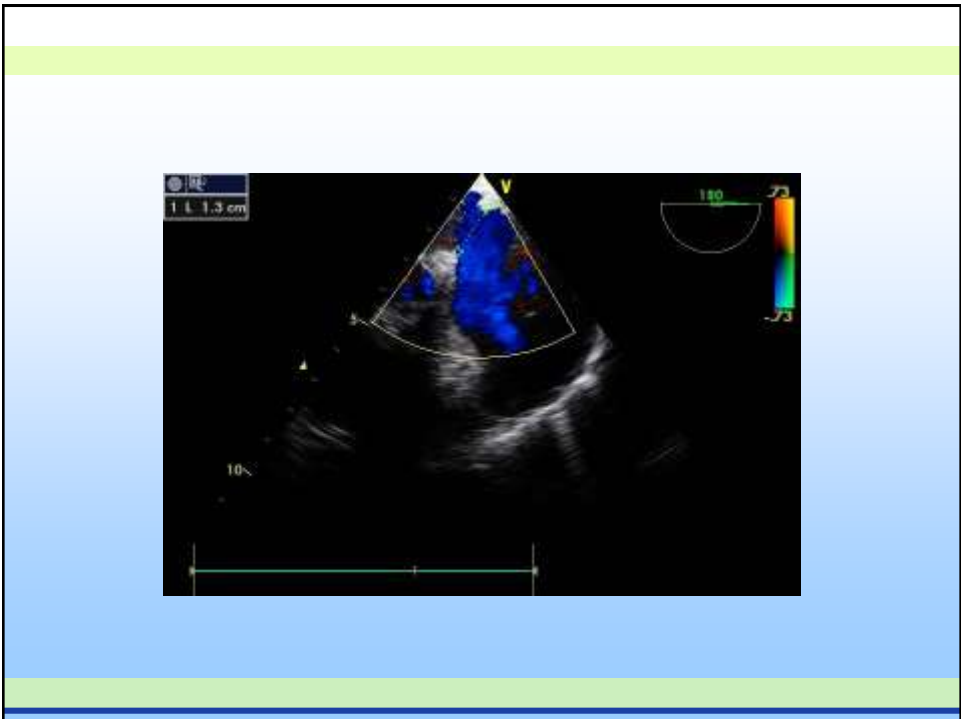
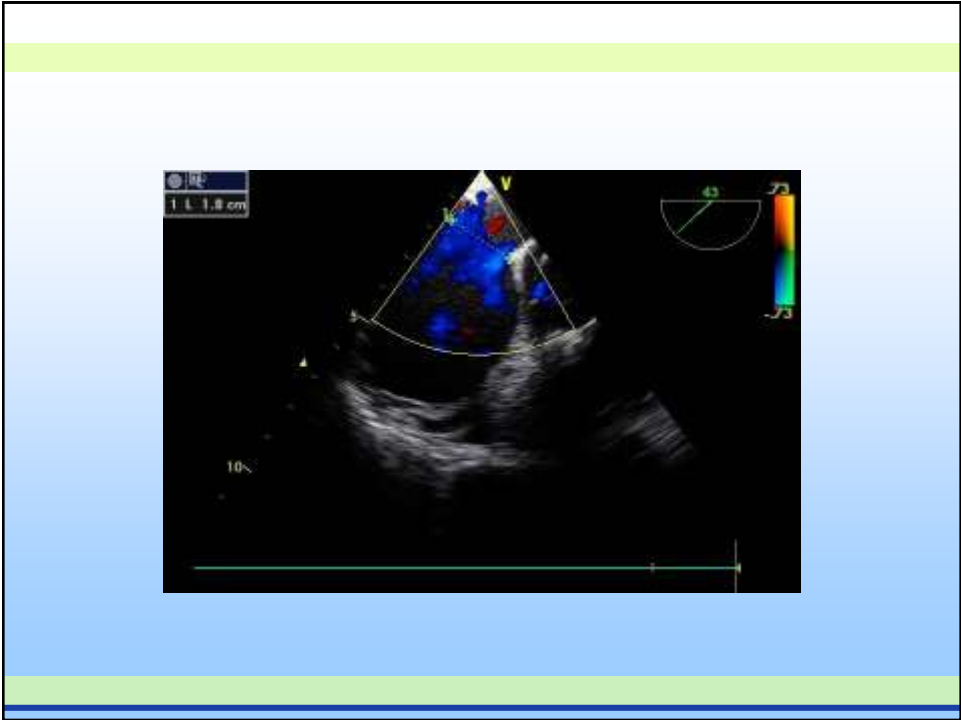
Echocardiography TTE

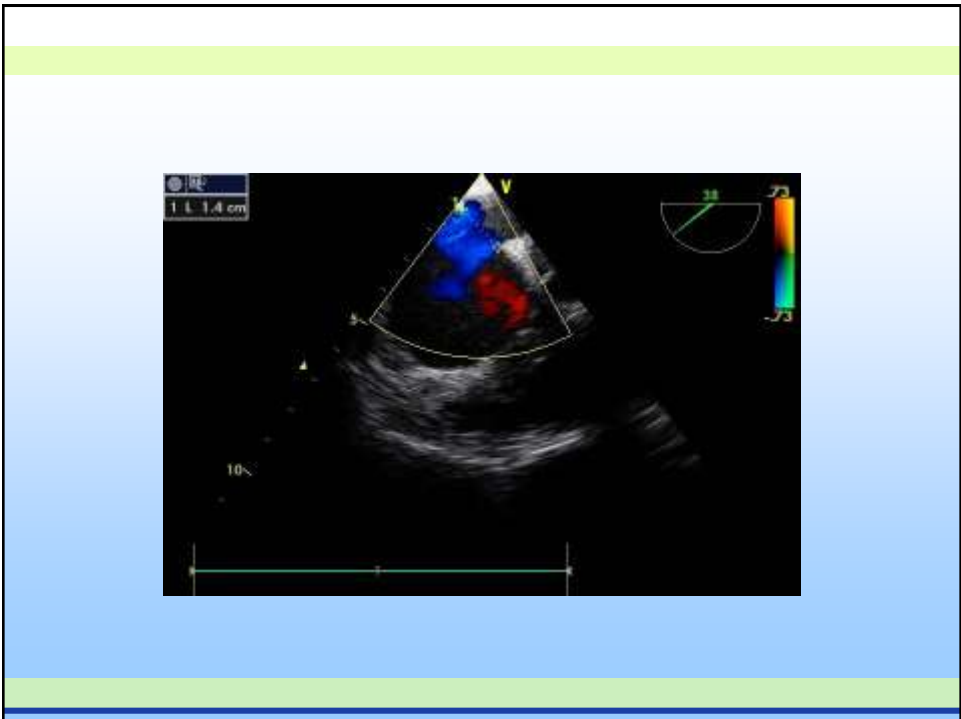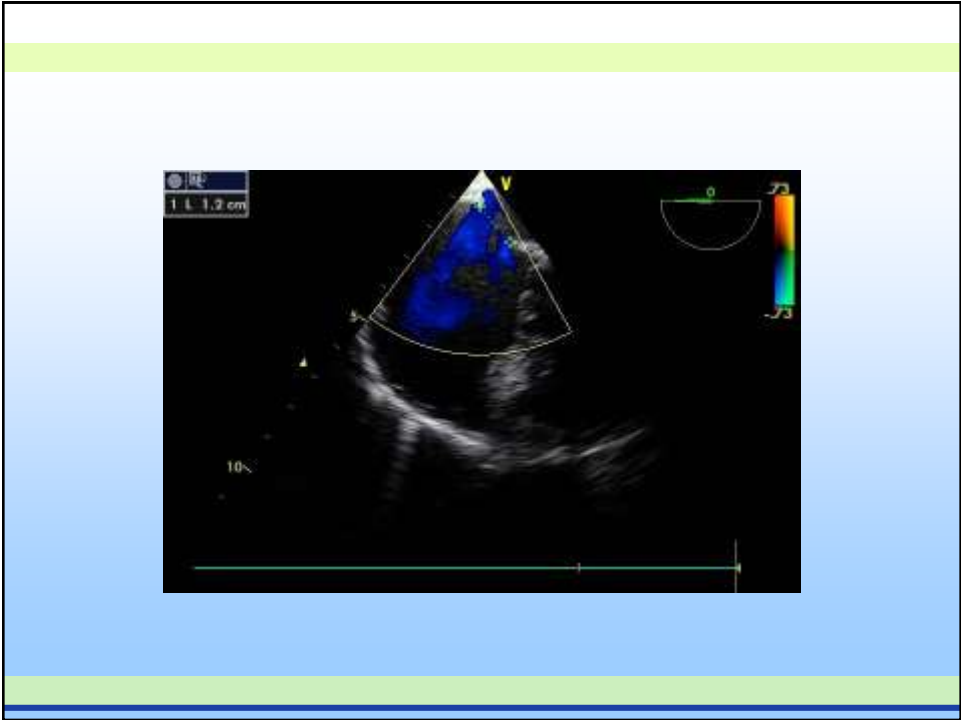
Secundum ASD diameter
15*17mm with left to right shunt.
Dilatation of RV
Deficient retro aortic rim
Other all rims were sufficient

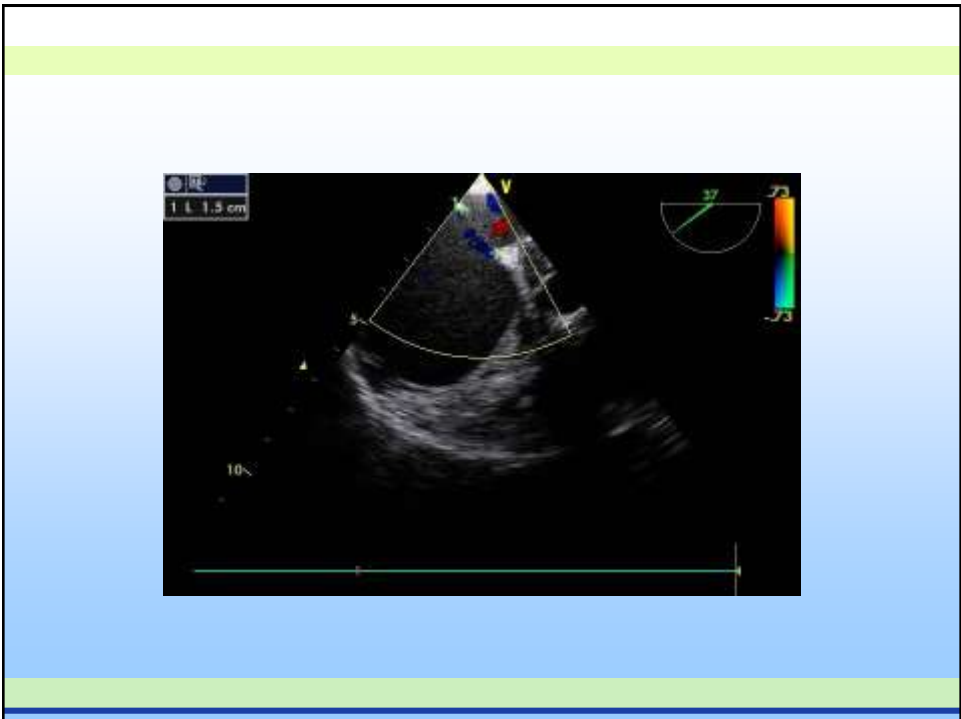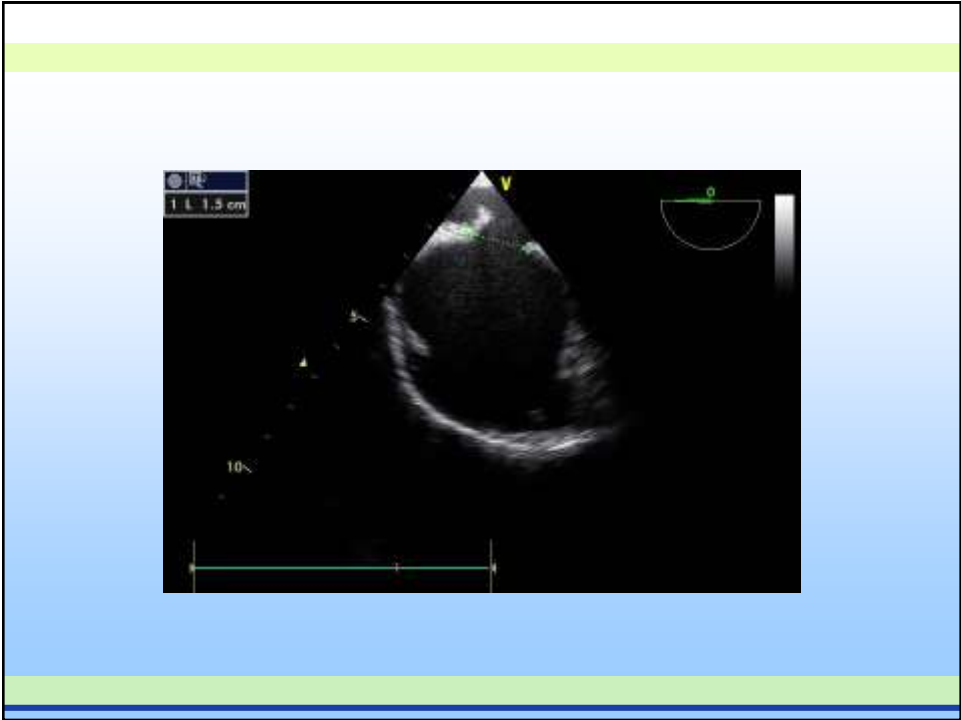
- Preoperative preparation done
- Pt underwent percutaneous device closure of defect after fulfilling criteria of procedure.
- **TEE**
- 4chamber view show size 15mm with left to right shunt ,preserved rims.
- Short axis view show

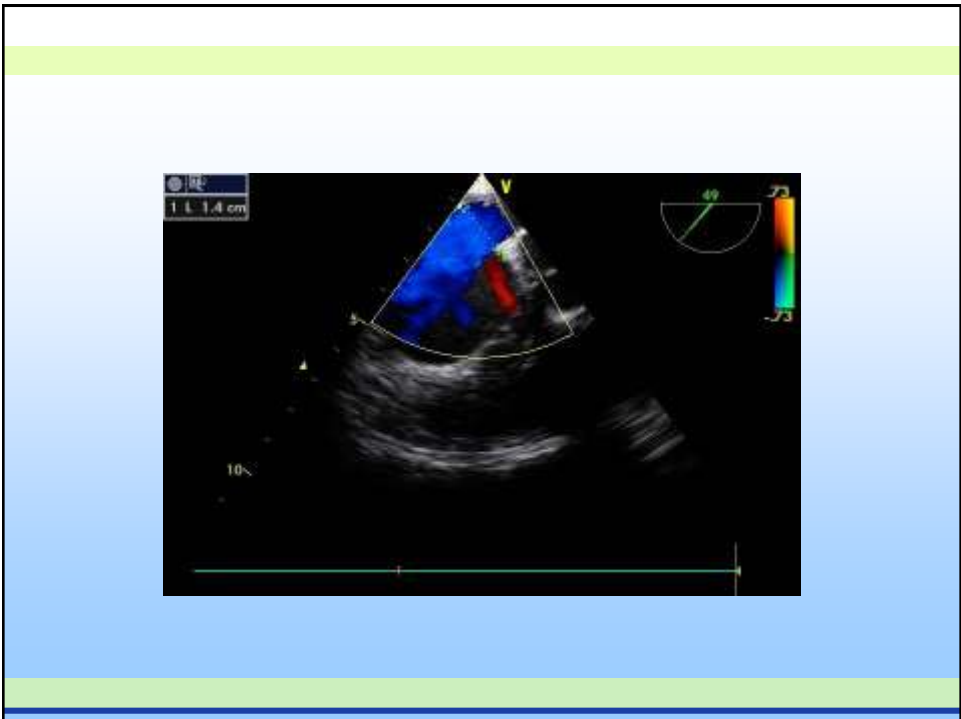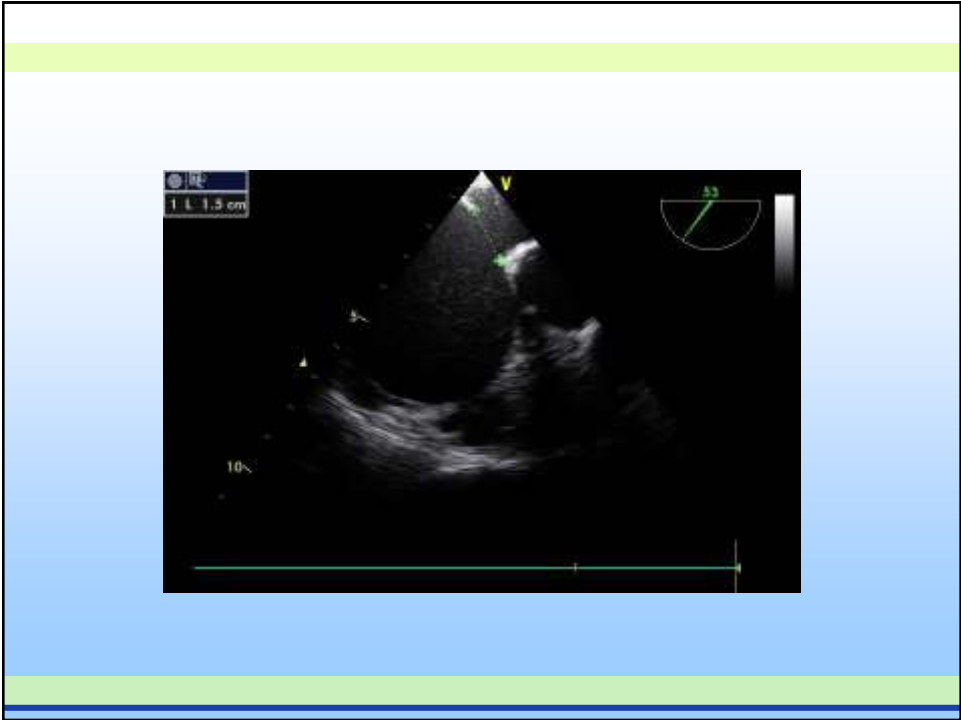
TEE BEFORE DEVICE











TECHNIQUE

- During deployment of device, recurrent prolapse of device was occurred several times through LUPV technique.
- Then deployment was done succesfully by Right upper pulmonary vein technique.

TEE AFTER DEVICE

- AFTER deployment of occluotec 21 septal occluder

First follow up echo TTE after deployment and release ????



- Device not in situ.
- Echo done show device embolized in RVOT.
- Patient was stable hemodynamically
- **When situation get worse?**

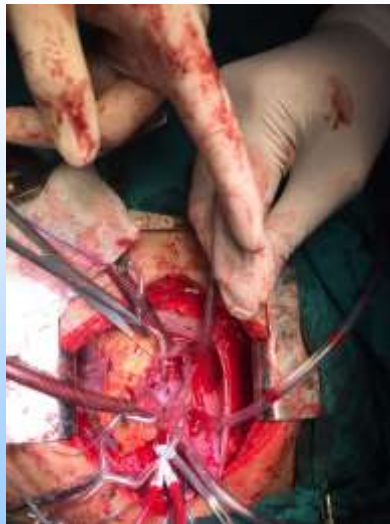Causes of embolized device in this patient

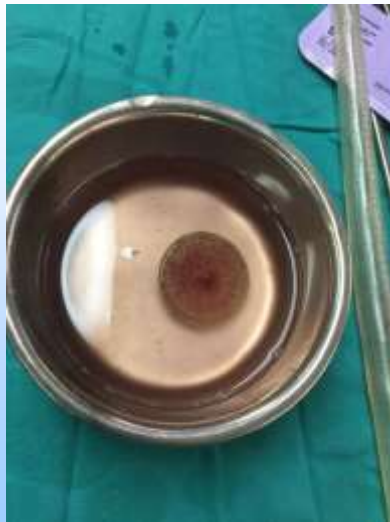
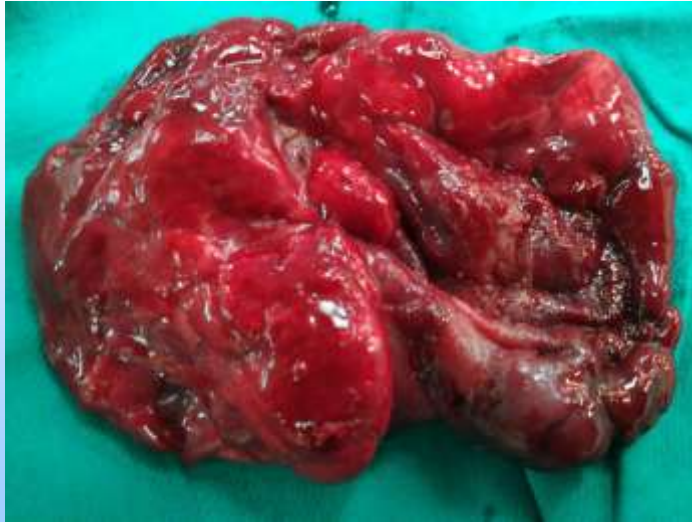- 1- under sized defect
- 2-insufficient rims
- 3-vigirous Minnesota
- 4-Malalignmet IAS
- 5-Thin ,floppy posterior portion of IAS (poster inferior rim)
- 6-small LA that cannot accommodate the device

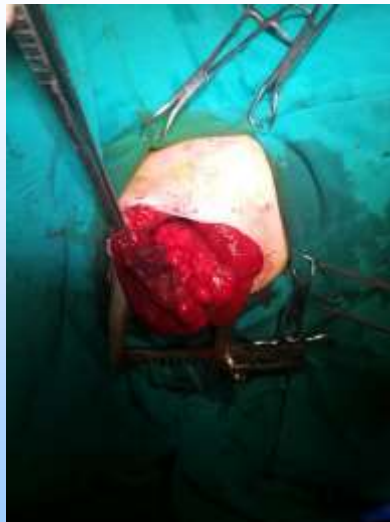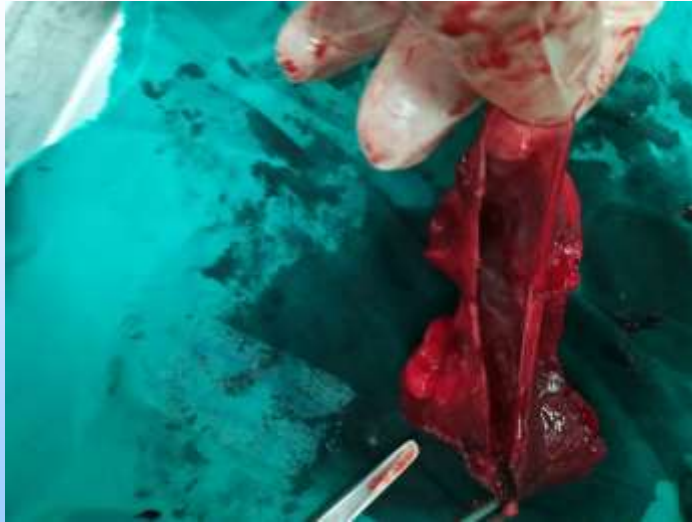
What will be the next step?

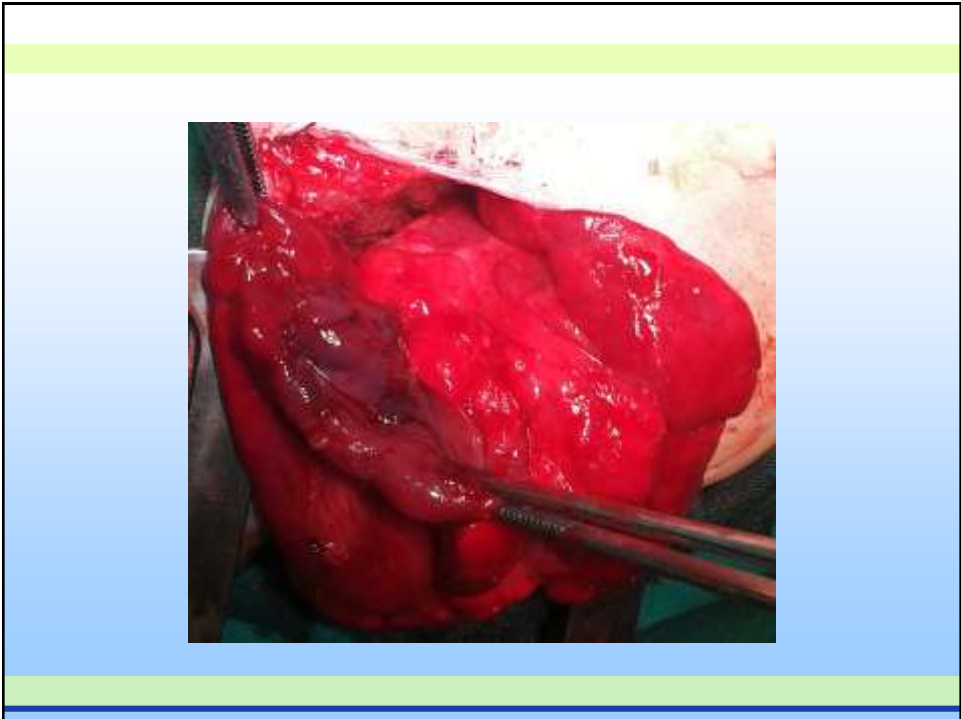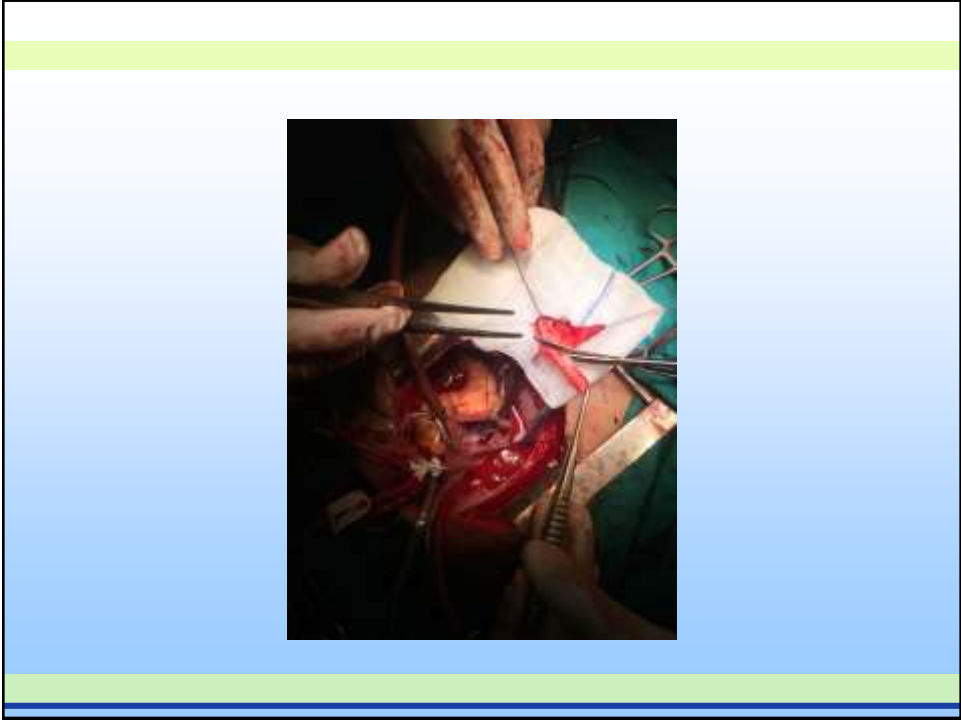
Snaring or surgery?

- cardiothoracic consultation was done for open heart and removal of device.
- the operation was carried out by median sternotomy after cardiopulmonary bypass.
- RVOT was opened, occlutech septal occluder was removed.
- ASD was closed by pericardial patch.
- Patient discharged on 7th day without complication.









- **Take home message**

- 1-strict selection criteria for ASD closure as regard its size ,adequate rims, to decrease incidence of complications.
- 2-Device embolization is the most common, serious, potential life threatening complication that require immediate removal via percutaneous or surgical intervention .

- 3-surgical back up must be ready and near Cath lab for help if indicated.
- 4-Team work action is very helpful in any emergency

- 5-some complicated cases of ASD are often difficult to reconstruct the spatial structure with use of 2D TEE or sizing balloon, 3D TEE is useful complementary of ASD option to 2D TEE for morphological evaluation.
- 6-comprehensive evaluation of ASD, careful monitoring for possible early and late embolization of device are mandatory in every case.

THANK YOU