

# ADDED VALUE OF THREE DIMENSIONAL ECHOCARDIOGRAPHY (RA GHOSTS)

**HODA SHEHATA ABDEL- KHALEK**  
ASSISTANT LECTURER  
CARDIOLOGY DEPARTMENT  
ALEXANDRIA UNIVERSITY ECHO LAB

## PERSONAL DATA

An 18 years old male

Complete heart block.

Dual chamber pacemaker implantation 4 years ago

IV drug abuser

## PRESENTATION

Persistent fever for 3 months.

On examination:

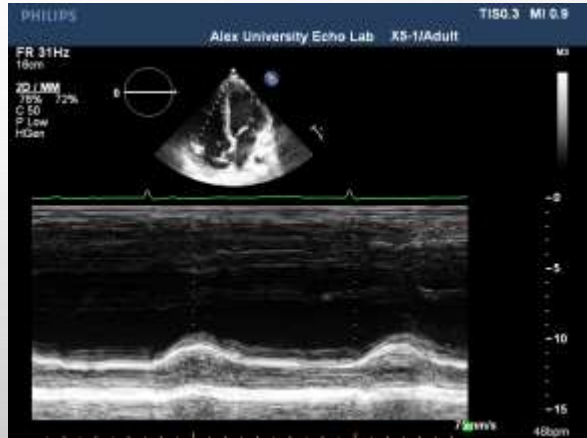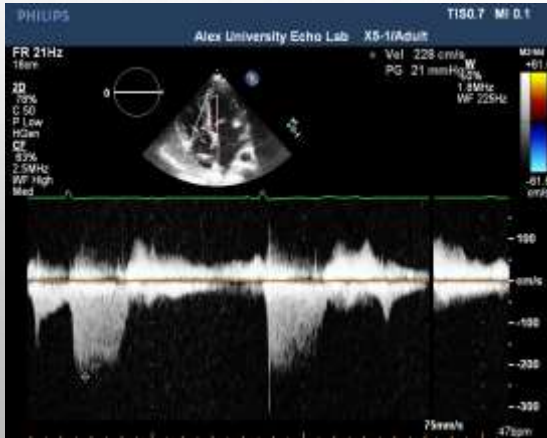-Temperature was 39°C

-No audible murmurs.

## 2D TTE

**TR: PSG 20 mmHg**

**TAPSE = 18mm.**



**2D TEE**

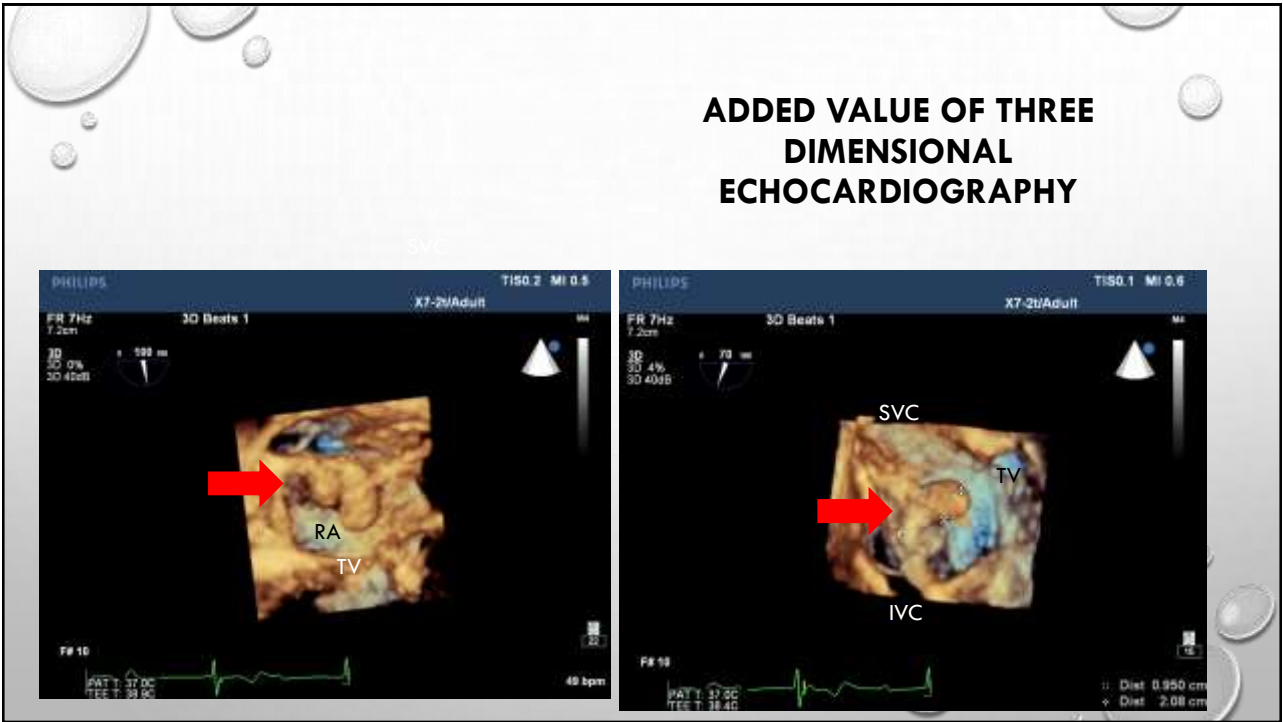


**3D ECHOCARDIOGRAPHY**



**3D TEE**

## ADDED VALUE OF THREE DIMENSIONAL ECHOCARDIOGRAPHY



B. Principles of treatment			
1. Prolonged (i.e. before and after extraction) antibiotic therapy and complete hardware (device and leads) removal are recommended in definite CDRIE, as well as in presumably isolated pocket infection	I	C	
2. Complete hardware removal should be considered on the basis of occult infection without another apparent source of infection	IIa	C	
3. In patients with NVE or PVE and an intracardiac device with no evidence of associated device infection, complete hardware extraction may be considered	IIb	C	

C. Mode of device removal			
1. Percutaneous extraction is recommended in most patients with CDRIE, even those with vegetations > 10 mm	I	B	382, 391, 405
2. Surgical extraction should be considered if percutaneous extraction is incomplete or impossible or when there is associated severe destructive tricuspid IE	IIa	C	
3. Surgical extraction may be considered in patients with large vegetations (>20 mm)	IIb	C	

**SO,**

**Parenteral antibiotics therapy.**

**Percutaneous lead extraction performed.**

**ONE WEEK AFTER LEADS  
EXTRACTION**

# EXPLANATION



**JACC: Cardiovascular Imaging**

Volume 3, Issue 7, July 2010  
DOI: 10.1016/j.jcmg.2009.12.016

**Diagnosis of Cardiac Device–Related Infective Endocarditis After Device Removal**

Yvan Le Dolley, Franck Thuny, Julien Mancini, Jean-Paul Casalta, Alberto Ribet, Frédérique Gounet, Emilie Bastard, Sebastien Ansaldo, Frederic Franceschi, Sebastien Renaud, Sebastien Prevot, Roch Giorgi, Laurence Tafanel, Jean-François Avierinos, Diöler Raoult, Jean-Claude Deharo and Gilbert Habib



[PDF Article](#)

---

**Abstract**

**Objectives** We sought to determine the incidence, diagnostic value, and outcome of intracardiac masses observed by echocardiography after device removal. We hypothesized that these “ghosts” of leads could be associated with the diagnosis of cardiac device–related infective endocarditis (CDRIE).

**Background** The echocardiographic appearance of residual floating masses in the right atrium after removal of permanent pacemakers and implantable cardioverter-defibrillators was recently described. However, the significance of these ghosts and their relationship with CDRIE are unknown.

**Methods** The pre-operative clinical, microbiological, and echocardiographic conditions, the indication, and the removal technique were analyzed in a retrospective cohort including all consecutive patients who underwent percutaneous lead removal. Three groups were formed according to the final diagnosis: CDRIE, local device infection, and noninfectious indications. The incidence of ghosts was compared among the 3 groups. All clinical, infectious, and extraction-related factors were studied for their association with ghosts. All patients with ghosts were followed after hospitalization.

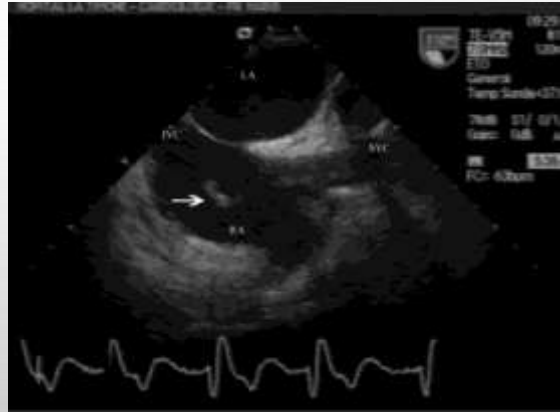**Results** Two hundred twelve patients underwent lead removal. Ghosts were observed in 17 patients (8% incidence), including 14 (16% of 60 patients with CDRIE) and 3 (5% of 59 patients with local device infection. Ghosts were never observed among the remaining 65 noninfected patients. A significant association was found between CDRIE and the presence of a ghost (odds ratio: 7.63, 95% confidence interval: 2.12 to 27.45,  $p = 0.001$ ). At 3 months, 2 patients with ghosts died suddenly, 2 underwent surgery, and 1 had a pulmonary embolism.

**Conclusions** Ghosts are observed in 8% of patients after percutaneous device extraction. Their presence is suggestive of device infection and seems to be associated with the diagnosis of CDRIE. The prognostic significance of such findings needs further investigation.

## WHAT IS A GHOST?

A ghost was defined as a post-removal, new, tubular, mobile mass detected by echocardiography following the lead's intracardiac route in the right cavities

Ghosts were observed in 17 patients (8% incidence), including 14 (16%) of 88 patients with CDRIE and 3 (5%) of 59 patients with local device infection. Ghosts were never observed among the remaining 65 noninfected patients

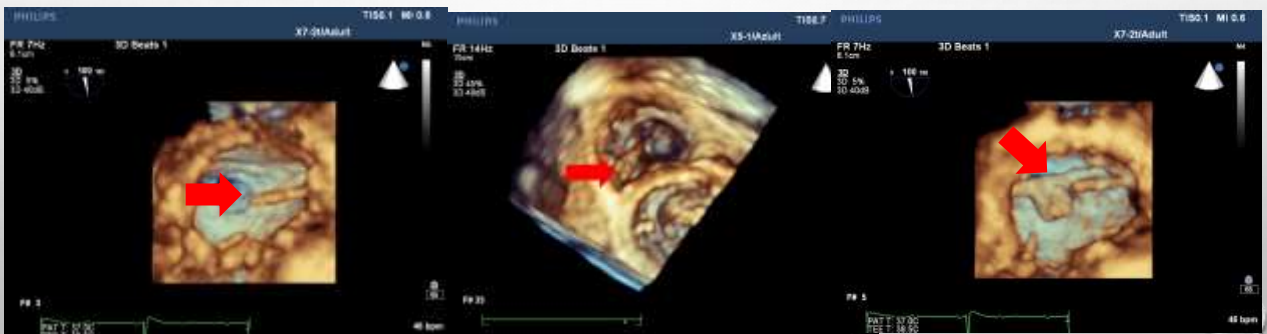

## GHOSTS: FOUND LOCATIONS

Superior vena cava

Tricuspid valve

Right atrium





## PATHOPHYSIOLOGY

CDRIE was the main factor associated with the appearance of ghosts.

Incomplete removal of the coating sheath surrounding the leads

Infected leads are more easily extracted than noninfected leads

Pathological findings were in agreement with the fact that **ghosts are not only fibrous sheaths but possible vegetations**

Ghosts might be **infected fibrous sheaths mixed with vegetations that come off cardiac device leads because of an infectious process.**

## CONCLUSIONS

A ghost is a floating mass in the right cardiac cavities observed in 8% of cases after percutaneous lead removal.

**The presence of a ghost seems to be associated with the diagnosis of CDRIE and might explain sudden death in some patients after lead extraction**

**The prognostic significance of these findings need further investigations.**

