

بِسْمِ اللَّهِ الرَّحْمَنِ الرَّحِيمِ

Exercise related syncope in young athlete (reassurance , restriction or referral)

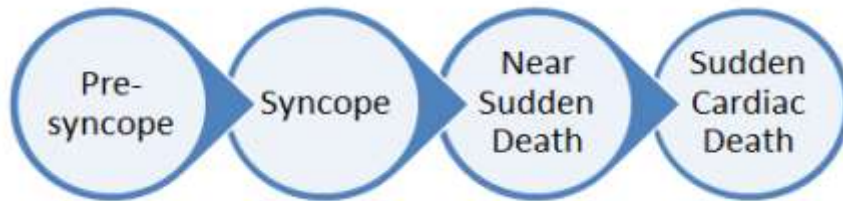
By

Hala Gouda Abomandour

Lecture of cardiology

E.P. unit , cardiology department

Egypt



Syncope

- A common event in young adults, syncope is usually benign and only rarely requires more than simple reassurance. However, exercise-related syncope always requires investigation because it may be the only symptom that precedes a sudden cardiac death.
- Syncope that occurs during exercise tends to be more ominous than that occurring in the postexertional state.

- 40% of the adult population has experienced a syncopal episode¹
- 1% of ER visits²
 - Up to 5% of admissions
- Cost per inpatient work up \$5,400²



- The family physician is often the first clinician to evaluate and manage patients with syncope and must quickly assess the risk and expedite an appropriate work-up.
- Several questions must be addressed immediately:
 1. should the athlete be allowed to exercise while the evaluation is under way?
 2. What tests should be scheduled and in what order?
 3. When is referral warranted and to whom?

What is syncope ?

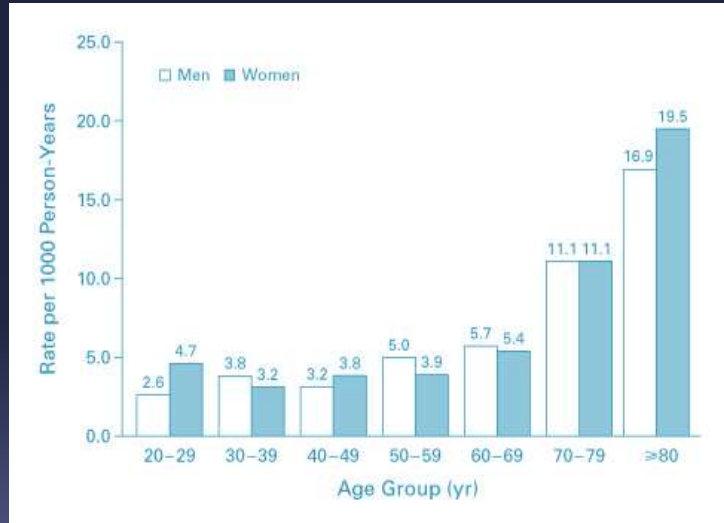
Syncope is :

- Transient loss of consciousness due to transient global cerebral hypoperfusion characterized by rapid onset, short duration, and spontaneous complete recovery.
- Consciousness is dependent on proper functioning of the **reticular activating system** and **both cerebral hemispheres**. Dysfunction leading to syncope, while multi-factorial and complex, is most commonly thought to be **metabolic in nature or secondary to insufficient cerebral cellular perfusion, or both**.

Moya A, Eur Heart J

- Exercise-related syncope occurs either during or immediately after a period of exercise.
- The sports medicine literature also recognizes the term **exercise-associated collapse** (EAC) to describe athletes who are unable to stand or walk unaided as a result of light-headedness, faintness, dizziness or syncope.^{4,5}
- EAC specifically excludes orthopedic injuries (e.g., sprained ankle, leg cramps) that would preclude completing a sports event.

Incidence and rate of hospitalization increases with age



¹ Soteriades ES, N Engl J Med

Mechanism

Types of Syncope

- Vascular syncope
 - Venous pooling in legs leads to decrease in ventricular preload
- Neurally mediated syncope
 - Receptors in atria, ventricles, and pulmonary arteries sense decreased venous return triggering vagal response
- Cardiac syncope
 - Interruption of cardiac output due to intrinsic cardiac abnormality

Types

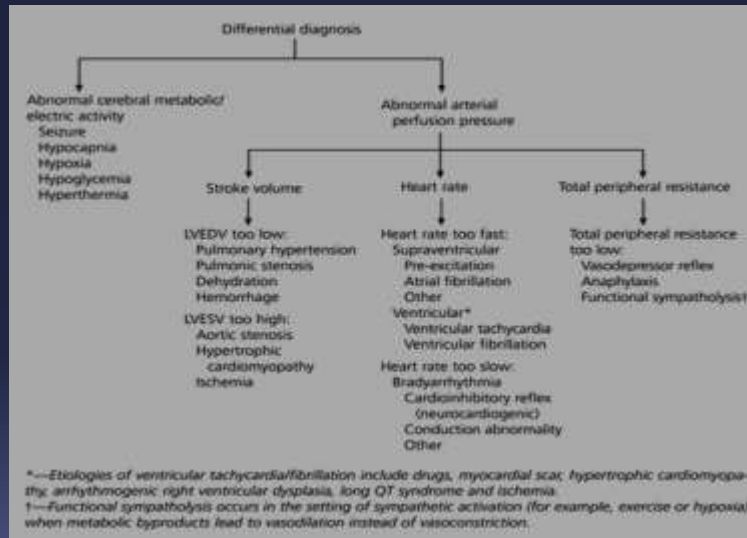
According to the cause :

- **Cardiac syncope**
 - Arrhythmia
 - Structural heart disease
- **Non-cardiac syncope**
 - Neurally-mediated syncope
 - Orthostatic hypotension
- **Non-syncope**
 - Epilepsy, concussion, psychogenic pseudosyncope

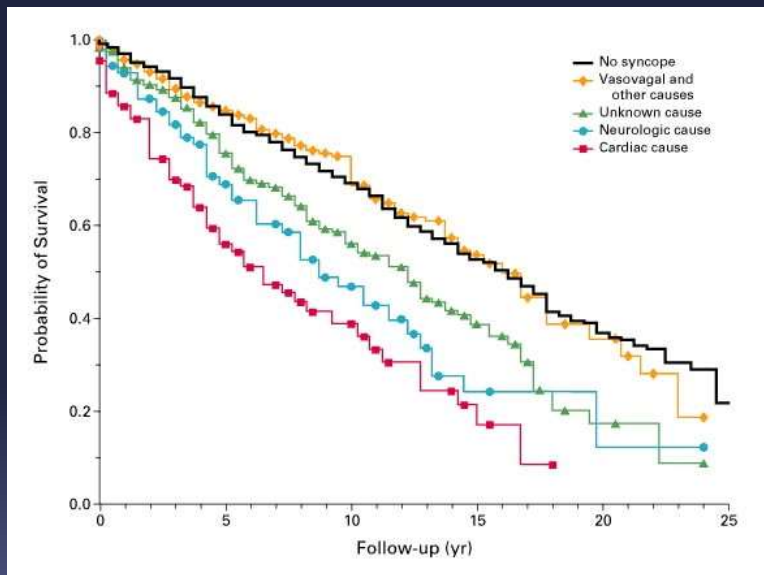
Cardiac Syncope

- **Arrhythmia**
 - Bradycardia
 - Sick sinus, atrioventricular block
 - Tachycardia
 - Ventricular tachycardia, supraventricular tachycardia, Wolff-Parkinson-White
 - Long QT syndrome, Brugada syndrome
- **Structural**
 - Aortic stenosis, mitral stenosis
 - Hypertrophic obstructive cardiomyopathy
 - Ischemia

Exercise-Related Syncope in Young Athletes



Overall Survival with Syncope

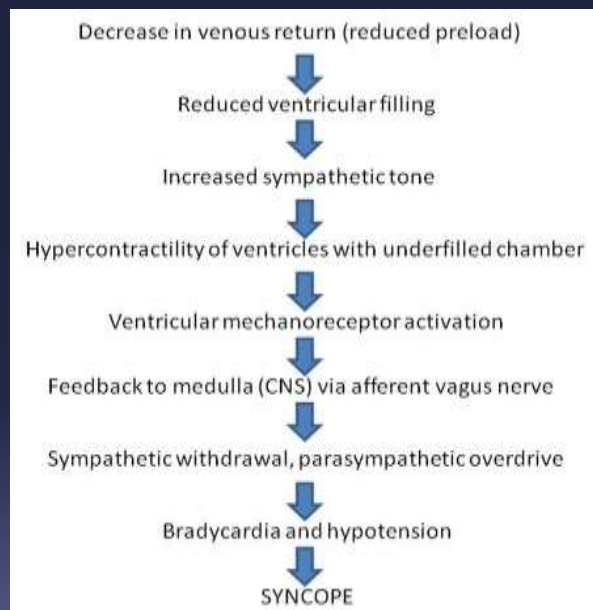


Soteriades ES, N Engl J Med

NEUROCARDIOGENIC SYNCOPE

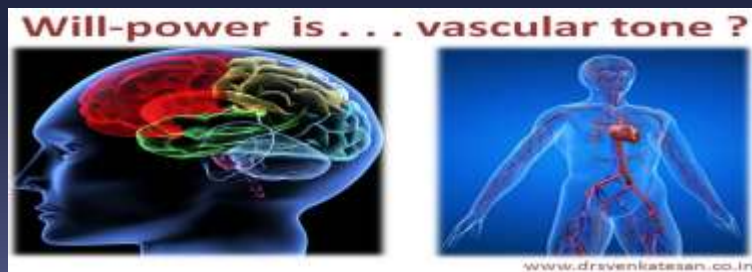
- Is generally regarded as **the most common cause of syncope in young adults**.
- It occurs when there is a loss of consciousness secondary to a **sudden reflex vasodilation or bradycardia, or both**.
- While most causes of neurally mediated syncope in young adults are triggered by situational stressors, neurocardiogenic mechanisms are also implicated in the majority of exercise-related syncopal events, particularly those that occur after exercise.
- Athletes are believed to be particularly predisposed to neurocardiogenic syncope.
- **High levels of resting vagal tone found in well-trained athletes may sensitize the efferent limb of the neurocardiogenic reflex**. In addition, **hemodynamic changes** that are beneficial during training may put athletes at greater risk for orthostatic intolerance.¹¹
- Neurocardiogenic syncope in athletes is generally **benign and has a favorable long-term prognosis**.¹²

Mechanism



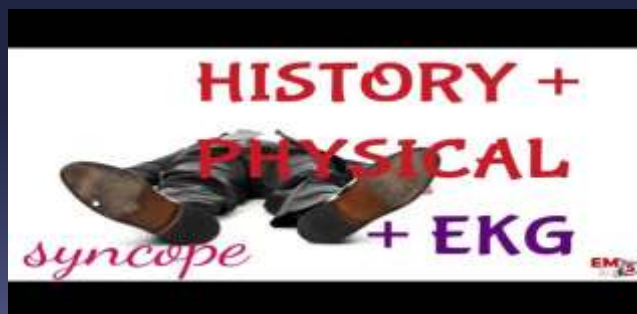Management

- Management of neurocardiogenic syncope in competitive athletes is controversial.
- The condition is optimally managed by a consultant who is familiar with this population. While pharmacologic therapy may be warranted in carefully selected cases,¹⁵
- nonpharmacologic therapy that is focused on training techniques and behavior modification should be attempted first.



Evaluation of exercise related syncope

- Exercise-related syncope, while generally a benign event, may sometimes be a precursor to sudden death and thus requires a thorough investigation. No definitive diagnostic test has been clearly identified.¹⁶



HISTORY

- Patients who present with a history of “passing out with exercise” require a careful medical history to **differentiate pathologic from benign etiologies**. The evaluating physician must first **distinguish between true syncope involving a loss of consciousness and collapse associated with exhaustive effort**.
- In cases of true syncope associated with hemodynamic causes, athletes typically recover quickly with restoration of arterial pressure unless resuscitation is required.
- **After collapse associated with an exhaustive effort, athletes usually will have prolonged periods of semi-consciousness, even while in the supine position with normal heart rate and blood pressure.**
- This is in contrast to patients with syncope associated with **heat stress**, who are universally **hypotensive and tachycardic**.
- Athletes who describe being “unconscious” but are able to assist in their own evacuation are unlikely to be in immediate danger of a life-threatening arrhythmia, although metabolic abnormalities may be present (e.g., hyponatremia).

- The second critical distinction is whether the syncopal event occurred **during or immediately after exercise**.
- Orthostatic hypotension that occurs after exercise, usually in association with sudden cessation of activity, is much less ominous than the sudden loss of consciousness that **occurs during exercise (which suggests an arrhythmic or cardiac etiology)**.
- **Prodromal symptoms** occurring during exercise, including palpitations (suggesting arrhythmia), chest pain (ischemia, aortic dissection), nausea (ischemia or high levels of vagal activity), wheezing and pruritis (anaphylaxis), are also significant. As in the evaluation of syncope in nonathletes.
- It is also important to identify whether syncope or dizziness occurs only in the **upright position (orthostatic hypotension)** or also **during sitting or supine positions (arrhythmia or nonhemodynamic cause)**.

- **Finally, a family history of sudden death is critical** and, if present, may identify very-high-risk subgroups with hypertrophic cardiomyopathy, long QT syndrome or arrhythmogenic right ventricular dysplasia.

Examination

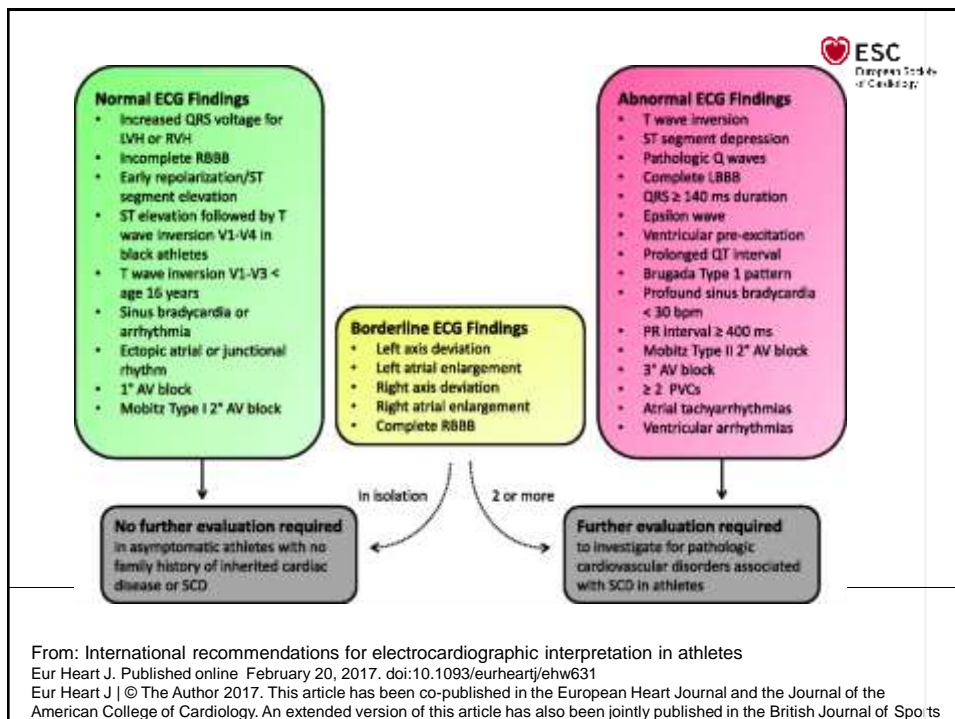


- **Vital signs**, including orthostatic blood pressure, should be obtained initially. Blood pressure should be measured in the arms and legs as well as after at least five minutes of standing to check for orthostatic hypotension.
- The general body habitus should be assessed for **Marfan's features**, including pectus deformity, high-arched palate, arm span greater than height and kyphoscoliosis (**Marfan's syndrome is a common cause of exercise-related sudden death, but it rarely presents with exercise-related syncope**).
- Careful evaluation of the carotid or radial pulse may demonstrate the bifid pulse (two systolic peaks) of hypertrophic cardiomyopathy or the slow rising pulse (pulsus parvus et tardus) of aortic stenosis.

- The cardiac examination begins with **chest palpation** in an attempt to identify the point of maximal impulse, as well as any thrills or heaves that may identify pathologic conditions.
- **Auscultation** should be performed with the patient in the **supine, seated** and **standing** positions. Murmurs, gallops and pathologic splitting should all be noted.
- **Echocardiography** should be performed for the evaluation of murmurs that are diastolic, continuous, holosystolic or of intensity grade 3 or greater.
- **Listening to the patient during squatting, while standing and during a Valsalva maneuver helps to rule out dynamic outflow obstruction.**
- A systolic murmur that gets louder with standing or during a Valsalva maneuver suggests the obstruction of hypertrophic cardiomyopathy.

ELECTROCARDIOGRAM

- The electrocardiogram (ECG) should be carefully evaluated for **rate, rhythm and repolarization abnormalities**, specifically looking for the **long QT syndrome, pre-excitation** (e.g., Wolff-Parkinson-White syndrome), left or right ventricular hypertrophy, and the complications of **ischemic heart disease**.
- Although not uncommon in athletes, electrocardiographic evidence of left ventricular hypertrophy or ventricular extrasystoles may represent subtle clues to hypertrophic cardiomyopathy or arrhythmogenic right ventricular dysplasia, respectively.
- Conversely, a completely normal ECG is rare in patients with hypertrophic cardiomyopathy.



SPECIAL TESTS AND REFERRAL

- Numerous special tests may be warranted in the evaluation of young athletes with exercise-induced syncope.
- The two most fundamental tests, however, are the **echocardiogram** and the **exercise stress test**.
- Echocardiography, which should precede exercise stress testing, allows the clinician to assess ventricular size and function, estimate pulmonary pressures and rule out valvular dysfunction.
- In young athletes, echocardiography can specifically assist in making the diagnosis of hypertrophic cardiomyopathy, aortic stenosis and pulmonary hypertension.
- The echocardiogram should be specifically examined for the presence of the left coronary ostium, which should arise from the left sinus of Valsalva. If present, it excludes an important congenital coronary anomaly often reported to cause sudden cardiac death. If the left coronary ostium is not clearly identified, further testing may be required.

Exercise stress test

- The exercise stress test should be performed after the echocardiogram.
- **Rather than using a standard Bruce protocol, a test should be designed to reproduce the conditions that provoked the specific syncopal event and challenge the individual athlete. For example, a stuttering start-stop test for a basketball or soccer player or a prolonged high-intensity test for a runner might be performed.**
- The exercise electrocardiogram should also be examined for appropriate shortening of the QT interval.
- Numerous mechanisms are available to detect pathologic arrhythmias, including **Holter monitors, looping event recorders and implantable recorders, as well as electrophysiologic studies.**
- Images of the coronary arteries may require cardiac catheterization or, if available, noninvasive magnetic resonance imaging.

- However, tilt-table testing should not be used to evaluate athletes with recurrent syncope.^{9,12} The exact sequencing of these studies, as well as the decision about whether an athlete can return to full activity while the evaluation is under way, requires individualization and consideration of referral to a consultant.
- The clinician is also reminded that not all syncope is cardiogenic.
- Athletes whose history suggests seizure activity may require an electroencephalogram and imaging of the brain to exclude a structural lesion.
- Hematologic and metabolic abnormalities require testing as indicated. Diabetic patients taking insulin, athletes with eating disorders and patients taking beta-blockers should be assessed for hypoglycemia.
- Black athletes with a history of collapse associated with high altitude training, dehydration or hyperthermia should be screened for sickle cell trait.

Clinical Clues to Common Etiologies Presenting with Exercise-Related Syncope

SUSPECTED DIAGNOSIS	CLINICAL CLUES	ELECTROCARDIOGRAM	SUGGESTED DIAGNOSTIC TESTING
Neurocardiogenic syncope	Noxious stimulus, prolonged upright position	Normal	Exercise testing
Supraventricular tachyarrhythmias	Palpitations, response to carotid sinus pressure	Pre-excitation	Electrophysiologic study and definitive therapy
Hypertrophic cardiomyopathy	Grade III/VI systolic murmur (louder on Valsalva maneuver), family history of sudden death	Normal, pseudoinfarction pattern, left ventricular hypertrophy with strain	ECG with Doppler Echocardiography

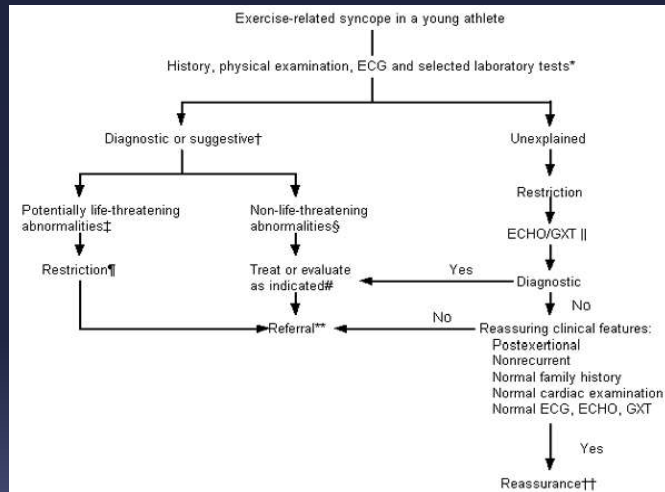
SUSPECTED DIAGNOSIS	CLINICAL CLUES	ELECTROCARDIOGRAM	SUGGESTED DIAGNOSTIC TESTING
Myocarditis, pericarditis	Previous upper respiratory tract infection, pneumonia; shortness of breath; recreational drug use	Simulation of a myocardial infarction with ectopy	Viral studies, echocardiography, drug screening
Aortic stenosis	Exertional syncope, grade III/VI harsh systolic crescendo-decrescendo murmur	Left ventricular hypertrophy	ECG with Doppler ultrasonography
Mitral valve prolapse	"Thumping heart," midsystolic click with or without a murmur	QT interval may be prolonged	Echocardiography with Doppler ultrasonography
Prolonged QT syndrome	Recurrent syncope with family history of sudden death	Prolonged corrected QT interval (> 0.44)	Family history, exercise stress test with ECG after exercise

SUSPECTED DIAGNOSIS	CLINICAL CLUES	ELECTROCARDIOGRAM	SUGGESTED DIAGNOSTIC TESTING
Coronary anomalies	Usually asymptomatic, near sudden death event, family history of sudden death	Normal resting ECG	Coronary angiography; cardiac MRI
Acquired coronary artery diseases	Chest pain syndrome; family history of sudden death	Ischemia, may be normal	Exercise testing with or without perfusion or contractile imaging, lipid studies
Right ventricular dysplasia	Asymptomatic until syncope, tachyarrhythmias, family history of sudden death	T wave inversion V ₁ -V ₃ PVCs with LBBB configuration	Echocardiography/Doppler study, electrocardiography

<i>SUSPECTED DIAGNOSIS</i>	<i>CLINICAL CLUES</i>	<i>ELECTROCARDIOGRAM</i>	<i>SUGGESTED DIAGNOSTIC TESTING</i>
Exertional hyponatremia	Prolonged endurance event, altered consciousness with normal temperature	Nonspecific changes, may be normal	Serum electrolytes, urine and serum osmolality
Hyperthermia, heat stroke	Prolonged endurance event, altered consciousness with elevated temperature	Nonspecific changes, may be normal	Rectal temperature, electrolyte levels, CK, LFTs, CBC count, urine myoglobin, sickle cell screen
Seizure	Incontinence, prolonged postictal state	Nonspecific changes, may be normal	Electroencephalogram, cranial MRI or CT

Final Comment

Final Comment : Evaluation of exertional syncope



- Algorithm for the primary care evaluation of exertional syncope in athletes under 35 years of age. (ECG = electrocardiogram; ECHO = echocardiogram; GXT = graded exercise stress test)

- In cases where the physician clearly suspects that a post-race, exercise-associated collapse occurred secondary to an exhaustive effort, a diagnosis of a non-life-threatening neurocardiogenic syncopal event may be concluded, with management as appropriate.
- The clinician is reminded that this diagnosis is the result of a carefully conducted history and physical examination, along with electrocardiographic analysis. The history of the event is critical to establishing the diagnosis, as previously discussed. Mandatory diagnostic features for post-race exercise collapse include: postexertional occurrence, nonrecurrent collapse, unremarkable family history, normal cardiac examination and normal electrocardiogram. Any doubt in the clinician's assessment would identify the athlete's syncopal event as unexplained and warranting further diagnostic evaluation.

- Unexplained exercise-related syncope warrants restriction and an evaluation beginning with echocardiography preceding exercise stress testing. A diagnosis made with the preceding tests should be managed as appropriate, while negative testing may warrant either careful observation or referral to a cardiologist for consideration of more advanced testing.
- In patients with an unremarkable echocardiogram and exercise stress test, a presumptive diagnosis of neurocardiogenic syncope may be the conclusion. If the event was clearly postexertional by history, nonrecurrent and associated with a normal physical examination (and a family history unremarkable for early sudden death or recurrent syncope) and a normal ECG, patients may safely return to vigorous activity with careful observation. Athletes whose clinical pictures do not meet these criteria, on the other hand, warrant further evaluation by a cardiologist.

2017 ACC/AHA/HRS Guideline for the Evaluation and Management of Patients With Syncope

Developed in Collaboration with the American College of Emergency Physicians and Society for Academic Emergency Medicine

Endorsed by the Pediatric and Congenital Electrophysiology Society

© American College of Cardiology Foundation, American Heart Association, and the Heart Rhythm Society

Athletes

COR	LOE	Recommendations
I	C-EO	Cardiovascular assessment by a care provider experienced in treating athletes with syncope is recommended prior to resuming competitive sports.
Ia	C-LD	Assessment by a specialist with disease-specific expertise is reasonable for athletes with syncope and high-risk markers.
Ia	C-LD	Extended monitoring can be beneficial for athletes with unexplained exertional syncope after an initial cardiovascular evaluation.
III: Harm	B-NR	Participation in competitive sports is not recommended for athletes with syncope and phenotype-positive HCM, CPVT, LQTS1, or ARVC before evaluation by a specialist.

References

- Moya A, Sutton R, Ammirati F, Blanc JJ, Brignole M, Dahm JB, et al. Guidelines for the diagnosis and management of syncope (version 2009): the task force for the diagnosis and management of syncope of the European Society of Cardiology (ESC). *Eur Heart J* 2009;30:2631-71.
- Soteriades ES, Evans JC, Larson MG, Chen MH, Chen L, Benjamin EJ, et al. Incidence and prognosis of syncope. *N Eng J Med* 2002;347:878-85.
- Sun BC, Emond JA, Camargo CA Jr. Direct medical costs of syncope-related hospitalizations in the United States. *Am J Cardiol* 2005;95:668-71.
- Linzer M, Poninen M, Gold DT, Divine GW, Felder A, Brooks WB. Impairment of physical and psychosocial function in recurrent syncope. *J Clin Epidemiol* 1991;44:1037-43.
- Rosanio S, Schwarz ER, Ware DL, Vitarelli A. Syncope in adults: systematic review and proposal of a diagnostic and therapeutic algorithm. *Int J Cardiol* 2013;162(3):149-57.
- Parry SW, Tan MP. An approach to the evaluation and management of syncope in adults. *BMJ* 2010;340:c880.
- <https://www.healthcarebluebook.com/>
- Radack KL. Syncope. Cost-effective patient workup. *Postgrad Med* 1986;80(8):169-76.
- Simpson CS, Krahn AD, Klein GJ, Yee R, Skanes AC, Manda V, Norris C. A cost effective approach to the investigation of syncope: relative merit of different diagnostic strategies. *Can J Cardiol* 1999;15(5):579-84.
- Strickberger, SA, Benson DW, Biaggioni I, Callans DJ, Cohen MI, Ellenbogen KA, et al. AHA/ACC scientific statement on the evaluation of syncope: from the American Heart Association Councils on Clinical Cardiology, Cardiovascular Nursing, Cardiovascular Disease in the Young, and Stroke, and the Quality of Care and Outcomes Research Interdisciplinary Working Group; and the American College of Cardiology Foundation: in collaboration with the Heart Rhythm Society; endorsed by the American Autonomic Society. *Circulation* 2006;113(2):316-27.
- Brignole M, Hamdan MH. New concepts in the assessment of syncope. *J Am Coll Cardiol* 2012;59(18):1583-91.
- Sheldon R, Rose S, Connolly S, Ritchie D, Koshman ML, Frenneaux M. Diagnostic criteria for vasovagal syncope based on a quantitative history. *Eur Heart J* 2006;27(3):344-50.
- Quinn JV, Sittell IG, McDermott DA, Sellers KL, Kohn MA, Wells GA. Derivation of the San Francisco Syncope Rule to predict patients with short-term serious outcomes. *Ann Emerg Med* 2004;43(2):224-32.
- Colivicchi F, Ammirati F, Melina D, Guido V, Imperoli G, Santini M, et al. Development and prospective validation of a risk stratification system for patients with syncope in the emergency department: the QESIL risk score. *Eur Heart J* 2003;24:811-9.
- Mendu ML, McAvay G, Lampert R, Stoehr J, Tinetti ME. Yield of diagnostic tests in evaluating syncopal episodes in older patients. *Arch Intern Med* 2009; 164(14):1299-1305.
- Nguyen-Michel VH, Adam C, Dinkelacker V, Pichit P, Boudali Y, Baulac M, et al. Characterization of seizure-induced syncopes: EEG, ECG, and clinical features. *Epilepsia* 2014;55(1):146-55.
- Grossman SA, Fischer C, Bar JL, Lipsitz LA, Mottley L, Sands K, et al. The yield of head CT in syncope: a pilot study. *Intern Emerg Med* 2007;2(1):46-9.
- Lagi A, Cuomo A, Veneziani F, Cencetti S. Copeptin: a blood test marker of syncope. *Int J Clin Pract* 2013;67(6):512-5.
- Langer-Gould AM, Anderson WE, Armstrong MJ, Cohen AB, Eccher MA, et al. The American Academy of Neurology's top five choosing wisely recommendations. *Neurology* 2013;81(11):1004-11.
- Marine JE. ECG features that suggest a potentially life-threatening arrhythmia as the cause for syncope. *J Electrocardiol* 2013;46(6):561-8.

